

Otorhinolaryngologica Italica

Volume 35

3

June 2015

*Official Journal of the Italian Society of Otorhinology
Head and Neck Surgery*

Organo Ufficiale della Società Italiana di Otorinolaringologia
e Chirurgia Cervico-Facciale

Review

Nimodipine in otolaryngology: from past evidence to clinical perspectives

Head and neck

Supratracheal laryngectomy: current indications and contraindications

A novel approach emphasising intra-operative superficial margin enhancement of head-neck tumours with narrow-band imaging in transoral robotic surgery

Salvage surgery in post-chemoradiation laryngeal and hypopharyngeal carcinoma: outcome and review

Rhinology

Transorbital transnasal endoscopic combined approach to the anterior and middle skull base: a laboratory investigation

Vestibology

Vertigo in childhood: proposal for a diagnostic algorithm based upon clinical experience

Otology

Osseointegrated implants in patients with auricular defects: a case series study

Clinical techniques and technology

Auricular reconstruction of congenital microtia: personal experience in 225 cases

Mandibular reconstruction using fibula free flap harvested using a customised cutting guide: how we do it

Case series and reports

Physiology and prospects of bimanual tracheoesophageal brass instrument play

Temporo-mandibular joint chondrosarcoma: case report and review of the literature

Audiological findings in a case of cerebellar angioreticuloma

PACINI
EDITORE
MEDICINA

www.actaitalica.it



ACTA

ACTA

Otorhinolaryngologica Italica

Official Journal of the Italian Society of Otorhinolaryngology - Head and Neck Surgery
Organo Ufficiale della Società Italiana di Otorinolaringologia e Chirurgia Cervico-Facciale

Former Editors-in-Chief: C. Calearo†, E. de Campora, A. Staffieri, M. Piemonte, F. Chiesa

Editorial Board

Editor-in-Chief:

G. Paludetti

President of S.I.O.:

G. Spriano

*Former Presidents of S.I.O.
and Editors-in-Chief:*

I. De Vincentiis, D. Felisati, L. Coppo,

G. Zaoli, P. Miani, G. Motta,

L. Marcucci, A. Ottaviani,

P. Puxeddu, M. Maurizi, G. Sperati,

D. Passali, E. de Campora, A. Sartoris,

P. Laudadio, M. De Benedetto,

S. Conticello, D. Casolino,

A. Rinaldi Ceroni, M. Piemonte,

A. Staffieri, F. Chiesa, R. Fiorella,

A. Camaioni, A. Serra

Editorial Staff

Editor-in-Chief:

G. Paludetti

Deputy Editor:

J. Galli

Associate Editors:

G. Almadori, F. Ottaviani

Editorial Coordinator:

E. De Corso

Editorial Assistant:

P. Moore

Treasurer:

L. de Campora

Italian Scientific Board

L. Bellussi, G. Danesi, C. Grandi,

A. Martini, L. Pignataro, F. Raso,

R. Speciale, I. Tasca

International Scientific Board

J. Betka, P. Clement, M. Halmagyi,

L.P. Kowalski, M. Pais Clemente,

J. Shah, H. Stammberger, R. Laszig,

G. O'Donoghue, R.J. Salvi, R. Leemans,

M. Remacle, F. Marchal, H.P. Zenner,

B. Scola Yurrita, R.W. Gilbert

Editorial Office

Editor-in-Chief:

G. Paludetti

Department of Head and Neck Surgery -

Otorhinolaryngology

Catholic University of the Sacred Heart

"A. Gemelli" Hospital

L.go F. Vito, 1 - 00168 Rome, Italy

Tel. +39 06 30154439

Fax + 39 06 3051194

actaitalicaorl@rm.unicatt.it

Editorial Coordinator:

E. De Corso

eugenio.decorso@rm.unicatt.it

Editorial Secretary:

R. Gallus

gallusroberto@gmail.com

Argomenti di Acta

Otorhinolaryngologica Italica

Editor-in-Chief: G. Paludetti

Editorial Coordinator: M.R. Marchese

raffaellamarchese@gmail.com

© Copyright 2015 by

Società Italiana di Otorinolaringologia

e Chirurgia Cervico-Facciale

Via Luigi Pigorini, 6/3

00162 Rome, Italy

Publisher

Pacini Editore SpA

Via Gherardesca, 1

56121 Pisa, Italy

Tel. +39 050 313011

Fax +39 050 3130300

info@pacinieditore.it

www.pacinimedicina.it

Acta Otorhinolaryngologica Italica is cited

in Index Medicus, MEDLINE, PubMed

Central, Science Citation Index Expanded,

Scopus, DOAJ, Open-J Gate, Free Medical

Journals, Index Copernicus, Socolar

Journal Citation Reports:

Impact Factor 1.439

Acta Otorhinolaryngologica Italica is

available on Google Scholar

PACINI
EDITORE
MEDICINA

www.actaitalica.it



Contents

Review

Nimodipine in otolaryngology: from past evidence to clinical perspectives

L'impiego della nimodipina in otorinolaringologia:

dalle esperienze del passato verso nuove prospettive farmaco-terapeutiche

D. Monzani, E. Genovese, L.A. Pini, F. Di Berardino, M. Alicandri Ciuffelli, G.M. Galeazzi, L. Presutti..... pag. 135

Head and neck

Supratracheal laryngectomy: current indications and contraindications

Laringectomia sopratracheale: indicazioni e controindicazioni

G. Succo, M. Bussi, L. Presutti, S. Cirillo, E. Crosetti, A. Bertolin, L. Giordano, G. Molteni, M. Petracchini,

A.E. Sprio, G.N. Berta, A. Fornari, G. Rizzotto » 146

A novel approach emphasising intra-operative superficial margin enhancement of head-neck tumours with narrow-band imaging in transoral robotic surgery

Un innovativo approccio intra-operatorio alla definizione dei margini superficiali nei tumori del testa-collo con l'uso della narrow-band imaging nella chirurgia robotica transorale

C. Vicini, F. Montevecchi, G. D'Agostino, A. De Vito, G. Meccariello..... » 157

Salvage surgery in post-chemoradiation laryngeal and hypopharyngeal carcinoma: outcome and review

Chirurgia di salvataggio nel carcinoma della laringe o dell'ipofaringe post-chemioradioterapia: risultati e revisione della letteratura

L. van der Putten, R. de Bree, P.A. Doornaert, J. Buter, S.E.J. Eerenstein, D.H.F. Rietveld, D.J. Kuik, C.R. Leemans » 162

Rhinology

Transorbital transnasal endoscopic combined approach to the anterior and middle skull base: a laboratory investigation

Approccio endoscopico combinato transnasale e transorbitario alla fossa cranica anteriore e media: studio su cadavere

A. AlQahtani, G. Padoan, G. Segnini, D. Lepera, S. Fortunato, I. Dallan, A. Pistochini, S. Abdulrahman, V. Abbate,

B. Hirt, P. Castelnuovo..... » 173

Vestibology

Vertigo in childhood: proposal for a diagnostic algorithm based upon clinical experience

La vertigine nell'infanzia: un algoritmo diagnostico alla luce dell'esperienza clinica

A.P. Casani, I. Dallan, E. Navari, S. Sellari Franceschini, N. Cerchiai » 180

Otology

Osseointegrated implants in patients with auricular defects: a case series study

Correzione di difetti del padiglione auricolare mediante epitesi fissate con impianti osteointegrati: casistica personale

E. Mevio, L. Facca, M. Mullace, M. Sbrocca, E. Gorini, L. Artesi, N. Mevio..... » 186

Clinical techniques and technology

Auricular reconstruction of congenital microtia: personal experience in 225 cases

Ricostruzione auricolare in microtia congenita: esperienza personale in 225 casi

M. Anghinoni, C. Bailleul, A.S. Magri » 191

Mandibular reconstruction using fibula free flap harvested using a customised cutting guide: how we do it

Ricostruzione mandibolare con lembo microvascolare di fibula, allestito mediante utilizzo di guida di taglio customizzata: ecco come lo realizziamo

A. Tarsitano, L. Ciocca, R. Cipriani, R. Scotti, C. Marchetti » 198

Case series and reports

Physiology and prospects of bimanual tracheoesophageal brass instrument play

Fisiologia e prospettive del suono bimanuale di un ottone in paziente portatore di valvola tracheoesofagea

F.J.M. Hilgers, R. Dirven, I. Jacobi, M.W.M. van den Brekel..... » 202

Temporo-mandibular joint chondrosarcoma: case report and review of the literature

Condrosarcoma dell'articolazione temporo-mandibolare: caso clinico e revisione della letteratura

C. Giorgione, F.M. Passali, T. Varakliotis, M. Sibilìa, F. Ottaviani » 208

Audiological findings in a case of cerebellar angiodysplasia

Risvolti audiologici nell'angiodysplasia cerebellare

A. Serra, P. Di Mauro, S. Cocuzza, I. Chiamonte, L. Maiolino..... » 212

Calendar of events - Italian and International Meetings and Courses » 215

REVIEW

Nimodipine in otolaryngology: from past evidence to clinical perspectives

L'impiego della nimodipina in otorinolaringologia: dalle esperienze del passato verso nuove prospettive farmaco-terapeutiche

D. MONZANI¹, E. GENOVESE¹, L.A. PINI², F. DI BERARDINO³, M. ALICANDRI CIUFELLI¹, G.M. GALEAZZI⁴, L. PRESUTTI¹

¹ Unità Operativa Complessa di Otorinolaringoiatria, Azienda Ospedaliero-Universitaria Policlinico di Modena, Italy;

² Cattedra di Farmacologia Clinica, Azienda Ospedaliero-Universitaria Policlinico di Modena, Italy; ³ Unità Operativa Complessa di Audiologia, Fondazione "IRCCS Ca' Granda", Ospedale Maggiore Policlinico di Milano, Italy;

⁴ Dipartimento di Medicina Diagnostica, Clinica e di Sanità Pubblica, Università degli Studi di Modena e Reggio Emilia

SUMMARY

As L-type voltage-gated calcium channels (VGCCs) control Ca²⁺ influx and depolarisation of cardiac and vascular smooth muscle, they represent a specific therapeutic target for calcium channel blockers (CCBs), which are approved and widely used to treat hypertension, myocardial ischaemia and arrhythmias. L-type currents also play a role in calcium entry in the sensory cells of the inner ear. In hair cells of both cochlea and labyrinth, calcium cytoplasmic influx is the first physiological process that activates complex intracellular enzymatic reactions resulting in neurotransmitter release. Excessive calcium ion entry into sensory cells, as a consequence of L-VGCCs malfunction is responsible for over-activation of phospholipase A2 and C, protein kinase II and C, nitric oxide synthase and both endonucleases and depolymerases, which can cause membrane damage and cellular death if the cytoplasmic buffering capacity is overcome. Nimodipine, a highly lipophilic 1-4 dihydropyridine that easily crosses the brain-blood barrier, is generally used to reduce the severity of neurological deficits resulting from vasospasm in patients with subarachnoid haemorrhage. Moreover, due to its selective blocking activity on L-channel calcium currents, nimodipine is also suggested to be an effective countermeasure for cochlear and vestibular dysfunctions known as channelopathies. Indeed, experimental data in amphibians and mammals indicate that nimodipine has a stronger efficacy than other CCBs (aminopyridine, nifedipine) on voltage-dependent whole-cell currents within hair cells at rest and it is the only agent that is also effective during their mechanically induced depolarisation. In humans, the efficacy of nimodipine is documented in the medical management of peripheral vestibular vertigo, sensorineural hearing loss and tinnitus, even in a pathology as complex as Ménière's disease. Nimodipine is also considered useful in the prophylaxis of damage to the facial and cochlear nerves caused by ablative surgery of cerebellopontine tumours; it has been recently hypothesised to accelerate functional recovery of recurrent nerve lesions during thyroid cancer surgery. Further trials with adequate study design are needed to test the efficacy of nimodipine in the treatment of vertigo due to cerebrovascular disease and vestibular migraine.

KEY WORDS: Vertigo • Tinnitus • Hearing loss • Vestibular migraine • Nimodipine

RIASSUNTO

I canali del calcio di tipo L sono indispensabili alla normale contrattilità del miocardio e della muscolatura liscia del sistema vascolare. In quanto tali, essi rappresentano uno specifico bersaglio terapeutico di una vasta famiglia di farmaci ad attività calcio-antagonista, che sono ampiamente usati per trattare l'ipertensione, l'ischemia miocardica e le aritmie. Tuttavia, i canali del calcio di tipo L svolgono un ruolo determinante anche nel normale funzionamento delle cellule sensoriali nell'orecchio interno. Nelle cellule cigliate, infatti, sia della coclea che del labirinto, l'ingresso del calcio all'interno del citoplasma è il primo processo fisiologico che attiva un complesso di meccanismi intracellulari, ovvero una sequenza di attivazioni enzimatiche, il cui risultato finale è il rilascio dei neurotrasmettitori a livello delle sinapsi. Al contrario, una concentrazione eccessiva di ioni calcio nelle stesse cellule sensoriali, ad esempio come conseguenza di un malfunzionamento dei canali del calcio di tipo L, è responsabile dell'attivazione delle fosfolipasi di tipo A2 e C, delle protein-chinasi II e C, dell'ossido nitrico sintetasi che possono causare un danno alla membrana plasmatica e la stessa morte cellulare qualora i limiti funzionali dei sistemi tampone del citoplasma vengano superati. La nimodipina, un agente altamente lipofilo, appartenente alla famiglia delle 1-4 diidropiridinine, che attraversa facilmente la barriera emato-encefalica, è generalmente utilizzata per ridurre la gravità dei deficit neurologici derivanti da vasospasmo nei pazienti con emorragia subaracnoidea. Inoltre, a causa della sua azione calcio-antagonista che si esplica selettivamente nei confronti dei canali del calcio di tipo L, viene suggerita come trattamento farmacologico efficace principalmente per quelle disfunzioni cocleari e vestibolari che vengono considerate delle "canalopatie". In effetti, i dati sperimentali ottenuti negli anfibi e in alcune specie di mammiferi indicano che nimodipina ha maggiore efficacia di altri calcioantagonisti (aminopiridina e nifedipina) nel bloccare le correnti di ioni calcio in ingresso nelle cellule cigliate e che è l'unico calcio-antagonista a mantenere tale efficacia anche durante la loro depolarizzazione indotta da stimolo meccanico. Negli esseri umani l'efficacia terapeutica della nimodipina è stata documentata nel trattamento della vertigine labirintica, dell'ipoacusia neurosensoriale e dell'acufene anche se riferibili ad una patologia complessa e non ancora del tutto chiarita come la malattia di Ménière. La nimodipina è inoltre considerata un valido approccio farmacologico nella profilassi dei danni neurali ai nervi facciali e cocleari causati dalla chirurgia ablattiva dei tumori dell'angolo ponto-cerebellare ed è stata recentemente indicata per accelerare il recupero funzionale delle lesioni del nervo ricorrente conseguenti alla chirurgia del cancro alla tiroide. Per verificare, infine, l'efficacia della nimodipina nel trattamento delle vertigini di origine centrale, perlopiù associate ai disordini cerebrovascolari, e nel trattamento della vertigine emicranica, sono necessari ulteriori studi che confermino con maggiore rigore scientifico tali prospettive, peraltro già ampiamente riportate nella letteratura scientifica.

PAROLE CHIAVE: Vertigine • Acufene • Ipoacusia • Vertigine emicranica • Nimodipina

Introduction

Recent advances in the management of vertigo and tinnitus focus on device-related modalities that provide some patients with aural symptoms with acceptable results¹, but others with less positive ones². There is therefore an increasing interest for pharmacological interventions that are traditionally used to treat various inner ear diseases and that are particularly effective in controlling symptoms if prescribed at higher dosages than in the past³ and/or as add-on medication in multi-component therapy⁴. Finally, there is accumulating evidence that drugs approved for use in other diseases can be prescribed “off-label” to patients affected by inner ear dysfunctions with satisfactory results⁵. For example, the 1-4 dihydropyridine calcium channel blocker nimodipine (NMDP) is approved by the Food and Drug Administration for reducing vasospasm after subarachnoid haemorrhage and neurological conditions⁶. Initially developed to treat high blood pressure, NMDP was more recently suggested to be an effective countermeasure for labyrinthine dysfunction^{7,8}, dizziness due to central nervous system disorders⁹ and migraine-related vertigo¹⁰. It has also been shown to prevent reduction of cochlear blood flow of different origins^{11,12}, and represents a potential therapeutic option for at least some types of tinnitus^{13,14}. Recent experience has shown that NMDP reduces the calcium intracellular overload in traumatised neurons so to exert an anti-apoptotic effect and improves the rate of nerve collateral re-sprouting, axonal growth and re-myelination of injured cranial nerves^{15,16}. Accordingly, its use in the prophylaxis and/or reparation of nerve damage occurring during head and neck surgery has been proposed^{17,18}. Despite this accumulating experimental and clinical evidence, which could potentially expand the prescription of NMDP in otolaryngology, its use in clinical practice is far from widespread. This manuscript: (a) briefly summarises the nature and function of calcium channels with particular attention to their role in auditory and vestibular systems; (b) reports on the experimental findings regarding the application of NMDP in inner ear function and dysfunction; and (c) reviews the evidence that suggest further indications for NMDP both as a single strategy or as an adjunct to standard care in otolaryngology.

Calcium channels: basic concepts

Voltage-gated calcium channels (VGCCs) are a group of ion-conducting pores located in the plasma membrane of excitable cells (e.g., muscle, glial cells, neurons, etc.) with a selective permeability to the calcium ion (Ca^{2+}). They belong to a large family of transmembrane ion channels that also include voltage-gated sodium, barium and potassium channels¹⁹. At resting membrane potential, VGCCs are normally closed and the concentration of Ca^{2+} is much higher outside of the cell than inside. In response to de-

polarisation, VGCCs allow Ca^{2+} to enter the cell and promote exocytosis which, depending on the cell type, results in activation of calcium-sensitive potassium channels, neurotransmitter and hormone release, muscular contraction, excitation of neurons and gene expression. The slow decline of cytoplasmic Ca^{2+} concentration after its initial rise to a peak level is due to both an increase of ion extrusion through a $\text{Na}^+\text{Ca}^{2+}$ exchange system at the plasma membrane and to reuptake into internal organelles. Malfunction of VGCCs can lead to an excess of intracellular calcium that over-activates enzymes such as nucleases²⁰ and phospholipases²¹ causing DNA injury and breakdown of phospholipids, respectively, which in turn irreversibly damage the membrane causing cellular death. VGCCs are complex proteins composed of distinct subunits (α_1 , $\alpha_2\delta$, β 1-4, and γ) (Fig. 1). The α_1 subunit with a mass of 190 to 250 kDa is the largest. It represents the primary subunit that forms the ion conducting pore necessary for channel functioning, determines most of the channel voltage-dependent opening and closing behaviours and contains the drug/toxin-binding sites. It is encoded by at least 10 different genes in mammals. It consists of four homologous (I-IV) domains containing six transmembrane α -helices each (S1-S6)²². The other subunits only exert an auxiliary modulation of the pharmacological and electrophysiological properties of VGCCs²³.

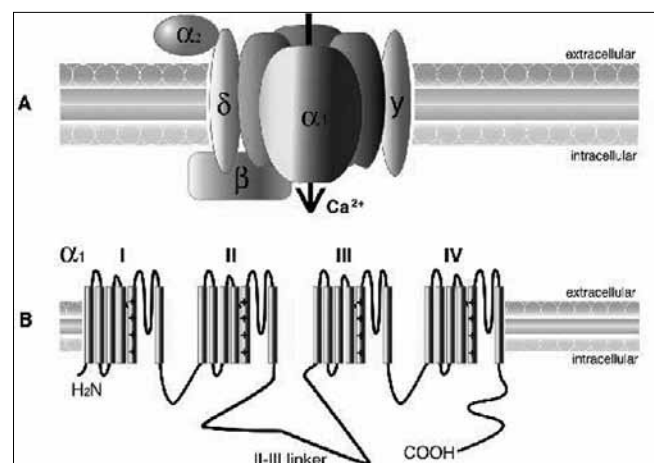


Fig. 1. A) Calcium channel structure comprising the α_1 , $\alpha_2\delta$, β , and γ subunits. The α_1 subunit, represented here with its 4-fold monomeric structure, is responsible for many of the functional characteristics of these channels, including the pore voltage-dependent gating and dihydropyridine binding. The α_2 is the extracellular glycosylated subunit that interacts with the α_1 subunit. The δ subunit has a single transmembrane region with a short intracellular portion that serves to anchor the protein in the plasma membrane. The β subunit is the only Ca^{2+} channel subunit that is entirely cytoplasmic. The γ subunit is a glycoprotein that, for the most part, is not required to regulate the channel complex. B) The α_1 subunit forms the Ca^{2+} selective pore, which contains voltage-sensing apparatus and drug/toxin-binding sites. This subunit contains 4 homologous domains (labelled I-IV), each containing 6 transmembrane helices (S1-S6).

Multiple types of Ca²⁺ channels are known and are classified according to differences in ionic conductance, gating modality and pharmacology. For instance, it was initially observed that most calcium channels need strong depolarisation for opening and are thus defined “high-voltage activated channels”; on the other hand, only a minority are activated by weak depolarisation and are referred to as “low-voltage activated channels”²⁴. A further alphabetical nomenclature was proposed for different types of calcium currents²⁵. For instance, most VGCCs are termed L-type because they inactivate slowly (“long-lasting”), need strong depolarisation to activate and are blocked by organic L-type calcium channel antagonists, such as the dihydropyridines nifedipine and NMDP²⁶. They are heterotetrameric polypeptide complexes comprising the α_1 , $\alpha_2\delta$, β , and, in some tissues, γ subunits. The α_1 subunit is encoded by CACNA1S, CACNA1C, CACNA1D and CACNA1F genes. Deficiency in 1D subunit of L-type Ca²⁺ channels causes the absence of L-type Ca²⁺ currents in cochlear inner hair cells and leads to degeneration of both outer and inner hair cells, with subsequent congenital deafness in the mouse²⁷.

Recently, a mutation in CACNA1D, which encodes for the pore-forming α_1 subunit of Ca(v)1.3 L-type calcium channel, has been identified in two consanguineous families with deafness. All deaf subjects also showed pronounced sinoatrial node dysfunction at rest²⁸. Auditory sensory hair cells of most species prevalently have L-type calcium channels.

P/Q-type calcium channels are present in Purkinje neurons in the cerebellum (and thus the name) and in cerebellar granule neurons. They are presynaptic high-voltage-gated calcium channels that couple neuronal excitation to release of neurotransmitter. The α_1 subunit is encoded by the CACNA1A gene and multiple splice variants exist in the central nervous system. Malfunction of P/Q channels due to mutations are probably associated with familial hemiplegic migraine type 1. In the mammalian auditory system, P/Q voltage-gated calcium channels modulate transmitter release at the olivo-cochlear efferent-inner hair cell cholinergic synapses, but their involvement in hearing defects is not known.

N-type (‘N’ for “Neural-Type”) Ca²⁺ channels are high-voltage activated calcium channels present throughout the central and peripheral nervous systems at presynaptic terminals. The α_1 subunit is encoded by CACNA1B gene. N-type voltage-gated calcium channels, as well the P/Q type are responsible for the synaptic activation of the inhibitory auditory efferent system.

The R-type calcium channel is a unique subtype of VGCC as its electrophysiological properties are intermediate between those of typical high-voltage-activated (P/Q-type, N-type, and L-type) or low-voltage-activated (T-type) channels. R-type channels are also typically resistant (thus the name) to antagonists of L-, N-, and P/Q-type Ca²⁺

Table I. Classification of voltage-gated calcium channels (VGCCs).

Classification of voltage-gated calcium channels (Cav) according to alphabetical nomenclature, electrophysiological properties (HVA: high voltage activated, LVA: low voltage activated), genetic determinants and dihydropyridine (DPH) sensitivity.

Type	Voltage	α_1 subunit (gene) Chromosome	DPH sensitivity
L-type calcium channel	HVA	Cav1.1 (<i>CACNA1S</i>) 1q32 Cav1.2 (<i>CACNA1C</i>) 12p13.3 Cav1.3 (<i>CACNA1D</i>) 3p14.3 Cav1.4 (<i>CACNA1F</i>) Xp11.23	Blocked
P/Q-type calcium channels	HVA	Cav2.1 (<i>CACNA1A</i>) 19p13	Resistant
N-type calcium channel	HVA	Cav2.2 (<i>CACNA1B</i>) 9q34	Resistant
R-type calcium channel	Intermediate	Cav2.3 (<i>CACNA1E</i>) 1q25.3	Resistant
T-type calcium channel	LVA	Cav3.1 (<i>CACNA1G</i>) 17q22 Cav3.2 (<i>CACNA1H</i>) 16p13.3 Cav3.3 (<i>CACNA1L</i>) 22q13.1	Partially blocked

channels. They have been identified in various areas of the CNS such as the cortex, hippocampus, striatum, amygdala, and interpeduncular nucleus and their role is believed to be predominantly implicated in spatial memory, fear behaviour, pain perception and morphine analgesia. The α_1 subunit is encoded by CACNA1E gene. Finally, T-type calcium channels are distinguished from other VGCCs by their low voltage thresholds for activation and inactivation. “T” stands for transient, referring to the length of activation. In many neurons, cytosolic Ca²⁺ influx through LVA channels triggers low-threshold spikes, which in turn trigger a burst of action potentials mediated by Na⁺ channels. T-type calcium channels contribute to the pacemaker activity of the sinoatrial node of the heart. The α_1 subunit is encoded by the CACNA1L gene.

A further classification of calcium channels was proposed in 2000²⁹, based on the chemical symbol of the ion (Ca), with the principal physiological regulator (voltage) indicated as a subscript (Cav). The Ca_v1 subfamily (Cav1.1 to Cav1.4) includes L-type calcium channels. The Cav2 (Cav2.1 to Cav2.3) includes P/Q-, R-, N-type calcium channels and the subfamily Cav3 (Cav3.1 to Cav3.3) identifies T-type calcium channels. The aforementioned main biochemical properties of VGCCs and their sensitivity to 1,4 dihydropyridine are summarised in Table I.

Calcium channels in the auditory and vestibular systems

The free intracellular concentration of calcium (Ca²⁺) in hair cells is very low at rest, but it rapidly increases due to entry through clusters of VGCCs in response to acoustic stimulation, which primarily allow the entry of cations close to the stereocilia tips at the cellular apex. The

calcium release from intracellular stores (endocytosis) is actually considered less relevant in this process. Calcium promotes vesicles fusion with the presynaptic membrane, leading to neurotransmitter release at the baso-lateral cellular wall³⁰, in order to activate auditory nerve terminals and generate action potential firing patterns. Hair cells, as retinal bipolar cells and photoreceptors, contain ribbon-type active zones. The synaptic ribbons are plate-like, proteinaceous structures packed with synaptic vesicles. The “ribbon” or “dense body” anchors to the presynaptic membrane only nanometres away from the clustered VGCCs (Fig. 2). Ribbons are thought to maintain exocytosis and sustained neurotransmitter release, albeit at reduced rates, in response to prolonged sound stimuli³¹. The intracellular spread of Ca^{2+} in hair cells is limited by the endogenous buffering activity of the cytosol. This system incorporates endogenous fixed and mobile Ca^{2+} buffers that limit the spread of free calcium in hair cells and carry incoming Ca^{2+} away from synaptic areas³². A plasma membrane Ca^{2+} -ATPase type 2 pump is responsible for extrusion of calcium from mammalian hair cells and its central role in intracellular calcium homeostasis is revealed by the hearing loss resulting from mutations in the plasma membrane CaATPase³³. Moreover, calcium influx into hair cells and its growing concentration opens Ca^{2+} -activated K^+ channels. The outward K^+ flow that follows repolarises the cell, closing Ca^{2+} channels and priming the cell for another cycle of oscillation. The number, distribution and kinetics of Ca^{2+} channels and K^+ channels determine the characteristic frequency at which a hair cell specifically responds and represents the basic process of electrical tuning in lower vertebrates’ cochlea³⁴. The presence of L-type channels is reported in the olivary nuclei, but they express a higher proportion of P/Q-type Ca^{2+} channels^{35 36} while T-type calcium channels are expressed in thalamic projection neurons to cortical auditory areas³⁷.

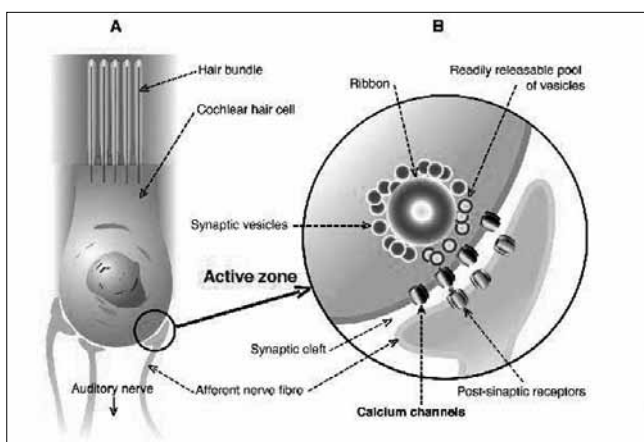


Fig. 2. A) schematic representation of cochlear hair cell structure with baso-lateral wall cytoplasmic membrane (marked with circle) and afferent auditory nerve bottoms; and B) presynaptic “active zone” with vesicles and ribbon containing neurotransmitters with clustered voltage-gated calcium channel (VGCCs).

The role of VGCCs in the vestibular end-organ is more debated. From animal experiments, it appears that the majority of VGCCs in semi-circular canals hair cells are L-type³⁸, although an R-type current component has been proposed based on its resistance to L- and N-type antagonists³⁹. Furthermore, an antibody to N-type subunits labelled the baso-lateral membranes of type I and type II hair cells⁴⁰, but further evidence is needed. Similarly, the saccular region displayed at least two different type of calcium channels, including L-type, both inhibited by nifedipine and promoted by the calcium-channel agonist Bay K 8644⁴¹. Besides this uncertainty, the mechanism of calcium sequestration for bio-crystallisation from endolymph through calcium pores is partially unknown, so that the formation and growth of otoconia remains to be elucidated⁴². In the brainstem, within the circuitry for the vestibulo-ocular reflex (VOR), neurons in the medial vestibular nucleus show adaptive changes in firing rate responses in relation to VOR gain (the ratio of evoked eye velocity to input head velocity). The firing rate response of neurons in the medial vestibular nuclei is reduced by increasing extracellular calcium and increased either by lowering extracellular calcium or with antagonists to calcium-dependent potassium channels⁴³. L-, N- and T-type calcium channels neurons are present in the medial vestibular nuclei^{44 45}, but their specific contribution to vestibular-ocular reflex is not fully understood. The large amount of ion-gated channels in hair cells found in these experimental studies points to their likely relevant role in highly excitable cells of both the cochlea and the labyrinth, supporting the hypothesis that inner ear dysfunction as complex as Ménière’s disease could be interpreted as channelopathy, particularly in those cases where familial expression of the disease is documented⁴⁶.

Nimodipine: from experimental data to clinical evidence

NMDP is a calcium channel blocker (CCB) belonging to the dihydropyridine class and is a highly lipophilic agent that rapidly crosses the blood-brain barrier (Fig. 3). Its mechanism of action is the selective blockage of intracellular calcium ions influx through L-type VGCCs. NMDP exerts a vasoactive effect by predominantly dilating small and collateral cerebral vessels, thus improving blood supply to hypo-perfused (post-ischaemia) areas and cerebral oxygenation even in healthy subjects⁴⁷. In the inner ear, the perilymphatic perfusion of NMDP is known to suppress both spontaneous neural noise and compound action potential. These are reversible and dose-dependent effects and provide support for an exclusively presynaptic role of L-type Ca^{2+} channels in the regulation of both spontaneous and evoked neurotransmitter release from hair cells⁴⁸. Similarly, the guinea pig compound action potential, the summing potential and the spontaneous firing of single

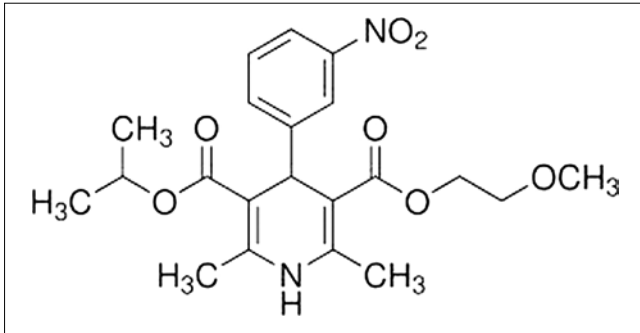


Fig. 3. Chemical structure and formula of nimodipine. 3-(2-methoxyethyl) 5-propan-2-yl 2,6-dimethyl-4-(3-nitrophenyl)-1,4-dihydropyridine-3,5-dicarboxylate $C_{21}H_{26}N_2O_7$.

cochlear ganglion neurons can be substantially reduced by the direct administration of NMDP in the cochlea⁴⁹. Recent findings have shown that Deiter's cells in the cochlea not only provide hair cells with supporting activity, but also contribute to their electrical and biomechanical properties. It has been suggested that these cells modify cochlear dynamics by influencing the force produced by sound-induced motion of outer hair cells, depending on their large voltage-activated, outwardly K^+ selective conductance. Even if voltage-activated Ca^{2+} currents are not present in Deiter's cells, NMDP interacts directly with K^+ channels in a voltage dependent manner and potentially interferes with depolarisation of the organ of Corti⁵⁰. The role of L-calcium channels in exerting presynaptic control on both acoustically provoked and spontaneous excitation of auditory nerve fibres appears to be of relevant interest since their abnormal function is suspected to be a potential source of annoying symptoms such as tinnitus⁵¹. The effect of selective Ca^{2+} channel agonists and antagonists on the afferent neuronal activity of isolated frog posterior semicircular canal is clearly documented^{52,53}; resting activity is substantially affected by all dihydropyridines, whereas only NMDP has been shown to significantly reduce the mechanically evoked activity³⁸. In particular, the stronger inhibitory activity of NMDP compared with nifedipine, also observed in isolated hair cells of the cochlea⁵⁴, may be due to their different biophysical and conformation-dependent interactions with the L-type calcium channel. Their overlapping actions on resting discharge could depend on different enzymatic patterns involved in rest and mechanically-evoked stimulation⁵⁵. Since the underlying pathogenic mechanism of Ménière's disease is an over-distension of the membranous structures of both the labyrinth and cochlea (endolymphatic hydrops) that modifies resting discharge of hair cells in the absence of sound stimuli and head movements, NMDP, cinnarizine and, partially, flunarizine qualify as a rational choice for this disease because of their selective activity on L-type calcium channels. The effects of mechanical over-stimulation of outer hair cells, such as that

by acoustic trauma, results in excessive entry of Ca^{2+} in hair cells⁵⁶ and its sustained intracellular overload primarily activates complex enzymatic reactions, namely phospholipase A2, protein kinase II and nitric oxide synthase that subsequently cause degeneration of the phospholipids of the membrane, cellular lysis and death⁵⁷. VGCCs are therefore supposed to be involved in the pathogenesis of acoustic injury in the auditory system as demonstrated by the recording of auditory brainstem responses (ABR) and morphological study of the cochlea in ddY mice after acoustic over-exposure⁵⁸. Many experiments in animals have been carried out to test the hypothesis that NMDP and other L-type calcium channel blockers can protect hair cells from acoustic trauma, but the results are so far inconclusive⁵⁹⁻⁶¹. In guinea pigs, cochlear blood flow (CBF) significantly decreases after administration of salicylate (100 mg/kg), but increases after administration of NMDP (2 mg/kg). After simultaneous administration of both salicylate (100 mg/kg) and NMDP (2 mg/kg), CBF remains unchanged. These results suggest that NMDP prevents the decrease in CBF induced by salicylate in animals⁶², but no experimental data are available for human CBF in relation to administration of VGCCs blockers alone or in association with ototoxic drugs. In order to study the efficacy of calcium antagonists in vertebrobasilar insufficiency, an animal model of VBI was developed by occluding one vertebral artery with a balloon catheter. Judging by the reversal of the nystagmic pattern, the CCBs flunarizine and NMDP were suggested to be effective drugs in this animal model⁶³. The protective effect of NMDP with respect to traumatic damage to the auditory nerve is documented by a recent study in rats⁶⁴. The histological examination of the temporal bones of NMDP-treated animals revealed significant preservation of spiral ganglion cells in the basal turn of the cochlea in response to experimentally provoked compression of the cerebellopontine angle portion of the eighth nerve. In humans, a prospective, randomised, double-blind study to assess the intra-operative efficacy of diltiazem (a non-dihydropyridine member of the calcium channel blocker family commonly used to treat hypertension and angina pectoris) in preventing acoustic trauma during otologic surgery was carried out in 1995⁶⁵. The results were influenced by a small postoperative sensorineural hearing loss in all cases (treated and placebo) and by the tendency for better preservation of the bone-conduction hearing threshold in the therapy group, although this did not reach statistical significance. No further trials regarding this possible indication have been reported to date. On the other hand, prophylactic treatment with NMDP is definitively shown to be effective in reducing both facial and cochlear nerve damage in humans due to vestibular schwannoma surgery^{17,66-68} by improving axon regeneration and collateral sprouting. One study¹⁷ showed that all patients who had received NMDP and hydroxyethyl starch-based prophyl-

laxis had a significant recovery of facial nerve function (House-Brackmann Grade I-II) compared with preoperative staging (House-Brackmann Grade III or worse), whereas one third of patients with pre-operative facial nerve paresis (House-Brackmann Grade III or worse) who had not received such prophylactic treatment were unchanged at long-term follow-up post-operation. In addition, in more than 50% of patients undergoing surgical removal of vestibular schwannoma without prophylactic medication, intraoperative brainstem auditory evoked potentials monitoring showed a sudden or slowly progressive loss of potentials. Despite prompt initiation of intraoperative vasoactive treatment, preservation of hearing function could not be obtained, suggesting that prophylaxis is superior to intraoperative vasoactive treatment. In a recent experience, the resected recurrent nerve due to removal of a thyroid cancer was repaired with a nerve graft and the patient was further treated with nimodipine for 3 months. After therapy, the electromyography showed complete re-innervation of laryngeal muscles¹⁸. This experience suggests the potential utility of NMDP as add-on therapy to prevent and/or facilitate re-innervation of both superior and recurrent laryngeal nerve lesions that may occur during thyroid surgery^{69 70} or of other nerves that could be damaged during neck dissection⁷¹. The use of CCBs in the treatment of peripheral vertigo has been reported for many years in Europe⁷² and their efficacy and safety has been tested in two double-blind studies that included different types of peripheral vestibular vertigo^{8 73}. In the first study, the effectiveness of NMDP (30 mg three times daily) was compared to cinnarizine (150 mg per day); after 12 weeks of treatment, the former drug reduced the incidence of moderate vertigo attacks to 78.8% of cases, and of severe vertigo in 85% of cases, whereas cinnarizine reduced 65.8% of moderate vertigo episodes and 89.8% of severe ones. Both NMDP and cinnarizine exhibited a significant therapeutic effect and similar safety profile. In the second study, conventional NMDP was administered three times daily at a dosage of 30 mg in 26 patients and its effect compared to that of an extended release formulation (90 mg, once a day) in 25 patients. After 8 weeks of extended release drug treatment, about 90% of both vertigo disability and severity was rated as decreased by 50%. In the conventional group, rating of severity was reduced by 50% in 90% of patients after 8 weeks whereas vertigo disability was decreased by 50% in 64% of cases. No significant difference was found between groups and both drug regimens were considered effective and well tolerated. While the aforementioned studies investigated the effectiveness of NMDP in the treatment of miscellaneous peripheral vestibular disorders, only one pilot study specifically explored the beneficial use of NMDP as monotherapy in medical treatment of Ménière's disease⁷. NMDP was prescribed to Ménière's disease patients whose first-line medical treatment

(diuretics, salt dietary restriction and vestibular suppressants) was not effective in controlling vertigo, or ameliorating or stabilising hearing loss. A recent retrospective analysis¹⁴ of 10-year experience in the long-term management of patients affected by definite Ménière's disease, diagnosed according to the American Academy of Otolaryngology-Head and Neck Surgery Committee on Hearing and Equilibrium diagnostic guidelines, highlighted a specific effect of NMDP as an add-on therapy for cochlear dysfunction⁷⁴. This study documented that a fixed combination of NMDP (at a dose of 40 mg a day) and betahistine (at a dose of 32 mg a day) for six months was more effective than monotherapy with betahistine (at a dose of 32 mg a day) for the same period in reducing the number of vertigo attacks, subjective annoyance due to tinnitus and severity of sensorineural hearing loss. These data suggest that NMDP should be prescribed as an add-on therapy in the long-term medical management of Ménière's disease in consideration of its efficacy on cochlear symptoms. This result confirms previous evidence on the beneficial effect of NMDP on tinnitus in both humans¹³ and animal models⁷⁵. Drug treatments are not commonly used for benign paroxysmal positional vertigo because different repositioning manoeuvres are now available to cure the unusual manifestations of otolith dysfunction^{76 77}, but it could be speculated that CCBs offer an attempt to prevent flare-ups in patients who are also affected with other peripheral vestibulopathies⁷⁸.

Finally, in order to test the effect of NMDP on the haemorheology and brainstem auditory evoked potentials (BAEP) in patients with vertebrobasilar insufficiency (VBI), a pilot study on 50 cases was carried out⁷⁹. Patients were divided into a NMDP group (25 cases) and a therapy-as-usual group (25 cases). Compared with the therapy-as-usual group, plasma viscosity was markedly decreased ($p < 0.05$) in the NMDP group, and peak latency of V wave, inter-peak latency of III-V and I-V were also improved significantly ($p < 0.05$). It was therefore suggested that NMDP could ameliorate central auditory pathway function through its beneficial effect on haemorheology in patients with vertebrobasilar insufficiency. This study further confirms the possible role of nimodipine in vestibular disorders since it has been shown that vertigo may also arise from cerebellar and cerebral vascular diseases⁸⁰, as reported below.

Further strategies and applications

Nimodipine and vertigo/dizziness of vascular origin

Vestibular compensation is a progressive neural process taking place in the central nervous system, which recalibrates vestibulo-oculomotor and vestibulo-spinal reflexes after peripheral vestibular-end organ failure and/or a vestibular (VIII nerve) neuritis. Its evolution is generally

thought to be complete and recovery may be achieved in a relatively short time in most cases. However, some patients complain of residual symptoms such as postural instability and episodic vertigo for long periods of time.

A single cause for this delayed compensation process is seldom identifiable and a multifactorial pathogenesis is most likely. For example, persistent vertigo and dizziness are more frequently observed in patients with cerebrovascular disease affecting those specific central nervous system areas and neural pathways that are supposed to be directly involved in vestibular compensation⁸¹. Moreover, it has been largely confirmed that patients with balance and gait disorders have a higher incidence of MRI white matter hyper-intensities due to white matter ischaemic disease and hypertension, so that cerebrovascular disorders may account for persistent vertigo *per se*⁸². Since the beneficial effects of NMDP on age-related cerebrovascular disorders in animals⁸³ and in human clinical trials⁸⁴⁻⁸⁶ are extensively documented, its use has been proposed in the treatment of vertigo in such patients. Interestingly, a study on elderly patients with chronic brain failure who received a single 30 mg oral dose of NMDP followed by two weeks treatment at a dose of 30 mg three times a day showed a significant amelioration of dizziness⁸⁷.

It should be added that both cerebrovascular diseases⁸⁸ and vertigo⁸⁹ are often associated with depression, a relevant cause of significant comorbidity. In a double-blind, randomised clinical trial⁹⁰, 101 patients diagnosed with "vascular depression" treated with fluoxetine at standard doses were randomised to placebo or NMDP administration. Treatment outcomes were assessed by the Hamilton Depression Rating Scale. Depression was decreased in both groups, but a greater improvement and a lower percentage of recurrence were seen in fluoxetine-NMDP patients. It should be added that in a previous multicentre, placebo-controlled, double-blind clinical study in 178 elderly patients with cognitive decline⁹¹, NMDP alone seemed to exert an antidepressant effect. Unfortunately, the exact mechanism of the probable antidepressant action of NMDP is unclear.

Finally, unlike other calcium channel blockers, NMDP can also modulate other calcium-dependent processes such as acetylcholine release, which is potentially of benefit in improving vestibular compensation in the elderly affected by uncompensated peripheral vestibular disorders and mild cognitive impairment due to cerebrovascular diseases⁹².

All these results clearly suggest a potential effect of NMDP in the pharmacological treatment of patients with uncompensated peripheral associated with cerebral vascular diseases presenting with persistent and recurrent dizziness. This indication seems to be most relevant in dizzy patients, and the elderly in particular, who are also affected by mood disturbance. Further investigations with appropriate study-designs are needed.

Nimodipine and vestibular migraine

Vestibular migraine (VM), also known as migraine-associated vertigo, is a common cause of dizziness in the adult population⁹³⁻⁹⁴, but in a large percentage of patients with vertigo, VM is under-diagnosed. Symptoms include spontaneous and positional vertigo, light-headedness and unsteadiness of variable duration, ranging from seconds to days. Some patients report a temporal relationship with the headache episode, but most do not. The wide variability in clinical presentation of patients with VM, lack of a generally accepted pathophysiologic model linking migraine and vertigo and the absence of specific biomarkers for the disease underlie the lack of commonly used criteria for diagnosis⁹⁵. A recent classification of vestibular migraine⁹⁶ postulates that a diagnosis of VM must be formulated on the basis of the following criteria:

- at least 5 episodes with vestibular symptoms of moderate or severe intensity, lasting 5 min to 72 hours;
- current or previous history of migraine with or without aura according to the International Classification of Headache Disorders (ICHD);
- one or more migraine features with at least 50% of vestibular episodes:
 - headache with at least two of the following characteristics:
 - one sided location, pulsating quality, moderate or severe pain intensity, aggravation by routine physical activity;
 - photophobia and phonophobia;
 - visual aura;
- not better accounted for by another vestibular or ICHD diagnosis.

Unfortunately, no standard medical treatment for acute attacks of VM is available, whereas prophylactic medications have been proposed.

A review of the pharmacological treatments of VM showed that common drugs routinely used in migraine prophylaxis (triptans, CCBs, nortriptyline, or metoprolol) can also be successfully prescribed to patients with VM⁹⁷. This finding has been recently confirmed by a retrospective analysis of 'epigone' migraine vertigo, a type of vertigo, migrainous in origin, starting late in lifetime and replacing, as an equivalent, a pre-existing migraine headache⁹⁸. This study reported successful results in the prophylaxis of both headache and vertigo spells after the administration of flunarizine. In addition, emerging clinical evidence supports not only a strong association between migraine and Ménière's disease⁹⁹, but also clearly indicates that patients with episodic vertigo, fluctuating hearing loss and migraine respond better to CCBs than to anti-hypertensive drugs¹⁰⁰⁻¹⁰¹.

The efficacy of NMDP in prophylaxis of migraine has been extensively investigated, but the results of placebo-controlled trials are controversial. Three of six comparative trials with placebo suggested no significant differ-

ence¹⁰²⁻¹⁰⁴, while the remaining three reported relatively large and statistically significant treatment effects¹⁰⁵⁻¹⁰⁷. This discrepancy could be due to many factors such as different types of migraine/headache included in the studies, dosages and duration of treatments and outcome measures used.

Taken together, these observations suggest an expanding indication for the use of NMDP in VM, but its potential efficacy needs to be documented in clinical trials with adequate study design.

Conclusions

The L-type calcium channel blocker NMDP has been widely utilised in numerous experimental and clinical investigations, far beyond its internationally approved indication. Primarily due to its vasoactive and neuroprotective effects on both the inner ear and the brain, it may be beneficial in many otoneurological syndromes, both peripheral, central and mixed, as monotherapy or as an add-on therapy to standard regimens. Its greater efficacy on aural symptoms such as tinnitus and hearing loss, if prescribed in association to betahistine compared to betahistine alone in the treatment of Ménière's disease, should be considered by otolaryngologists and audiologists and included in their routine pool of possible medications.

Since cerebrovascular lesions often cause gait disturbances and dizziness, and represent a possible cause of an uncompleted compensation of vestibular end-organ diseases, NMDP, by facilitating perfusion and oxygenation of human brain hypoxic areas, appears to be a rational choice in the treatment of vertigo of vascular origin. Despite existing uncertainties about the origin of vestibular migraine, it has been recently confirmed that patients suffering from this disease can be successfully treated with anti-migraine drugs so that NMDP may be an effective medical option considering both its efficacy as a migraine prophylactic drug and activity in inner ear disorders.

A more restricted field of application for NMDP is the surgery of the eighth nerve and cerebello-pontine angle lesions because of its neuroprotective effects, which are useful in preventing damage to both facial and cochlear nerves. It should be finally noted that despite increasing indications for the use of NMDP in otolaryngology, its prescription is still off-label in this field and informed consent should be obtained by patients before use.

References

- Thomsen J, Sass K, Ödkvist L, et al. *Local overpressure treatment reduces vestibular symptoms in patients with Ménière's Disease: a clinical, randomized, multicenter, double-blind, placebo-controlled study*. Otol Neurotol 2005;26:68-73.
- Hobson J, Chisholm E, El Refaie A. *Sound therapy (masking) in the management of tinnitus in adults*. Cochrane Database Syst Rev 2010;(12):CD006371.
- Strupp M, Hupert D, Frenzel C, et al. *Long-term prophylactic treatment of attacks of vertigo in Ménière's disease--comparison of a high with a low dosage of betahistine in an open trial*. Acta Otolaryngol 2008;128:520-4.
- Hahn A, Sejna I, Stefflova B, et al. *A fixed combination of cinnarizine/dimenhydrinate for the treatment of patients with acute vertigo due to vestibular disorders: a randomized, reference-controlled clinical study*. Clin Drug Investig 2008;28:89-99.
- Ganança MM, Caovilla HH, Ganança FF, et al. *Clonazepam in the pharmacological treatment of vertigo and tinnitus*. Int Tinnitus J 2002;8:50-3.
- Agnoli A. *The classification of calcium antagonists by the WHO expert committee: relevance in neurology*. Cephalalgia 1988;(Suppl 8):7-10.
- Lassen LF, Hirsch BE, Kameroner DB. *Use of nimodipine in the medical treatment of Ménière's disease: clinical experience*. Am J Otol 1996;17:577-80.
- Pianese CP, Hidalgo LO, González RH, et al. *New approaches to the management of peripheral vertigo: efficacy and safety of two calcium antagonists in a 12-week, multinational, double-blind study*. Otol Neurotol 2002;23:357-63.
- Wu C, Liao L, Yan X, et al. *Effects of Yangxue Qingnao Granules on chronic cerebral circulation insufficiency: a randomized, double-blind, double-dummy, controlled multicentre trial*. Psychogeriatrics 2013;13:29-34.
- Cha YH. *Migraine-associated vertigo: diagnosis and treatment*. Semin Neurol 2010;30:167-74.
- Ochi K, Kinoshita H, Kenmochi M, et al. *Effects of nimodipine on salicylate ototoxicity*. Ann Otol Rhinol Laryngol 2002;111:1092-6.
- Ma F, Li X, Zhong Z, et al. *Effects of nimodipine on cochlear blood flow with normal and vertebrobasilar insufficiency status*. Lin Chuang Er Bi Yah Hou Ke Za Zhi 2002;16:174-6.
- Davies E, Knox E, Donaldson I. *The usefulness of nimodipine, an L-calcium channel antagonists, in the treatment of tinnitus*. Br J Audiol 1994;28:125-9.
- Monzani D, Barillari MR, Alicandri Ciufelli M, et al. *Effect of a fixed combination of nimodipine and betahistine versus betahistine as monotherapy in the long-term treatment of Ménière's disease: a 10-year experience*. Acta Otorhinolaryngol Ital 2012;32:393-403.
- Angelov DN, Neiss WF, Streppel M, et al. *Nimodipine accelerates axonal sprouting after surgical repair of rat facial nerve*. J Neurosci 1996;16:1041-8.
- Mattsson P, Janson AM, Alikogius H, et al. *Nimodipine promotes regeneration and functional recovery after intracranial facial nerve crush*. J Comp Neurol 2001;437:106-17.
- Scheller C, Richter HP, Engelhardt M, et al. *The influence of prophylactic vasoactive treatment on cochlear and facial nerve functions after vestibular schwannoma surgery: a prospective and open-label randomized pilot study*. Neurosurgery 2007;61:92-8.
- Mattsson P, Björck G, Remahl S, et al. *Nimodipine and microsurgery induced recovery of the vocal cord after recurrent laryngeal nerve resection*. Laryngoscope 2005;115:1863-5.
- Yu FH, Catterall WA. *The VGL-kanome: a protein superfamily specialized for electrical signaling and ionic homeostasis*. Sci STKE 2004;253:p.re15.

- 20 Krause GS, White BC, Aust SD, et al. *Brain cell death following ischemia and reperfusion: a proposed biochemical sequence*. Crit Care Med 1988;16:714-26.
- 21 Siesjo BK. *Cell damage in the brain: a speculative synthesis*. J Cereb Blood Flow Metab 1981;1:155-85.
- 22 Catterall WA, Perez-Reyes E, Snutch TP, et al. *International Union of Pharmacology. XLVIII. Nomenclature and structure-function relationships of voltage-gated calcium channels*. Pharmacol Rev 2005;57:411-251.
- 23 Hofmann F, Biel M, Flockerzi V. *Molecular basis for Ca²⁺ channel diversity*. Annu Rev Neurosci 1994;17:399-418.
- 24 Carbone E, Lux HD. *A low voltage-activated fully inactivating Ca channel in vertebrate sensory neurons*. Nature 1984;310:501-2.
- 25 Tsien RW, Lipscombe D, Madison D, et al. *Reflections on Ca(2+)-channel diversity, 1988-1994*. Trends Neurosci 1995;18:52-4.
- 26 Fleckensstein A. *History of calcium antagonists*. Circ Res 1983;52:13-16.
- 27 Platzter J, Engel J, Schrott-Fischer A, et al. *Congenital deafness and sinoatrial node dysfunction in mice lacking class D L-type Ca²⁺ channels*. Cell 2000;102:89-97.
- 28 Baig SM, Koschak A, Lieb A, et al. *Loss of Ca(v)1.3 (CACNA1D) function in a human channelopathy with bradycardia and congenital deafness*. Nat Neurosci 2011;14:77-84.
- 29 Ertel EA, Campbell KP, Harpold MM, et al. *Nomenclature of voltage-gated calcium channels*. Neuron 2000;25:533-5.
- 30 Issa NP, Hudspeth AJ. *Clustering of Ca²⁺ channels and Ca(2+)-activated K⁺ channels at fluorescently labeled presynaptic active zones of hair cells*. Proc Natl Acad Sci USA 1994;91:7578-82.
- 31 Beutner D, Voets T, Neher E, et al. *Calcium dependence of exocytosis and endocytosis at the cochlear inner hair cell afferent synapse*. Neuron 2001;29:681-90.
- 32 Hall JD, Betarbet S, Jaramillo F. *Endogenous buffers limit the spread of free calcium in hair cells*. Biophys J 1997;73:1243-52.
- 33 Street VA, McKee-Johnson JW, Fonseca RC, et al. *Mutations in plasma membrane Ca²⁺-ATPase gene causes deafness in deafwaddler mice*. Nat Genet 1998;19:390-4.
- 34 Roberts WM, Howard J, Hudspeth AJ. *Hair cells: transduction, tuning, and transmission in the inner ear*. Annu Rev Cell Biol 1988;4:63-92.
- 35 Hirtz JJ, Boesen M, Braun N, et al. *Cav1.3 calcium channels are required for normal development of the auditory brainstem*. J Neurosci 2011;31:8280-94.
- 36 Barnes-Davies M, Owens S, Forsythe ID. *Calcium channels triggering transmitter release in the rat medial superior olive*. Hear Res 2001;162:134-45.
- 37 Bayazitov IT, Westmoreland JJ, Zakharenko SS. *Forward suppression in the auditory cortex is caused by the Ca(v)3.1 calcium channel-mediated switch from bursting to tonic firing at thalamocortical projections*. J Neurosci 2013;33:18940-50.
- 38 Perin P, Soto E, Vega R, et al. *Calcium channels functional roles in the frog semicircular canal*. Neuroreport 2000;11:417-20.
- 39 Martini M, Rossi ML, Rubbini G, et al. *Calcium currents in hair cells isolated from semicircular canals of the frog*. Biophys J 2000;78:1240-54.
- 40 Lopez I, Ishiyama G, Ishiyama A, et al. *Differential subcellular immunolocalization of voltage-gated calcium channel alpha1 subunits in the chinchilla cristae ampullaris*. Neuroscience 1992;92:773-82.
- 41 Su ZL, Jiang SC, Gu R, et al. *Two types of calcium channels in bullfrog saccular hair cells*. Hear Res 1995;87:62-8.
- 42 Lundberg YW, Zhao X, Yamoah EN. *Assembly of the otoconia complex to the macular sensory epithelium of the vestibule*. Brain Res 2006;1091:47-57.
- 43 Serafin M, Khateb A, de Waele C, et al. *Low threshold calcium spikes in medial vestibular nuclei neurons in vitro: a role in the generation of the vestibular nystagmus quick phase in vivo?* Exp Brain Res 1990;82:187-90.
- 44 Serafin M, de Waele C, Khateb A, et al. *Medial vestibular nucleus in the guinea-pig: II. Ionic basis of the intrinsic membrane properties in brainstem slices*. Exp Brain Res 1991;84:426-33.
- 45 Smith MR, Nelson AB, Du Lac S. *Regulation of firing response gain by calcium-dependent mechanisms in vestibular nucleus neurons*. J Neurophysiol 2002;87:2031-42.
- 46 Gates P. *Hypothesis: could Meniere's disease be a channelopathy?* Intern Med J 2005;35:488-9.
- 47 Canova D, Roatta S, Miciceli G, et al. *Cerebral oxygenation and haemodynamic effects induced by nimodipine in healthy subjects*. Funct Neurol 2012;27:169-76.
- 48 Sueta T, Zhang SY, Sellick PM, et al. *Effects of a calcium channel blocker on spontaneous neural noise and gross action potential waveforms in the guinea pig cochlea*. Hear Res 2004;188:117-25.
- 49 Robertson D, Paki B. *Role of L-Type Ca²⁺ channels in transmitter release from mammalian inner hair cells. II. Single neuron activity*. J Neurophysiol 2002;87:2734-40.
- 50 Nenov AP, Chen C, Bobbin RP. *Outward rectifying potassium currents are the dominant voltage activated currents present in Deiters' cells*. Hear Res 1998;123:168-82.
- 51 Jastreboff PJ, Brennan JF. *Special effects of nimodipine on the auditory system*. Ann NY Acad Sci 1988;522:716-8.
- 52 Masetto S, Russo G, Taglietti V, et al. *K⁺ and Ca⁺⁺ currents in hair cells isolated from the semicircular canals of the frog*. Boll Soc Ital Biol Sper 1991;67:493-500.
- 53 Prigioni I, Masetto S, Russo G, et al. *Calcium currents in solitary hair cells isolated from frog crista ampullaris*. J Vestib Res 1992;2:31-9.
- 54 Lin X, Hume RI, Nuttall AL. *Dihydropyridines and verapamil inhibit voltage-dependent K⁺ current in isolated outer hair cells of the guinea pig*. Hear Res 1995;88:36-46.
- 55 Guth PS, Aubert A, Ricci AJ, et al. *Differential modulation of spontaneous and evoked neurotransmitter release from hair cells: some novel hypotheses*. Hear Res 1991;56:69-78.
- 56 Fridberger A, Flock A, Ulfendahl M, et al. *Acoustic overstimulation increases outer hair cell Ca²⁺ concentrations and causes dynamic contractions of the hearing organ*. Proc Natl Acad Sci U S A 1998;95:7127-32.
- 57 Trump BF, Berezesky IK. *The role of cytosolic Ca²⁺ in cell injury, necrosis and apoptosis*. Curr Opin Cell Biol 1992;4:227-32.
- 58 Uemaetomari I, Tabuchi K, Nakamagoe M, et al. *L-type voltage-gated calcium channel is involved in the pathogen-*

- esis of acoustic injury in the cochlea. *Tohoku J Exp Med* 2009;218:41-7.
- 59 Boettcher FA, Caldwell RK, Gratton MA, et al. *Effects of nimodipine on noise-induced hearing loss*. *Hear Res* 1998;121:139-46.
- 60 Ison JR, Payman GH, Palmer MJ, et al. *Nimodipine at a dose that slows ABR latencies does not protect the ear against noise*. *Hear Res* 1997;106:179-83.
- 61 Kansu L, Ozkarakas H, Efendi H, et al. *Protective effects of pentoxifylline and nimodipine on acoustic trauma in Guinea pig cochlea*. *Otol Neurotol* 2011;32:919-25.
- 62 Ochi K, Kinoshita H, Kenmochi M, et al. *Effects of nimodipine on salicylate ototoxicity*. *Ann Otol Rhinol Laryngol* 2002;111:1092-6.
- 63 Hofferberth B. *Calcium entry blockers in the treatment of vertebrobasilar insufficiency*. *Eur Neurol* 1986;25(Suppl 1):80-5.
- 64 Sekiya T, Yagihashi A, Asano K, et al. *Nimodipine ameliorates trauma-induced cochlear neuronal death*. *Neurol Res* 2002;24:775-80.
- 65 Maurer J, Riechelmann H, Amedee RG, et al. *Diltiazem for prevention of acoustical trauma during otologic surgery*. *ORL J Otorhinolaryngol Relat Spec* 1995;57:319-24.
- 66 Strauss C, Bischoff B, Neu M, et al. *Vasoactive treatment for hearing preservation in acoustic neuroma surgery*. *J Neurosurg* 2001;95:771-7.
- 67 Scheller C, Strauss C, Fahlbusch R, et al. *Delayed facial nerve paresis following acoustic neuroma resection and postoperative vasoactive treatment*. *Zentralbl Neurochir* 2004;65:103-7.
- 68 Strauss C, Bischoff B, Romstock J, et al. *Hearing preservation in medial vestibular schwannomas*. *J Neurosurg* 2008;109:70-6.
- 69 Marchese-Rangona R, Restivo DA, Mylonakys I, et al. *The superior laryngeal nerve injury of a famous soprano, Amelita Galli-Curci*. *Acta Otorhinolaryngol Ital* 2013;33:67-71.
- 70 Rulli F, Ambrogi V, Dionigi G. *Meta-analysis of recurrent laryngeal nerve injury in thyroid surgery with or without intraoperative nerve monitoring*. *Acta Otorhinolaryngol Ital* 2014;34:223-9.
- 71 Lee CH, Huang NC, Chen HC, et al. *Minimizing shoulder syndrome with intra-operative spinal accessory nerve monitoring for neck dissection*. *Acta Otorhinolaryngol Ital* 2013;33:93-6.
- 72 Olesen J. *Calcium entry blockers in the treatment of vertigo*. *Ann NY Sci* 1988;522:690-7.
- 73 Lisbeth M, Consuelo P, Glenda C, et al. *Evaluation of the effect of nimodipine o.d. (extended release) vs nimodipine t.i.d. in the treatment of peripheral vertigo*. *Curr Drug Deliv* 2013;10:343-7.
- 74 *Committee on Hearing and Equilibrium guidelines for the diagnosis and evaluation of therapy in Ménière's Disease*. *Otolaryngol Head Neck Surg* 1995;113:181-5.
- 75 Wang H, Jiang S, Yang W, et al. *Evaluating effects of some medicine on tinnitus with animal behavioural model in rats*. *Zhonghua Er Bi Yan Hou Ke Za Zhi* 2000;25:331-4.
- 76 Califano L, Vassallo A, Melillo MG, et al. *Direction-fixed paroxysmal nystagmus lateral canal benign paroxysmal positioning vertigo (BPPV): another form of lateral canalolithiasis*. *Acta Otorhinolaryngol Ital* 2013;33:254-60.
- 77 Califano L, Salafia F, Mazzone S, et al. *Anterior canal BPPV and apogeotropic posterior canal BPPV: two rare forms of vertical canalolithiasis*. *Acta Otorhinolaryngol Ital* 2014;34:189-97.
- 78 Balatsouras DG, Ganelis P, Aspris A, et al. *Benign paroxysmal positional vertigo associated with Meniere's disease: epidemiological, pathophysiological, clinical, and therapeutic aspects*. *Ann Otol Rhinol Laryngol* 2012;121:682-8.
- 79 Zang Jian-hong, Fan Jian-zhong, Qi Zhi-qiang. *Effect of nimodipine on hemorrhology and BAEP in the patients with vertebrobasilar insufficiency*. *Cin J Reab Te Prac* 2002;11:679-81.
- 80 Armato E, Ferri E, Pinzani A, et al. *Cerebellar haemorrhage mimicking acute peripheral vestibulopathy: the role of the video head impulse test in differential diagnosis*. *Acta Otorhinolaryngol Ital* 2014;34:288-91.
- 81 Furman JM, Balaban CD, Pollack IF. *Vestibular compensation in a patient with a cerebellar infarction*. *Neurol* 1997;48:916-20.
- 82 Franch O, Calandre L, Alvarez-Linera J, et al. *Gait disorders of unknown cause in the elderly: Clinical and MRI findings*. *J Neurol Sci* 2009;280:84-6.
- 83 De Jong GI, Traber J, Luiten PGM. *Formation of cerebrovascular anomalies in the aging rats is delayed by chronic nimodipine application*. *Mech Aging Dev* 1992;64:255-72.
- 84 Rossi R, Inzitari D, Pantoni L, et al. *Nimodipine in subcortical vascular dementia trial*. *Alzheimer Dis Assoc Disord* 1999;13(Suppl 3):S159-5.
- 85 Pantoni L, Rossi R, Inzitari D, et al. *Efficacy and safety of nimodipine in subcortical vascular dementia: a subgroup analysis of the Scandinavian Multi-Infarct Dementia Trial*. *J Neurol Sci* 2000;175:124-34.
- 86 Pantoni L, del Ser T, Sogliani AG, et al. *Efficacy and safety of nimodipine in subcortical vascular dementia: a randomized placebo-controlled trial*. *Stroke* 2005;36:619-24.
- 87 Eicher H, Hilgert D, Zeeh J, et al. *Pharmacokinetics of nimodipine in multimorbid elderly patients with chronic brain failure*. *Arch Gerontol Geriatr* 1992;14:309-19.
- 88 Göthe F, Enache D, Wahlund LO, et al. *Cerebrovascular diseases and depression: epidemiology, mechanisms and treatment*. *Panminerva Med* 2012;54:161-70.
- 89 Chandra RK, Epstein VA, Fishman AJ. *Prevalence of depression and antidepressant use in an otolaryngology patient population*. *Otolaryngol Head Neck Surg* 2009;141:136-8.
- 90 Taragano FE, Bagnatti P, Allegri RF. *A double-blind, randomized clinical trial to assess the augmentation with nimodipine of antidepressant therapy in the treatment of "vascular depression"*. *Int Psychogeriatr* 2005;17:487-98.
- 91 Ban TA, Morey L, Aguglia E, et al. *Nimodipine in the treatment of old age dementias*. *Prg Neuropsychopharmacol Biol Psychiatry* 1990;14:525-51.
- 92 Monzani D, Genovese E, Marrara A, et al. *Stimulation of the cholinergic neurotransmissions enhances the efficacy of vestibular rehabilitation*. *Acta Otorhinolaryngol Ital* 2010;30:11-9.
- 93 Neuhauser HK, von Brevern M, Radtke A, et al. *Epidemiol-*

- ogy of vestibular vertigo: a neurotologic survey of the general population. *Neurol* 2005;65:898-904.
- ⁹⁴ Pagnini P, Verrecchia L, Giannoni B, et al. *Migraine-related vertigo (MV)*. *Acta Otorhinolaryngol Ital* 2003;23:(5 Suppl 75):19-27.
- ⁹⁵ Savundra PA, Carroll JD, Davies RA, et al. *Migraine-associated vertigo*. *Cephalalgia* 1997;17:505-10.
- ⁹⁶ Lempert T, Olesen J, Furman J, et al. *Vestibular migraine: diagnostic criteria*. *J Vestib Res* 2012;22:167-72.
- ⁹⁷ Fotuhi M, Glaun B, Quan SY, et al. *Vestibular migraine: a critical review of treatment trials*. *J Neurol* 2009;256:711-6.
- ⁹⁸ Pagnini P, Vannucchi P, Giannoni B, et al. *Epigone migraine vertigo (EMV): a late migraine equivalent*. *Acta Otorhinolaryngol Ital* 2014;34:62-70.
- ⁹⁹ Ibekwe TS, Fasunla JA, Ibekwe PU, et al. *Migraine and Menière's disease: two different phenomena with frequently observed concomitant occurrences*. *J Natl Med Assoc*. 2008;100:334-8.
- ¹⁰⁰ Goto F, Tsutsumi T, Ogawa K. *Migraine-associated vertigo with hearing loss and recurrent vertigo attack*. *Nihon Jibiinkoka Gakkai Kaiho* 2013;116:600-5.
- ¹⁰¹ Teggi R, Fabiano B, Recanati P, et al. *Case reports on two patients with episodic vertigo, fluctuating hearing loss and migraine responding to prophylactic drugs for migraine. Menière's disease or migraine-associated vertigo?* *Acta Otorhinolaryngol Ital* 2010;30:217-21.
- ¹⁰² Ansell E, Fazzone T, Festenstein R, et al. *Nimodipine in migraine prophylaxis*. *Cephalalgia* 1988;8:269-72.
- ¹⁰³ Migraine-Nimodipine European Study Group (MINES). *European multicenter trial of nimodipine in the prophylaxis of classic migraine (migraine with aura)*. *Headache* 1989;29:639-42.
- ¹⁰⁴ Migraine-Nimodipine European Study Group (MINES). *European multicenter trial of nimodipine in the prophylaxis of common migraine (migraine without aura)*. *Headache* 1989;29:633-38.
- ¹⁰⁵ Gelmers HJ. *Nimodipine, a new calcium antagonist, in the prophylactic treatment of migraine*. *Headache* 1983;23:106-135.
- ¹⁰⁶ Havanka-Kanniainen H, Hokkanen E, Myllylä VV. *Efficacy of nimodipine in the prophylaxis of migraine*. *Cephalalgia* 1985;5:39-43.
- ¹⁰⁷ Bussone G, Baldini S, D'Andrea G, et al. *Nimodipine versus flunarizine in common migraine: a controlled pilot trial*. *Headache* 1987;27:76-9.

Received: November 7, 2014 - Accepted: March 8, 2015

HEAD AND NECK

Supratracheal laryngectomy: current indications and contraindications

Laringectomia sopratracheale: indicazioni e controindicazioni

G. SUCCO¹, M. BUSSI², L. PRESUTTI³, S. CIRILLO⁴, E. CROSETTI⁵, A. BERTOLIN⁶, L. GIORDANO², G. MOLteni³, M. PETRACCHINI⁴, A.E. SPRIO⁷, G.N. BERTA⁷, A. FORNARI⁸, G. RIZZOTTO⁶

¹Otolaryngology Service, Oncology Department, "San Luigi Gonzaga" Hospital, University of Turin, Italy; ²Otolaryngology Service, Head and Neck Department, "San Raffaele" Hospital, University of Milan, Italy; ³Otolaryngology Service, Head and Neck Department, Policlinico Hospital, University of Modena, Italy; ⁴Radiology Service, Mauriziano Hospital, Turin, Italy; ⁵Otolaryngology Service, Martini Hospital, Turin, Italy; ⁶Otolaryngology Service, Vittorio Veneto Hospital, Treviso, Italy; ⁷Department of Clinical and Biological Sciences, University of Turin, Italy; ⁸Pathology Service, Oncology Department "San Luigi Gonzaga" Hospital, University of Turin, Italy

SUMMARY

Cancer of the larynx in the intermediate/advanced stage still presents a major challenge in terms of controlling the disease and preserving the organ. Supratracheal partial laryngectomy (STPL) has been described as a function-sparing surgical procedure for laryngeal cancer with sub-glottic extension. The aim of the present multi-institutional study was to focus on the indications and contraindications, both local and general, for this type of surgery based on the long-term oncological and functional results. We analysed the clinical outcomes of 142 patients with laryngeal cancer staged pT2-pT4a who underwent STPL. Five-year overall survival (OS), disease-specific survival (DSS), disease-free survival (DFS) and loco-regional control (LRC) rates were: glottic pT2 [71.4%, 95.2%, 76.0%, 76.0%], glottic-transglottic pT3 [85.3%, 91.1%, 86.4%, 88.7%], and pT4a [73.2%, 88.1%, 52.7%, 60.7%], respectively. DFS and LRC prevalences at 5 years were greatly affected by pT4a staging. Five-year laryngeal function preservation (LFP) and laryngectomy free survival (LFS) were: glottic pT2 [90.9%, 95.2%], glottic-transglottic pT3 [84.4%, 93.1%], and pT4a [63.7%, 75.5%], respectively, being affected by pT staging and age 65 ≥ years (LFP 54.1%). As a result of Type III open horizontal partial laryngectomies (OPHLs) (supratracheal laryngectomies), the typical subsites of local failure inside the larynx were the mucosa at the passage between the remnant larynx and trachea, the mucosa at the level of the posterior commissure and the contralateral cricoarytenoid unit as well as outside the larynx at the level of the outer surface of the remnant larynx. For patients with glottic or transglottic tumours and with sub-glottic extension, the choice of STPL can be considered to be effective, not only in prognostic terms, but also in terms of functional results.

KEY WORDS: Laryngectomy • Laryngeal cancer • Contraindications

RIASSUNTO

Il cancro della laringe in fase intermedio / avanzata rappresenta ancora una grande sfida in termini di controllo della malattia e di preservazione d'organo. La laringectomia parziale sopratracheale (STPL) è stata descritta come procedura chirurgica di function-sparing per il cancro della laringe con estensione sub-glottica. Lo scopo del presente studio multi-istituzionale è di concentrarsi sulle indicazioni e controindicazioni, sia locali che generali, per questo tipo di chirurgia sulla base dei risultati oncologici e funzionali a lungo termine. Abbiamo analizzato i risultati clinici di 142 pazienti con cancro della laringe in stadio pT2-pT4a sottoposti a STPL. A cinque anni i tassi di sopravvivenza globale (OS), di sopravvivenza malattia specifica (DSS), di sopravvivenza libera da malattia (DFS) e di controllo loco-regionale (LRC) sono risultati rispettivamente: pT2 glottici [71,4%, 95,2%, 76,0%, 76,0%], pT3 glottici-transglottici [85,3%, 91,1%, 86,4%, 88,7%], e pT4a [73,2%, 88,1%, 52,7%, 60,7%]. La DFS ed il LRC a 5 anni sono risultati fortemente influenzati dallo stadio pT4a. A cinque anni i tassi di conservazione della funzione laringea (LFP) e la sopravvivenza libera da laringectomia (LFS) sono risultati: pT2 glottici [90,9%, 95,2%], pT3 glottici-transglottici [84,4%, 93,1%] e pT4a [63,7%, 75,5%], risultando negativamente influenzati dal pT staging e dall'età di 65 ≥ anni (LFP 54,1%). A seguito di laringectomia parziale sopratracheale le sedi tipiche di recidiva sono risultate all'interno della laringe la mucosa al passaggio fra laringe residua e trachea, la mucosa a livello della commissura posteriore, l'unità cricoaritenoidica controlaterale e all'esterno la superficie esterna della laringe residua. Per i casi di tumore glottico con estensione subglottica o di tumore con importante estensione transglottica, la scelta di una STPL può essere considerata efficace, non solo in termini prognostici, ma anche in termini di risultati funzionali.

PAROLE CHIAVE: Laringectomia parziale • Cancro della laringe • Indicazioni • Controindicazioni

Acta Otorhinolaryngol Ital 2015;35:146-156

Introduction

The subglottic extent of a glottic or transglottic tumour is often difficult to detect preoperatively, has a large propensity for extralaryngeal spread and poor prognosis, espe-

cially when adopting conservative therapeutic protocols such as chemoradiotherapy, transoral laser surgery or open partial laryngectomy¹⁻³.

In 1972, Italo Serafini⁴ reported a new type of open partial laryngectomy called tracheohyoidoepiglottopexy aimed at

managing laryngeal cancer with subglottic extension: this procedure entailed the preservation of the suprahyoid epiglottis as well as the pexy of the hyoid bone and the residual epiglottis to the first tracheal ring. Because of removal of both arytenoids, the resulting functional outcomes were poor and Serafini abandoned this technique in the early 1980s.

In the 1990s, Laccourreye et al.⁵ applied a modification of conventional supracricoid partial laryngectomy (SCPL), removing the cricoid ring in the case of glottic tumours with anterior sub-glottic extension: this has opened the way for “functional” supratracheal partial laryngectomies (STPL), whose current version was described in 2006 by Rizzotto et al.⁶

Nowadays, STPL involves resection of the entire glottic and subglottic sites along the thyroid cartilage, sparing both or at least one functioning cricoarytenoid unit (i.e. half of the posterior cricoid plate, with the corresponding arytenoid and the intact inferior laryngeal nerve on the same side). Inferiorly, the limit of resection encompasses the cricoid reaching the first tracheal ring.

Recently, the European Laryngological Society proposed a classification of the more commonly adopted procedures according to the extent of resection⁷, including three types of OPHL: Type I – supraglottic, Type II – supracricoid, and Type III – supratracheal.

In our practice, OPHL Type III expands the indications suggested by the National Comprehensive Cancer Network (NCCN) and the Italian Head and Neck Society (IHNS) guidelines for the treatment of laryngeal cancer with conservative surgery (T1–T2, N0 or selected T3): some problematic glottic cT3 (i.e. sub-glottic extension and cricoarytenoid joint invasion) and some large glottic-transglottic cT3 now became manageable by OPHL, showing promising oncological and functional results^{8,9}. With great caution, the same practice can be considered to be an upfront option in a very limited number of cT4a cases, with minimal anterior extralaryngeal extension, when it is reasonable to expect an exclusive treatment.

The aim of the present study is to focus on the indications and contraindications, both local and general, for this type of surgery. A multicentric retrospective outcome analysis of 142 patients, suffering from glottic/transglottic laryngeal squamous cell carcinoma (SCC) with subglottic extension in intermediate/advanced stage, was carried out over a 10-year period during which organ-preservation protocols with chemoradiotherapy or total laryngectomy were applied as conventional therapeutic options for these types of locally advanced tumours.

Materials and methods

Patients

All patients were from the Hospital of Vittorio Veneto, Treviso, the Martini Hospital of Turin, the San Raffaele Hospital of Milan, and the Policlinico Hospital of Modena. Selection

was based on clinical and radiologic evaluation performed within 3 weeks of surgery, to evaluate the superficial and depth extent of the tumour, as previously described¹⁰.

Inclusion criteria were histological diagnosis of intermediate/advanced stage glottic or transglottic laryngeal SCC⁸, laryngeal chondrosarcoma¹¹ or other rare tumours, and a Karnofsky index¹² higher than 80.

The tumours were glottic in 113 patients and transglottic in 29 patients. Vocal fold mobility was: 31 cases with normal or impaired vocal cord mobility (22 glottic pT2, 9 supraglottic pT4a), 52 cases with fixed vocal cord and mobile cricoarytenoid joint (10 transglottic pT3, 3 supraglottic pT4a, 16 glottic-subglottic pT3, and 23 glottic pT4a) and 59 cases with fixed vocal cord and cricoarytenoid joint (7 transglottic pT3, 31 glottic-subglottic pT3, and 21 glottic pT4a).

Exclusion criteria were severe diabetes mellitus, severe bronchopulmonary chronic obstructive disease, neurological problems impairing the ability to expectorate and/or swallow, or severe cardiac disease. Advanced age, an important cut-off for relative surgical indication¹³, was not considered, in itself, an exclusion criterion.

Surgery

After informed consent had been obtained, 142 patients were selected to undergo Type III OPHL between August 29, 2002 and December 28, 2012.

Despite the fact that most of these cases had already been included elsewhere⁹, the preoperative and intraoperative records, and pathological reports were reviewed to allow proper reclassification of these cases according to the 2002 TNM classification system¹⁴.

Forty-eight patients (33.8%) included in the present analysis had been treated previously for laryngeal carcinoma by CO₂ transoral laser surgery (27 of 142; 19.0%), (chemo)-radiation therapy (12 of 142; 8.5%), open partial laryngectomy (4 of 142; 2.8%), or cordectomy (5 of 142; 3.5%).

Accordingly to the European Laryngological Society Classification⁷, only Type III OPHLs were performed, where “+CAU” represents the removal of one cricoarytenoid unit: Type IIIa (supratracheal partial laryngectomy/tracheo-hyoido-epiglottopexy) = 13 (9.2%), Type IIIa + CAU = 108 (76.1%), Type IIIb (supratracheal partial laryngectomy/tracheo-hyoido-pexy) = 7 (4.9%), Type IIIb + CAU = 14 (9.9%). In all patients, resection margins were examined intraoperatively with frozen sections: when positive, the resection was expanded until margins were negative. The margins of the surgical specimen were always checked again upon definitive pathology.

Neck dissection (ND), graded according to the American Academy of Otolaryngology-Head and Neck Surgery Foundation classification¹⁵, was performed in 101 patients (71.1%) and was monolateral in 56 (55.4%) and bilateral in 45 (44.6%) cases. ND was elective (ND levels II–IV) in 90 cN0 patients (63.4%), and curative (ND levels II–V

+ internal jugular vein in one case) in 11 cN > 0 patients (7.7%). In 67 patients, whole level VI or unilateral paratracheal lymph node clearance was added. No ND was performed in an additional 41 patients (28.9%) (elderly and/or cN0 disease or in previously treated neck).

Postoperative care and adjuvant treatments

All patients were monitored for early complications (local and general) and late sequelae. Apart from those with serious early complications, patients underwent the same rehabilitation protocol, which included: (1) insertion of an uncuffed tracheal cannula and beginning of phonation (days 1 to 4); (2) intermittent occlusion of the tracheostomy with saline-soaked gauze and starting of feeding without the tracheal cannula in position (days 4 to 6); (3) nasogastric (NG) tube removal as soon as a good level of swallowing of both solids and liquids had been achieved (day 6 onwards)¹². Postoperative aspiration was graded in accordance with Pearson's scale¹⁶ (0 = none; I = occasional cough but no clinical problems; II = constant cough worsening with meal or swallowing; III = pulmonary complications).

Adjuvant treatments

On the basis of pathological findings (pN+ and/or extracapsular spread (ECS), large extralaryngeal extent), 41 patients (28.9%) were subjected to adjuvant radiotherapy. The indications for adjuvant therapy were: 13 N+ (8 level VI N+ and 5 pN2) and 28 cases with extralaryngeal extent (9 supraglottic pT4a and 19 glottic pT4a).

A large volume encompassing the primary site and all draining lymph nodes was irradiated with a dose of up to 54 Gy/2 Gy. Regions at higher risk for malignant dissemination received a 12-Gy boost (total 66 Gy/2 Gy – range 62–68 Gy). Six of 41 patients (level VI- Delphian node pN+ and pN2 with ECS, and pT4a showing close margins toward pre-laryngeal tissues) also received 100 mg/m² cisplatin on days 1, 22 and 43 of the course of radiotherapy¹⁷.

Statistical methods

Overall survival (OS), disease-specific survival (DSS), disease-free survival (DFS), loco-regional control (LRC), local control (LC), laryngectomy-free survival (LFS) and laryngeal function preservation (LFP) were assessed by Kaplan–Meier curves. Log-rank and Gehan-Breslow-Wilcoxon tests (for early events) were used to compare Kaplan–Meier estimates between groups (staging, clinical history of previous treatment, and age). The corresponding incidences were evaluated by chi-squared tests. The endpoints considered were obtained as the length of time from the date of diagnosis to: OS – the date of death; DSS – the date of death from the disease; DFS – the date of the first recurrence; LRC – the date of the first loco-regional recurrence; LC – the date of the first local recurrence; LFS – the date of total laryngectomy; LFP – the date of total laryngectomy or presence of tracheostomy,

NG tube, gastrostomy feeding, or non-intelligible voice. All analyses were performed with GraphPad Prism version 6.0c (GraphPad Software, San Diego CA, USA), with $p < 0.05$ as the statistically significant cut-off.

Results

Patients

In total, 148 patients undergoing STPLs were initially included in this study. After excluding those treated for non-SCC, a cohort of 142 patients undergoing Type III OPHLs was considered. Current or former smokers made up 92% of the cohort. Patients were followed for a mean period of 3.29 years.

Pathology

All patients suffered from a biopsy-proven glottic or transglottic laryngeal SCC, which was classified as pT2, pT3 or pT4a, according to the 2002 TNM classification system¹⁴. Furthermore, pathology reports indicated close margins (< 2 mm) in 13 cases (9.1%), and positive margins were not found in any case at definitive histopathologic examination. One hundred and thirty-one patients (92.3%) had been staged as cN0 by palpation and neck CT scan or MRI. Overall, lymph node metastases were detected in 13/142 patients (9.1%), of whom 5 (3.5%) had multiple metastases.

Survival and disease control

The 5-year OS, DSS, DFS, LRC, and LC were 78.7%, 90.4%, 69.1%, 73.8% and 80.6%, respectively (Fig. 1). At last follow-up, a total of 24 patients had died, of whom 12 had died from the cancer under study.

Chart data stratification

Locally intermediate/advanced laryngeal carcinomas differ greatly in surgical indications and prognosis. The analyses were hence conducted on the basis of pathological staging to obtain homogeneous prognostic data. By stratifying the chart data, we evaluated whether pT, previous treatment, or age could affect the DSS, DFS, or LRC end points in terms of prevalence (Fig. 2).

We found that none of the factors affected DSS at 5 years. Indeed, the 5-year DSS of pT2 tumours was 95.2%, while those of pT3 and pT4a SCC were 91.1 and 88.1%, respectively. Similarly, the 5-year DSS of previously-treated patients was very comparable to that of untreated patients (91.2 and 90.5%, respectively). Finally, slight differences in DSS outcome, although not statistically significant, were found between older and younger patients (88.2 and 91.2%, respectively).

DFS and LRC prevalence at 5 years were greatly affected by local staging. Despite pT2 and pT3 carcinomas displaying comparable DFS prevalence (76.0 and 86.4%, respectively), the 5-year DFS of pT4a tumours was on-

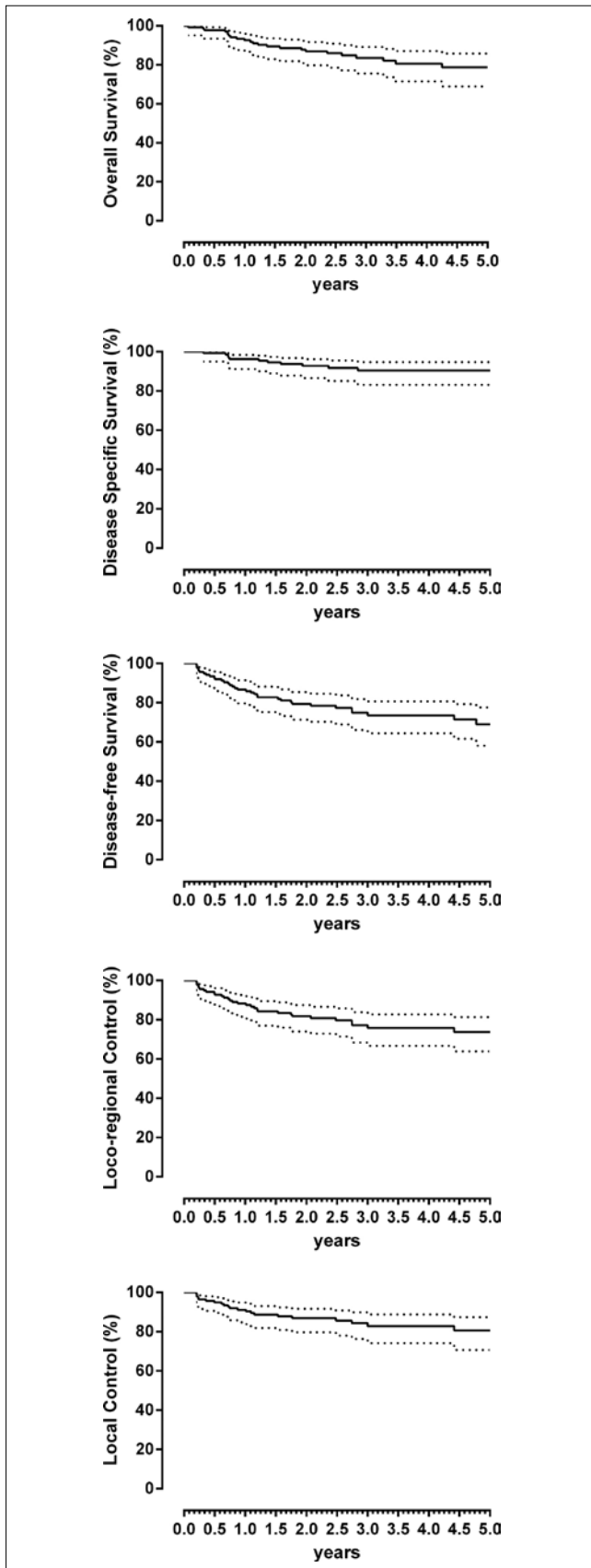


Fig. 1. Overall survival, disease-specific survival, disease-free survival, loco-regional control and local control over a 5-year period in 142 patients with laryngeal cancer staged pT2–pT4a who underwent supratracheal partial laryngectomy.

ly 52.7% ($p < 0.05$); the same pattern was also evident for the LRC endpoint: 76.0% in pT2, 88.7% in pT3, but 64.8% in pT4a patients. Otherwise, the clinical history of previous treatment or age did not affect the 5-year rates of DFS and LRC. In fact, DFS and LRC were 61.0% and 73.2% in pre-treated patients, whereas they were 71.3 and 74.5%, respectively, in patients undergoing OPHL Type III as primary surgery. Similarly, age did not correlate with DFS and LRC: older patients had a prevalence of 67.3% for DFS and 72.3% for LRC, while younger ones had a prevalence of 70.6 and 74.7%, respectively. Finally, in terms of incidence, the overall analyses of the endpoints considered are reported in Table I.

Patterns of failure

Loco-regional recurrences affected 30 patients within 5 years from surgery. According to the site of pathology, they were sub-grouped as 21 local (70.0%) and 9 regional (30.0%) recurrences. Local recurrences were observed in 13 (13.8%) untreated and 8 (16.7%) pre-treated patients. Among these, 3 had subglottic extension and inclusion of a cricoarytenoid joint, 1 had surface extension as far as the inferior edge of the cricoid ring, 14 had extralaryngeal extension (9 anterior, 5 posterior) and 3 showed surface extension toward the posterior commissure. Inside the larynx, the typical subsites of local failure were the mucosa at the passage between the remnant larynx and trachea, the mucosa at the level of the posterior commissure and the contralateral CAU as well as outside the larynx at the level of the outer surface of the remnant larynx (probably one of these options: in transit metastasis, lymph node metastasis at the level of Berry's ligament, direct invasion of the thyroid gland). The most frequent site of close margins was the posterior commissure mucosa. In all patients with local recurrence, salvage therapy included total laryngectomy and adjuvant radiation therapy and/or chemotherapy in 17 patients, and laser surgery in four cases. One patient was lost to follow-up, seven patients died of laryngeal cancer from progression of disease

Table I. Incidence of disease-specific survival (DSS), disease-free survival (DFS) and loco-regional control (LRC) in terms of local staging, previous treatment and age.

	Patients	DSS	DFS	LRC
pT				
pT2	22/142	21/22 (95.5%)	17/22 (77.3%)	17/22 (77.3%)
pT3	58/142	54/58 (93.1%)	51/58 (87.9%)	52/58 (89.7%)
pT4a	62/142	56/62 (90.3%)	40/62 (64.5%)*	43/62 (69.4%)*
Previous treatment				
Untreated	94/142	87/94 (92.6%)	72/94 (76.6%)	75/94 (79.8%)
Treated	48/142	44/48 (91.7%)	36/48 (75.0%)	37/48 (77.1%)
Age (years)				
< 65	97/142	90/97 (92.8%)	76/97 (78.4%)	78/97 (80.4%)
≥ 65	45/142	41/45 (91.1%)	32/45 (71.1%)	34/45 (75.6%)

χ^2 -test; * $p < 0.05$.

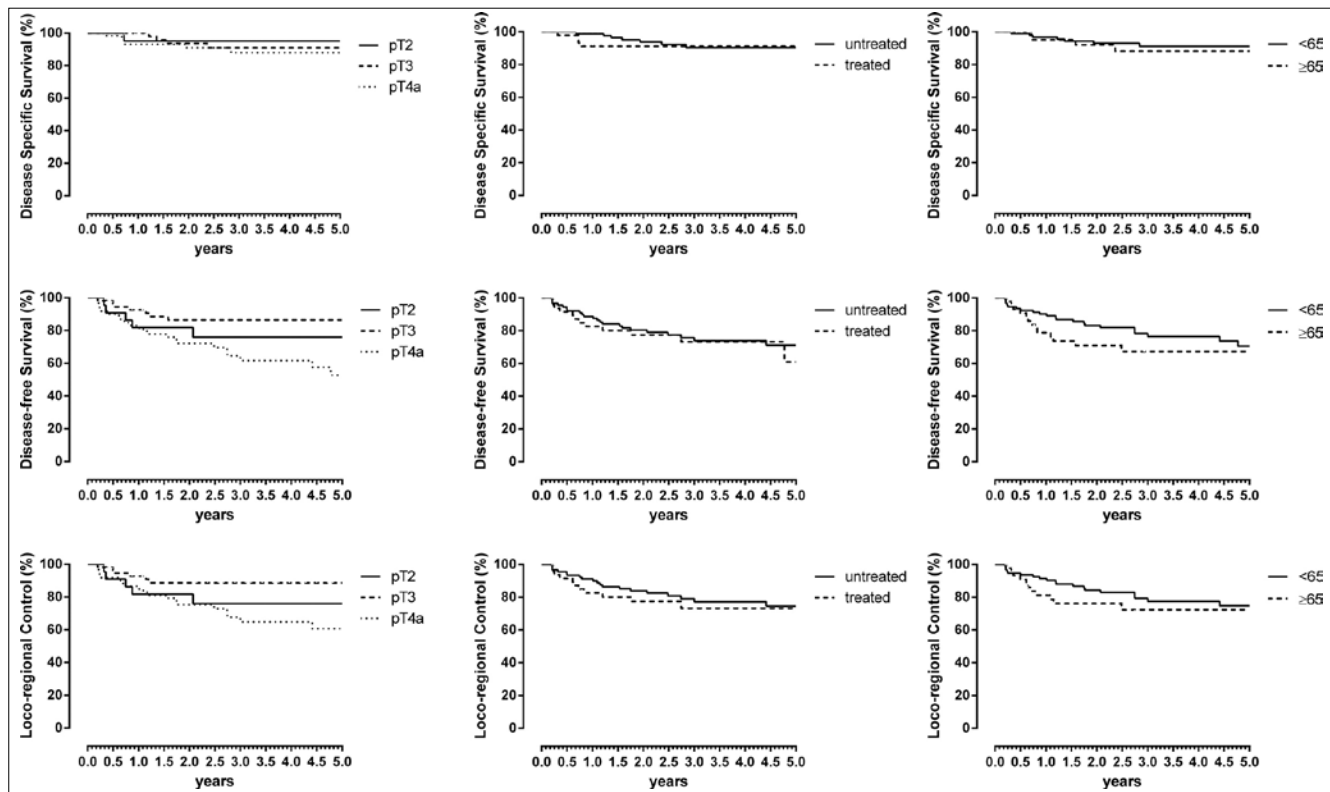


Fig. 2. Disease-specific survival, disease-free survival and loco-regional control in terms of local staging, previous treatment and age over a 5-year period in 142 patients with laryngeal cancer staged pT2–pT4a who underwent supracric partial laryngectomy.

(average 14.0 months, range 7.4–34.1 months) and three patients died of other disease, while at the last follow-up, three patients were alive with disease and seven patients were alive and disease-free; overall local control after salvage therapy was achieved in 7 of 21 patients (33.3%), and at 3 years the local control rate was 66.6%.

Recurrence in the neck was observed in nine cases, five of whom were previously classified as cN0 and four as cN > 0 patients. At the time of primary resection, five of these nine received bilateral neck dissection, and six of nine recurrences were observed at level VI. Five recurrences in the neck were treated with surgery and adjuvant radiation therapy and/or chemotherapy, four recurrences with chemotherapy, one of whom also received radiation therapy; three patients died due to regional recurrences (range 3.8–21.0 months, mean 13.7 months) while at the last follow-up, one patient was alive with disease and five patients were alive and disease-free.

Postoperative course and morbidity

Overall, acute complications during hospitalisation occurred in 10 of 142 patients (7.0%) (Table II) and there were no perioperative deaths. The mean hospitalisation time for patients with acute complications was 37 ± 6 days, which was significantly longer than that for patients without acute complications (25 ± 5 days; $p < 0.001$). Late sequelae following discharge were observed in 40 of 142

cases (28.2%) (Table II). Of these, 37 were successfully treated with transoral CO₂ laser surgery (33/37, 89.2%), injective laryngoplasty using Vox-implants, which successfully treated dysphagia (3/37, 8.1%), or total laryngectomy (1/37, 2.7%).

Laryngeal function preservation

In our patient cohort, the 5-year LFS and LFP were 85.4% and 75.0%, respectively. Furthermore, we evaluated whether LFP could be affected by local staging, presence of previous treatment, or age ≥ 65 years (Fig. 3). Patients affected by advanced pT stage or characterised by older age were more prone to lose laryngeal function than those with intermediate pT stage or younger patients ($p < 0.05$

Table II. Acute postoperative complications and late sequelae.

	Patients (%)
Acute complications	
Cervical bleeding	1/142 (0.7%)
Wound infection	2/142 (1.4%)
Aspiration pneumonia	5/142 (3.5%)
Other	2/142 (1.4%)
Late sequelae	
Laryngeal soft tissue stenosis	25/142 (17.6%)
Dyspnoea	3/142 (2.1%)
Aspiration pneumonia	12/142 (8.5%)

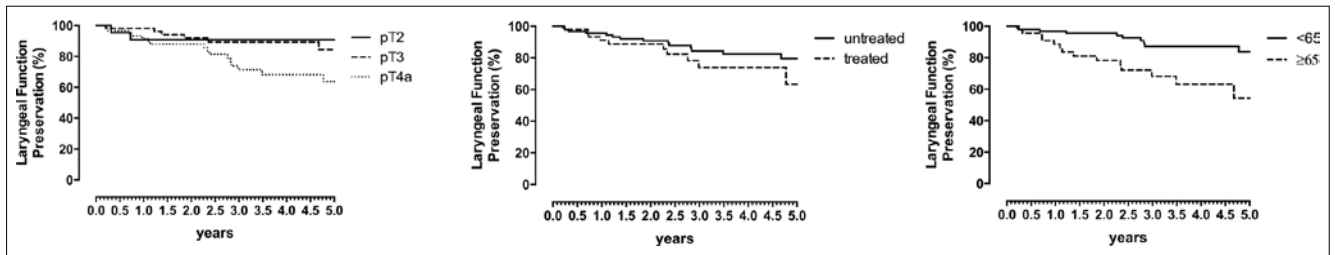


Fig. 3. Laryngeal function preservation in terms of local staging, previous treatment and age over a 5-year period in 142 patients with laryngeal cancer staged pT2–pT4a who underwent supratracheal partial laryngectomy.

and $p < 0.01$, respectively). In fact, functionality was maintained in 90.9% of pT2 and in 84.4% of pT3 patients, but in only 63.7% of pT4a patients. Similarly, laryngeal function was maintained in 83.8% of younger patients compared to 54.2% of the elderly, a difference that can be considered to be an early event, which was also significant with the Gehan Breslow Wilcoxon test ($p < 0.01$). Finally, LFP was not biased by previous treatments (not shown).

Overall, aspiration pneumonia (AP) was observed in 14/142 patients (9.9%), five cases during hospitalisation and 12 cases during follow-up (Table II). Due to intense dysphagia and AP episodes, a temporary gastrostomy was required in 10 patients (7.0%); for six of these, it was removed within the first postoperative year. The gastrostomy was maintained in only four cases due to repeated episodes of AP and severe dysphagia for liquids. In two cases, total laryngectomy was proposed for persistent aspiration: one patient accepted this treatment while the second refused, preferring to keep the gastrostomy and maintain voice. The other two patients were subjected to the endoscopic procedure of injective laryngoplasty using a Vox implant, which successfully resolved the dysphagia, allowing gastrostomy removal.

Discussion

The basic goal of a partial intervention on the larynx is to obtain loco-regional control of the disease, sparing laryngeal functions^{18–20}. To this end, surgery offers either transoral excision of the neoplasm, usually by carbon dioxide laser²¹, or open neck partial, “functional” laryngectomies^{22,23}, the greater part of which, especially in Europe, is represented by open horizontal partial laryngectomies (OPHL). Literature addressing this topic is rich, and a number of surgical procedures have been described to cope with the different patterns of endolaryngeal tumour site and spread^{8,22–25}. Schematically, among the currently available surgical options, total laryngectomy (TL)²⁶ and OPHL Type II²⁷ are the more established solutions for intermediate-advanced stage laryngeal tumours affecting the glottis. However, in an attempt to tailor therapeutic choice to a number of variables related to the tumour and the patient, a significant number of lesions are not amena-

ble to be treated safely by OPHL Type II: (i) glottic/transglottic tumours with subglottic extension when the lesion reaches the cricoid (anteriorly, the cricoid ring is about 15 mm from the glottis while posteriorly, the cricoid plate is about 5–8 mm from the vocal folds); (ii) glottic/transglottic T4a because of extralaryngeal progression through the caudal end of the thyroid cartilage and/or through the cricothyroid membrane.

In this study, we considered 142 patients affected by II–IV staged laryngeal SCC undergoing OPHL Type III, which allows safer resection of subglottic extended lesions^{8,9}. Because of their superficial involvement of the cricoid, glottic-subglottic pT2 are characterised by normal or impaired vocal cord mobility. The latter can be advantageously treated by a CO₂ laser resection²¹, or by OPHL Type II²³, by removing the mucosa from the cricoid cartilage. In both cases, the deep margin could be close, but is often safe. Conversely, despite the fact that OPHL Type III might seem an overtreatment due to the resection of the corresponding part of the cricoid, we must remember that posterior subglottic lesions are difficult to manage with any surgical solution. In the absence of cartilage involvement, non-surgical treatment should always be taken into serious consideration^{28,29}.

The glottic/transglottic pT3 category with subglottic extension represents the actual core group for OPHL Type III. The clinical feature most often characterising these tumours is vocal cord and arytenoid fixation with cricoarytenoid joint and cricothyroid space involvement, combined with arytenoid and/or cricoid sclerosis. The choice of an OPHL Type II procedure would result in a greater risk of positive margins. The introduction of OPHL Type III has opened a useful window into function sparing surgical protocols. In fact, open neck partial surgery can now be conducted using the principles of a modular approach. This states that the resection is always prepared in standard mode and the larynx is opened from the side less affected by disease. Sub-sites involved are removed and the resection can be easily enlarged as follows: OPHL Type II +ARY → OPHL Type III +CAU, OPHL Type IIIa/b → OPHL Type IIIa/b +CAU, OPHL Type III/a → OPHL Type III/b. Resection margins must be examined with frozen sections: if positive, the resection can be ex-

panded until free margins are achieved. The systematic application of whole organ sections represents the quality control for both the surgical procedure and imaging accuracy. It demonstrates that the more extirpative OPHL Type III is mandatory for cancers affecting the cricothyroid space and reaching the upper limit of the cricoid. In these cases, an OPHL Type II would almost certainly result in a positive margin along the upper border of the cricoid. In the present study for pT3, the 5-year OS and DSS were 85.3 and 91.1%, respectively, which are better than what was previously reported for both concomitant chemoradiotherapy or induction chemotherapy and radiotherapy (~60%)^{26,29}.

More advanced pT4a tumours require a series of considerations: first, it must be noted that, in all of the cases in the present cohort, the extralaryngeal extent was minimal. The second is the widespread agreement that total laryngectomy would be the elective intervention for a tumour with extralaryngeal spread, which occurs almost always through invasion of the laryngeal framework. OPHL Type III results have demonstrated that a careful selection can make a good number of patients eligible, even in a few very well selected "extreme cases". Treating anterior cT4a tumours (full-thickness involvement of the thyroid lamina and/or minimal extralaryngeal extension) by OPHL requires an absolutely comparable radicality to that resulting from total laryngectomy. At the end of the work-up, the surgeon must be able, as much as possible, to ensure safe margins thus avoiding an upfront total laryngectomy. As the elective indication in these cases is extirpative surgery, patients should be driven by a strong desire to avoid total laryngectomy and must be informed in advance. Adopting these selection criteria in pT4a cases, OPHL Type III displayed 5-year OS and DSS of 73.2 and 88.1%, respectively, which are in line with those achievable with total laryngectomy. However, the DFS for pT4a cancer (52.7%) was significantly lower than that for pT3 cases (86.4%), but higher in comparison to what was obtained by radiotherapy and/or chemoradiotherapy management (26 to 38%)^{26,29}. On the other hand, the absence of major comorbidities and the ability to undergo a rigorous post-operative rehabilitation represent general prerequisites for all partial laryngectomies.

More attention should be given to local contraindications related to disease extension. OPHL Type III is not able to give a sufficient radicality in: (i) lesions arising from the epilarynx (junction zone between the supraglottic larynx and the other regions); (ii) lesions with major invasion of the preepiglottic space involving the hyoid bone, the interarytenoid space, the posterior commissure and both arytenoid cartilages; (iii) large extralaryngeal spread of cancer; and (iv) lesions reaching the first tracheal ring.

Larynx function preservation has substantial advantages in tailoring surgery to the actual extent of the tumour. Its maintenance was more critical in patients affected by pT4a

cancer (63.7%) and in those older than 65 years (54.2%). Persistent slight dysphagia and aspiration pneumonia still represent major complications in patients undergoing OPHLs^{20,25,30-31}, while voice was significantly deteriorated, and generally quite hoarse and breathy⁹. Fortunately, these phenomena are infrequent, tend to be easily controlled and are well tolerated by patients.

In cases indicated for a more extreme OPHL Type III, ethical considerations can arise. In fact, these cases are considered "amenable with total laryngectomy" and therefore, upfront directed to non-surgical treatment to spare the larynx. The patient must be clearly informed that if the resection margins are positive from frozen sections, the intervention will be converted to a total laryngectomy, thus "jumping" the option of concomitant chemoradiotherapy (recommendation IA in the current guidelines). For these reasons, both the severity of the intervention and the necessity for adjuvant radiotherapy demand that extreme caution must be taken in considering the indications.

In conclusion, we summarise the precise indications and contraindications for OPHL Type III (see OPHL Handbook in the Appendix 1). Furthermore, we demonstrate that the choice of a modular OPHL Type III approach can be considered viable in comparison to chemoradiation protocols for some well-studied glottic and/or transglottic tumours with sub-glottic extension. Advantages can be obtained in terms of prognosis (better identification of upstaging and reduction in prevalence of recurrence) and functional results such as a reduction in the number of total laryngectomies, even at the expense of voice quality and occurrences of sequelae (aspiration pneumonia).

Acknowledgements

Sincere thanks to Professor A.R. Antonelli for valuable suggestions and encouragement to continue research in the field of laryngeal oncology.

References

- Chen AY, Schrag N, Hao Y, et al. *Changes in treatment of advanced laryngeal cancer 1985-2001*. *Otolaryngol Head Neck Surg* 2006;135:831-7.
- The Department of Veterans Affairs Laryngeal Cancer Study Group. *Induction chemotherapy plus radiation compared with surgery plus radiation in patients with advanced laryngeal cancer*. *N Engl J Med* 1991;324:1685-90.
- Forastiere AA, Goepfert H, Maor M, et al. *Concurrent chemotherapy and radiotherapy for organ preservation in advanced laryngeal cancer*. *N Engl J Med* 2003;349:2091-8.
- Serafini I. *Reconstructive laryngectomy*. *Rev Laryngol Otol Rhinol (Bord)* 1972;93:23-38.
- Laccourreye O, Brasnu D, Jouffre V, et al. *Supra-cricoid partial laryngectomy extended to the anterior arch of the cricoid with tracheo-crico-hyoido-epiglottopexy. Oncologic and functional results*. *Ann Otolaryngol Chir Cervicofac* 1996;113:15-9.

- ⁶ Rizzotto G, Succo G, Lucioni M, et al. *Subtotal laryngectomy with tracheohyoidopexy: a possible alternative to total laryngectomy*. *Laryngoscope* 2006;116:1907-17.
- ⁷ Succo G, Peretti G, Piazza C, et al. *Open partial horizontal laryngectomies: a proposal for classification by the working committee on nomenclature of the European Laryngological Society*. *Eur Arch Otorhinolaryngol* 2014;271:2489-96.
- ⁸ Rizzotto G, Crosetti E, Lucioni M et al. *Oncological outcomes of supratracheal laryngectomy: critical analysis*. *Head Neck* 2014 May 16. doi: 10.1002/hed.23773. [Epub ahead of print].
- ⁹ Schindler A, Fantini M, Pizzorni N, et al. *Swallowing, voice and quality of life after supratracheal laryngectomy: preliminary long term results*. *Head Neck* 2015;37:557-66.
- ¹⁰ Rizzotto G, Crosetti E, Lucioni M, et al. *Subtotal laryngectomy: outcomes of 469 patients and proposal of a comprehensive and simplified classification of surgical procedures*. *Eur Arch Otorhinolaryngol* 2012;269:1635-46.
- ¹¹ Damiani V, Crosetti E, Rizzotto G, et al. *Well and intermediate differentiated laryngeal chondrosarcoma: toward conservative surgery?* *Eur Arch Otorhinolaryngol* 2014 Feb;271:337-44.
- ¹² Karnofsky DA, Burchenal JH. *The clinical evaluation of chemotherapeutic agents in cancer*. In: MacLeod CM, editor. *Evaluation of chemotherapeutic agents*. New York: Columbia University Press; 1949. p. 191-205.
- ¹³ Schindler A, Favero E, Capaccio P, et al. *Supracricoid laryngectomy: age influence on long-term functional results*. *Laryngoscope* 2009;119:1218-25.
- ¹⁴ *TNM classification of malignant tumours*. Sixth Edition. New York: Wiley-Liss Editor; 2002.
- ¹⁵ Robbins KT, Clayman G, Levine PA, et al. *Neck dissection classification update: revisions proposed by the American Head and Neck Society and the American Academy of Otolaryngology-Head and Neck Surgery*. *Arch Otolaryngol Head Neck Surg* 2002;128:751-8.
- ¹⁶ Pearson BW. *Subtotal laryngectomy*. *Laryngoscope* 1981;91:1904-12.
- ¹⁷ Bernier J, Domenge C, Ozsahin M, et al. *Postoperative irradiation with or without concomitant chemotherapy for locally advanced head and neck cancer*. *N Engl J Med* 2004;350:1945-52.
- ¹⁸ De Vincentiis M, Minni A, Gallo A, et al. *Supracricoid partial laryngectomies: oncologic and functional results*. *Head Neck* 1998;20:504-6.
- ¹⁹ Mercante G, Grammatica A, Battaglia P, et al. *Supracricoid partial laryngectomy in the management of T3 laryngeal cancer*. *Otolaryngol Head Neck Surg* 2013;149:714-20.
- ²⁰ Crosetti E, Garofalo P, Bosio C, et al. *How the operated larynx ages*. *Acta Otorhinolaryngol Ital* 2014;34:19-28.
- ²¹ Peretti G, Piazza C, Del Bon F, et al. *Function preservation using transoral laser surgery for T2-T3 glottic cancer: oncologic, vocal, and swallowing outcomes*. *Eur Arch Otorhinolaryngol* 2013;270:2275-81.
- ²² Laccourreye O, Brasnu D, Biacabe B, et al. *Neo-adjuvant chemotherapy and supracricoid partial laryngectomy with cricohyoidopexy for advanced endolaryngeal carcinoma classified as T3-T4: 5-year oncologic results*. *Head Neck* 1998;20:595-9.
- ²³ Di Nicola V, Fiorella ML, Spinelli DA, et al. *Acoustic analysis of voice in patients treated by reconstructive subtotal laryngectomy. Evaluation and critical review*. *Acta Otorhinolaryngol Ital* 2006;26:59-68.
- ²⁴ Lima RA, Freitas EQ, Dias FL, et al. *Supracricoid laryngectomy with cricohyoidopiglottopexy for advanced glottic cancer*. *Head Neck* 2006;28:481-6.
- ²⁵ Benito J, Holsinger FC, Perez-Martin A, et al. *Aspiration after supracricoid partial laryngectomy: Incidence, risk factors, management, and outcomes*. *Head Neck* 2011;33:679-85.
- ²⁶ Wolf G. *Reexamining the treatment of advanced laryngeal cancer: the VA laryngeal cancer study revisited*. *Head Neck* 2010;32:7-14.
- ²⁷ Pinar E, Imre A, Calli C, et al. *Supracricoid partial laryngectomy: Analysis of oncologic and functional outcomes*. *Otolaryngol Head Neck Surg* 2012;147:1093-8.
- ²⁸ Ruberto M, Alicandri-Ciuffelli M, Grammatica A, et al. *Partial laryngectomies: when the problem is the pexy*. *Acta Otorhinolaryngol Ital* 2014;34:247-52.
- ²⁹ Forastiere AA, Zhang Q, Weber RS, et al. *Long-term results of RTOG 91-11: a comparison of three nonsurgical treatment strategies to preserve the larynx in patients with locally advanced larynx cancer*. *J Clin Oncol* 2013;31:845-52.
- ³⁰ de Virgilio A, Greco A, de Vincentiis M. *The role of cricohyoidopiglottopexy in the era of transoral laser surgery and radio/chemotherapy*. *Acta Otorhinolaryngol Ital* 2014;34:209.
- ³¹ Ricci Maccarini A, Stacchini M, Salsi D et al. *Surgical rehabilitation of dysphagia after partial laryngectomy*. *Acta Otorhinolaryngol Ital* 2007;27:294-8.

Received: March 3, 2015 - Accepted: March 16, 2015

Appendix 1

Type III OPHL Handbook

Local indications

As definitions for the Type III (a+b) OPHLs have only recently been introduced, the precise T classification related indications and contraindications are separately reported:

- *Glottic T2 with subglottic extension*

The OPHL Type III option has been considered for tumours with anterior or lateral subglottic extension, spreading above the conus elasticus and reaching the cricoid. In all these cases, vocal cord mobility has been normal or impaired, while arytenoid mobility has always been normal. As a rule, the lesion has shown a superficial subglottic extension, more than 10 mm anteriorly and about 5–8 mm posteriorly.

The CT scan shows a glottic lesion extending downward, apparently without involvement of the cricothyroid space and/or extension through the cricothyroid membrane, and which reaches the cricoid plate posteriorly and/or the cricoid ring anteriorly. There is no evidence of direct involvement of the laryngeal framework although it is possible to highlight sclerosis of the arytenoid or the cricoid cartilage, indirect signs of the lesion reaching the cartilage perichondrium (Fig. S1 a-c).

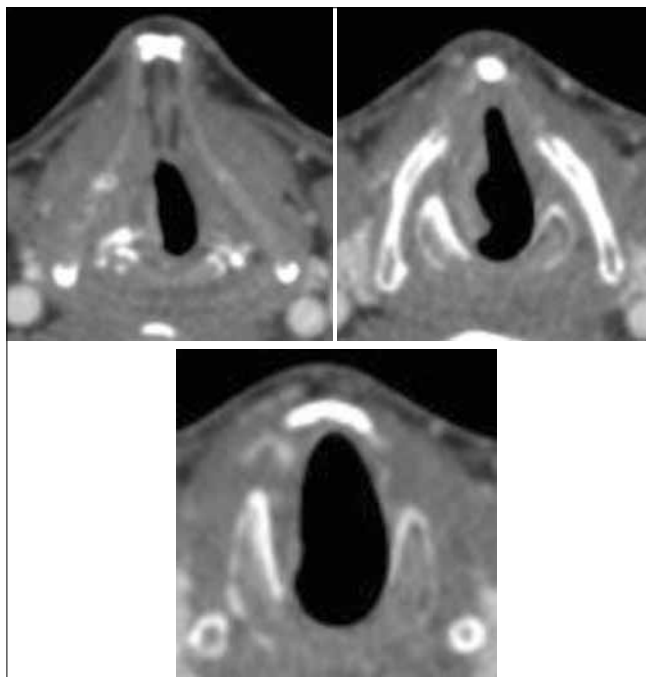


Fig. S1. a-b) CT scan in axial view of right recurrent glottic T2 with impaired mobility of the vocal cord, extending superficially to the subglottic site along the elastic cone toward the cricoid cartilage. c) The tumour reaches the cricoid plate and ring.

- *Glottic/transglottic T3 with subglottic extension*

This category is extremely heterogeneous and the majority of lesions are manageable with an OPHL Type II (supracricoid laryngectomy). In these cases, the most evident clinical feature is the fixed vocal cord with mobile arytenoid, a sign of no invasion of the cricoarytenoid joint.

OPHL type III was essentially adopted in two situations:

A. glottic-subglottic T3 tumours spreading within the paraglottic space and controlled by the conus elasticus medially and the perichondrium of the thyroid cartilage laterally (Fig. S2 a-d) (tumour growth is directed downward and laterally; sometimes it can infiltrate the inferior edge of the thyroid cartilage or exit the larynx between the thyroid and cricoid cartilages through the cricoarytenoid membrane: the so-called early glottic pT4a) (Fig. S3 a-c). Surface extension toward the posterior commissure can be observed. Typical clinical features are the fixed vocal cord, fixed arytenoid and subglottic swelling.

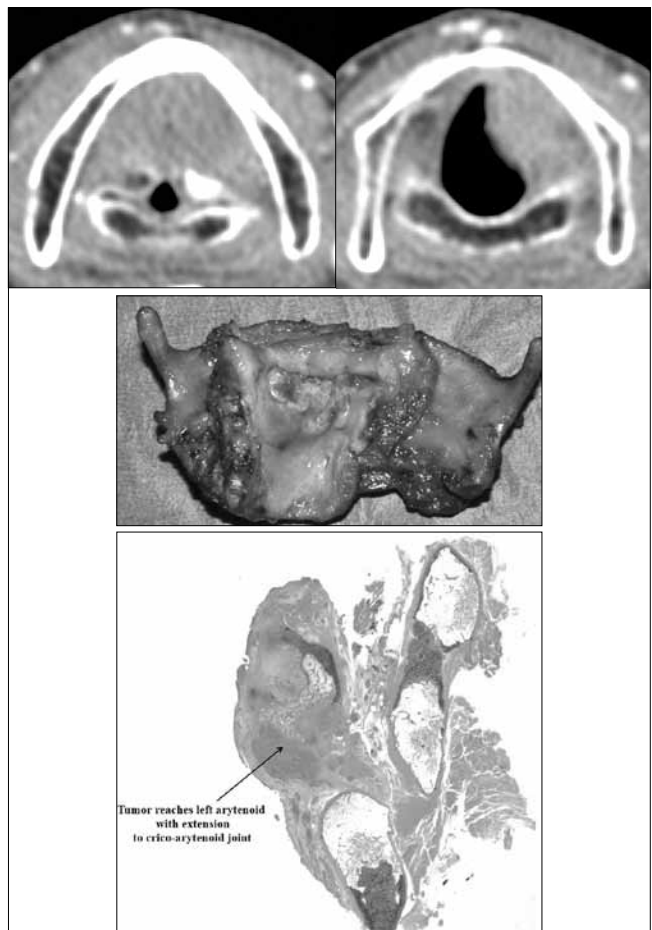


Fig. S2. a-b) CT scan in axial view of left glottic T3 with fixed vocal cord and hypomobile arytenoid, extending downward and laterally within inferior paraglottic space. Note the intense sclerosis of the arytenoid without evidence of direct invasion of the cricoid. c) The specimen of OPHL type III + left CAU. d) Macrosection of the same specimen: the lesion reaches the crico-arytenoid joint (arrow).

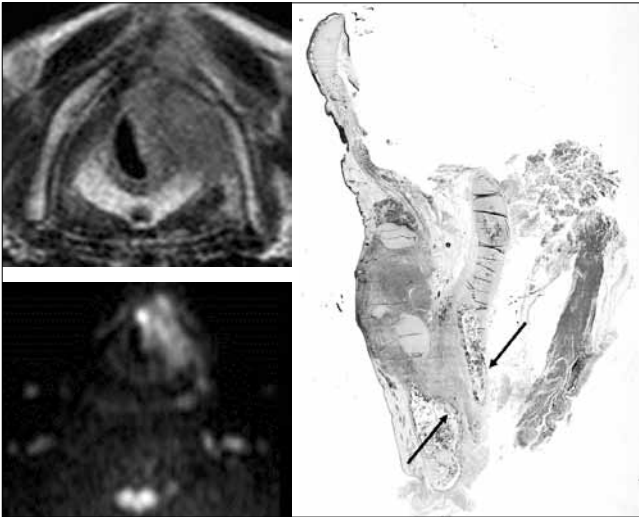


Fig. S3. a-b) MRI in axial view of left glottic T3 with fixed vocal cord and arytenoid, extending downward and laterally reaching the crico-thyroid space. Note the intense sclerosis of the cricoid with suspect involvement of thyroid cartilage. c) Macro-section on the specimen of OPHL type III + left CAU: the lesion involves the cricothyroid space, the inferior edge of the thyroid cartilage and superior edge of the cricoid (arrows).

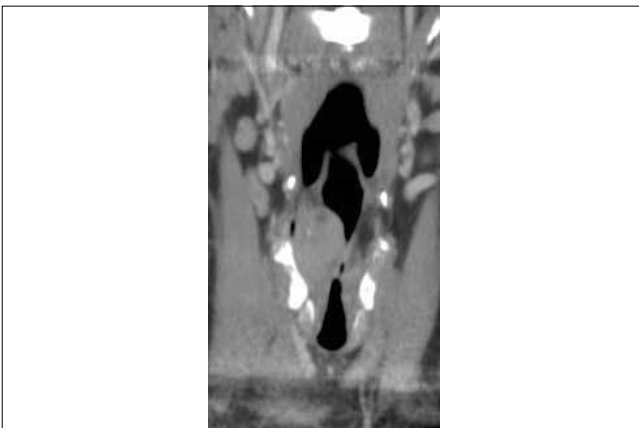

Fig. S4. CT scan in coronal view of right transglottic T3 with fixed vocal cord and arytenoid. The tumour clearly invades the superior and inferior paraglottic space with transglottic extension toward the cricoid cartilage.

B. transglottic T3 tumours spreading superiorly into the deep tissue of the ventricular band under the quadrangular membrane and progressing into the subglottic area, where they reach the internal lamina and the inferior edge of the thyroid cartilage or the superior edge of the cricoid (Fig. S4). Also in these cases, both the vocal cord and arytenoid can be fixed.

- *T4a with limited anterior or lateral extralaryngeal extension*

Gross extralaryngeal spread of cancer represents a clear contraindication to any type of partial laryngectomy. However, OPHL type III has been advantageously adopted in

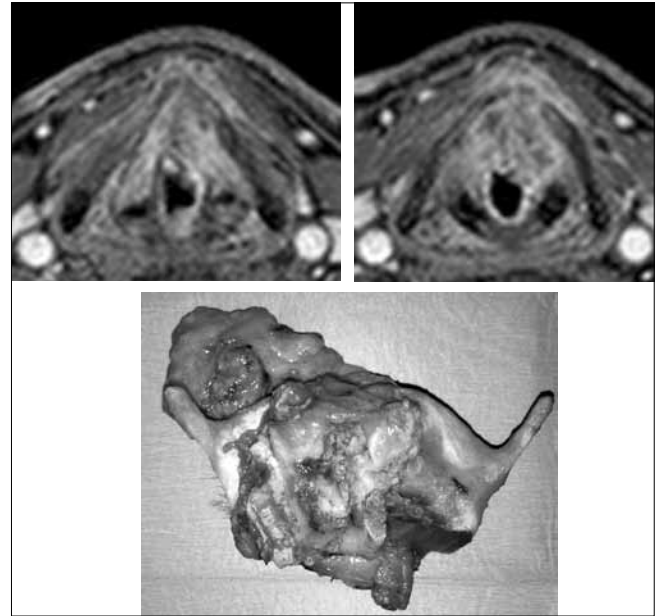


Fig. S5. a) MRI in axial view of left glottic T4a with fixed vocal cord and arytenoid, extending downward and laterally within inferior paraglottic space. Note the involvement of the arytenoid and the crico-arytenoid joint without evidence of direct invasion of the cricoid. b) Anterior extralaryngeal spread through the thyroid cartilage. c) The specimen of OPHL type III + left CAU.

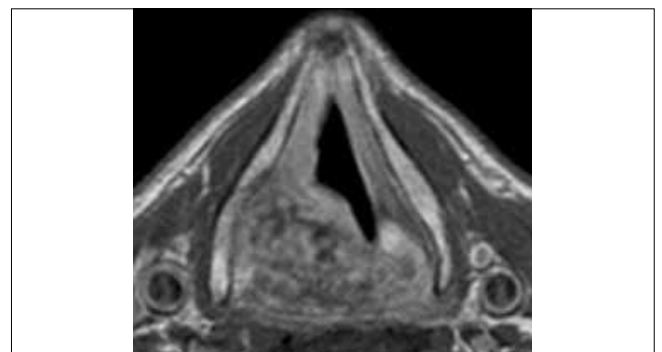


Fig. S6. MRI in axial view of right intermediated grade larynx chondrosarcomas without involvement of the whole cricoid plate.

clinically T3 tumours but strongly suspected of having an initial extralaryngeal extension through the laryngeal framework or cricothyroid space/membrane (Fig. S5 a-c). In these cases, because of the suspicion of extralaryngeal extension, the radicality provided would be comparable to that of total laryngectomy.

Other indications

OPHL Type III was also successfully adopted for radical resection of low-intermediate grade laryngeal chondrosarcomas without involvement of the whole cricoid plate¹¹ (Fig. S6) and in a case of recurrent papillary thyroid carcinoma with thyroid cartilage involvement and intralaryngeal spread (Fig. S7 a-b).

Contraindications

With respect to the local extent of the tumour, our absolute contraindications were as follows:

- supraglottic T4a tumours reaching the base of the tongue or invading the hyoid bone (Fig. S8 a-b);
- glottic-subglottic T3 tumours with massive invasion of the paraglottic space reaching the posterior cricoarytenoid muscle and the pyriform sinus submucosa (Fig. S9);
- gross glottic-subglottic T4a with massive cricoid invasion (Fig. S10) or reaching the first tracheal ring (Fig. S11);
- lymph nodes staged N3.

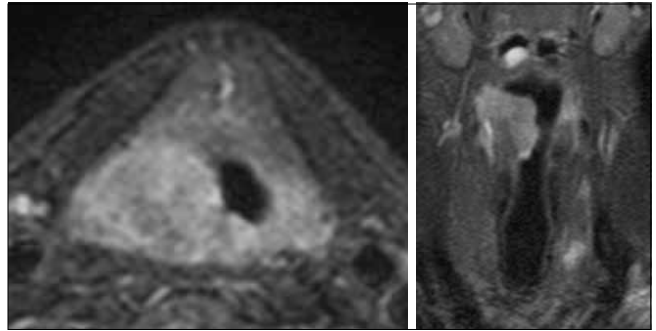


Fig. S9. a-b) MRI in axial and coronal view of right glottic T3 with fixed vocal cord and arytenoid, extending posteriorly to the pyriform sinus submucosa and reaching the posterior commissure and posterior crico-arytenoid muscles.

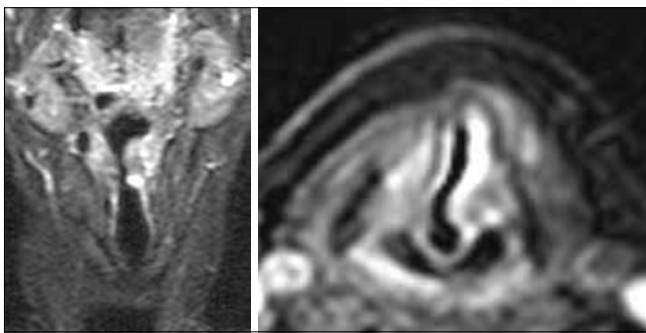


Fig. S7. a-b) MRI in coronal and axial view of recurrent papillary thyroid carcinoma with thyroid cartilage involvement and intralaryngeal spread.

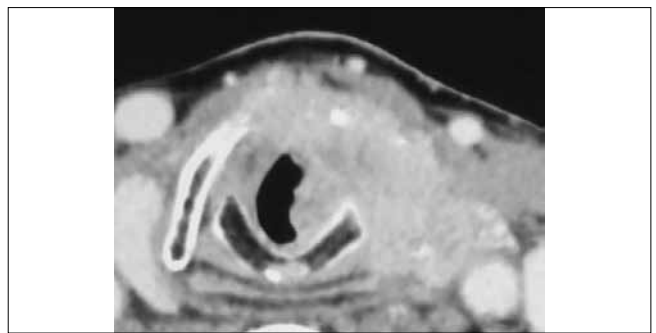


Fig. S10. CT scan of large glottic-subglottic T4a with massive cricoid invasion and extralaryngeal spread.

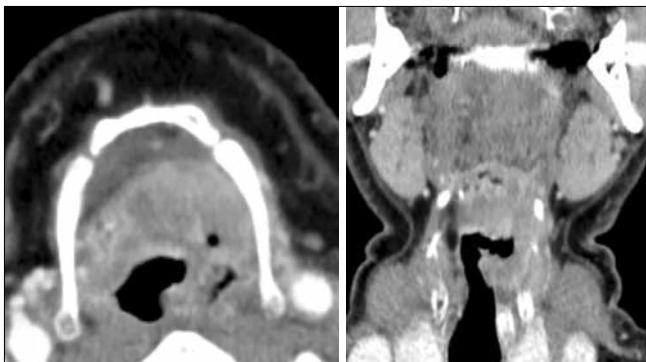


Fig. S8. a-b) CT scan of supraglottic T4a tumors reaching the base of the tongue and involving the hyoid bone. a) Axial view. b) Coronal view.

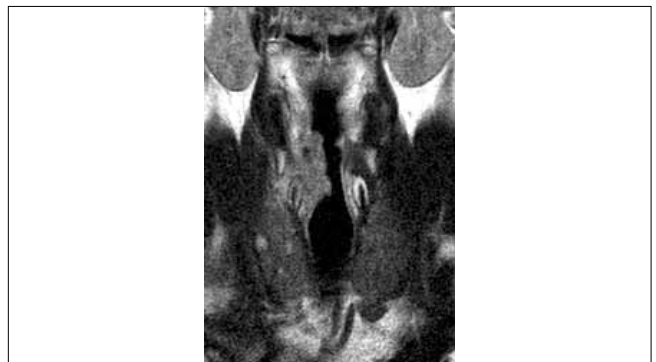

Fig. S11. CT scan of glottic-subglottic T4a reaching the first tracheal ring and with extralaryngeal spread.

HEAD AND NECK

A novel approach emphasising intra-operative superficial margin enhancement of head-neck tumours with narrow-band imaging in transoral robotic surgery

Un innovativo approccio intra-operatorio alla definizione dei margini superficiali nei tumori del testa-collo con l'uso della narrow-band imaging nella chirurgia robotica transorale

C. VICINI, F. MONTEVECCHI, G. D'AGOSTINO, A. DE VITO, G. MECCARIELLO

ENT, Head-Neck Surgery and Oral Surgery Unit, Department of Special Surgery, Morgagni Pierantoni Hospital, Forlì, Italy

SUMMARY

The primary goal of surgical oncology is to obtain a tumour resection with disease-free margins. Transoral robotic surgery (TORS) for surgical treatment of head-neck cancer is commensurate with standard treatments. However, the likelihood of positive margins after TORS is up to 20.2% in a recent US survey. The aim of this study is to evaluate the efficacy and the feasibility of narrow-band imaging (NBI) during TORS in order to improve the ability to achieve disease-free margins during tumour excision. The present study was conducted at the ENT, Head-Neck Surgery and Oral Surgery Unit, Department of Special Surgery, Morgagni Pierantoni Hospital, Azienda USL Romagna. From March 2008 to January 2015, 333 TORS were carried out for malignant and benign diseases. For the present study, we retrospectively evaluated 58 biopsy-proven squamous cell carcinoma patients who underwent TORS procedures. Patients were divided into 2 groups: (1) 32 who underwent TORS and intra-operative NBI evaluation (NBI-TORS); (2) 21 who underwent TORS with standard intra-operative white-light imaging (WLI-TORS). Frozen section analysis of margins on surgical specimens showed a higher rate of negative superficial lateral margins in the NBI-TORS group compared with the WLI-TORS group (87.9% vs. 57.9%, respectively, $p = 0.02$). The sensitivity and specificity of intra-operative use of NBI, respectively, were 72.5% and 66.7% with a negative predictive value of 87.9%. Tumour margin enhancement provided by NBI associated with magnification and 3-dimensional view of the surgical field might increase the capability to achieve an oncologically-safe resection in challenging anatomical areas where minimal curative resection is strongly recommended for function preservation.

KEY WORDS: Robotic surgical procedures • Narrow band imaging • Frozen section • Optical imaging • Minimally invasive surgery

RIASSUNTO

Il principio fondamentale della chirurgia oncologica è ottenere una exeresi della massa tumorale con margini di resezione liberi da malattia. Tuttavia nel corso degli anni sono state messe a punto tecniche mini invasive, quali la chirurgia robotica trans orale (TORS), che permettono di ottenere risultati comparabili alle tecniche tradizionali in termini di controllo loco-regionale della malattia e sopravvivenza. D'altronde, l'approccio chirurgico robotico prevede una resezione minimale e sufficiente della lesione tumorale al fine di ottenere una exeresi che non comporti una eccessiva demolizione dei tessuti non coinvolti dalla patologia in modo da ridurre le sequele funzionali. Il punto chiave del concetto di chirurgia mini-invasiva è la capacità di localizzare in maniera appropriata il piano di resezione al fine di minimizzare l'asportazione di tessuto normale ma allo stesso tempo di consentire un buon controllo sui margini ai fini di prevenzione della recidiva locale. Lo scopo dello studio è di analizzare se l'uso della narrow-band imaging (NBI) nella valutazione intra-operatoria dei margini superficiali di resezione possa permettere un maggior successo in termini di margini liberi da malattia durante la chirurgia robotica trans orale per tumori faringei e laringei. Nel periodo compreso da marzo 2008 e gennaio 2015, presso l'UO di Otorinolaringoiatria e Chirurgia Cervico-Facciale, Servizio di Stomatologia e Chirurgia Orale (Dipartimento di Chirurgie Specialistiche) dell'Ospedale Morgagni-Pierantoni di Forlì (AUSL della Romagna) sono state eseguite 333 procedure TORS sia per patologia benigna che maligna. In tale casistica 61 pazienti sono stati trattati con TORS per diagnosi istologica di malignità. Il carcinoma squamocellulare rappresenta l'entità istopatologica più frequente (95,1%); solo un paziente (1,6%) presentava un adenocarcinoma di tipo salivare della base lingua mentre due pazienti (3,3%) soffrivano di melanoma mucoso della tonsilla palatina. Tuttavia sono stati valutati nello studio solo 58 pazienti con carcinoma squamocellulare. I pazienti, quindi, sono stati divisi in due gruppi: 1) 37 soggetti sottoposti a TORS con valutazione intraoperatoria con l'uso di NBI; 2) 21 soggetti sottoposti a TORS valutati con luce bianca standard. L'analisi istopatologica al congelatore dei margini superficiali sul pezzo operatorio ha dimostrato una alta percentuale di negatività nelle resezioni assistite da NBI rispetto alle resezioni valutate con metodica standard (87,9% vs. 57,9%, rispettivamente, $p = 0,02$). La sensibilità e la specificità della NBI nel suo uso intraoperatorio raggiunge rispettivamente il 72,5% e il 66,7% con valore predittivo negativo pari al 87,9%. Concludendo l'uso della NBI durante le resezioni TORS per malignità consente di aumentare potenzialmente il successo di una resezione con margini liberi da malattia limitando la distruzione dei tessuti non coinvolti da tumore.

PAROLE CHIAVE: Procedure di chirurgia robotica • Narrow band imaging • Esame intraoperatorio • Tecnica di definizione ottica • Chirurgia mini-invasiva

Introduction

The primary goal of surgical tumour removal is to obtain disease-free margins. The advent of transoral robotic surgery (TORS), using the daVinci® Surgical System (Intuitive Surgical, Sunnyvale, CA), allows for a three-dimensional view with magnification and increased freedom of mobility of surgical instruments (cautery/laser and Maryland forceps) in the surgical management of pharyngeal and laryngeal tumours. These advantages, besides avoiding mandibular splitting or neck incision, also improve surgical excision in terms of tumour-free margins, and whenever possible to spare important functional structures. In a recent US national survey, the likelihood of positive margins after TORS for oropharyngeal cancers was reported to be 20.2%¹. On the other hand, narrow band imaging (NBI) has been shown to be a useful additional tool for the early detection of small superficial cancers in the oropharynx, hypopharynx and larynx^{2,3}. This technique has also enabled the lateral spread of oropharyngeal, hypopharyngeal and laryngeal tumours to be visualised, allowing an accurate evaluation of lesion extension, which is essential for the best planning of the surgical margins⁴. In our study, we used NBI combined with TORS to examine the superficial spread of head-neck cancers during surgery to enhance tumour resection with disease-free margins. The main aim is to evaluate the feasibility and efficacy of NBI during TORS in order to achieve disease-free excision margins.

Materials and methods

The study was conducted in compliance with our Institutional Review Board and Ethics Committee requirements. Between March 2008 and January 2015 at ENT, Head-Neck and Oral Surgery Unit, Department of Special Surgery, Morgagni Pierantoni Hospital, Azienda

USL Romagna, 333 TORS were carried out for malignant and benign diseases (Table I). The study was a prospective non-randomised, single-centre cohort trial. For the present study, we enrolled all patients who underwent TORS procedures for biopsy-proven squamous cell carcinoma (SCC). All cases were presented and discussed at our Head and Neck Multidisciplinary Tumour Board. Informed consent form was obtained by all patients after attending a counselling session on the alternatives to surgery and on the intraoperative use of NBI. We staged tumours in accordance with the American Joint Committee on Cancer staging criteria (AJCC, 7th)⁵. A first group of cases was treated without the use of NBI until the instrumentation was acquired. In 2010, NBI was acquired by our Department and after an in-office training period, was applied intra-operatively to each cancer patient who underwent TORS.

A Fey-Kastenbauer retractor (Gyrus Medical Inc., Maple Grove, MN), Dingman retractor and Crowe Davis retractor were used to expose the operative site. The tumour margins were observed intraoperatively with a 0 or 30° 8 mm Hopkins Scopes (Karl Storz, Germany) by white light imaging (WLI) alone and then with the NBI high-definition video-endoscopy system (CV-260SL processor, CVL-260SL light source, Olympus Optical Co., Ltd., Japan) to evaluate the feasibility of the NBI system for clinical use and its ability to identify abnormal findings. The key point was the enhancement of definition of the lesion's extension and its macroscopic boundaries and maintain from them the margins established. The surgical margins were set at least 1 cm in the oral cavity/oropharynx and at least 2 mm in hypopharynx and larynx. The edges of surgical excision were inked and/or marked with monopolar (in case of difficulties to mark with ink, i.e. supraglottic/hypopharyngeal cancer) and controlled with NBI. When NBI showed a suspicious pattern^{6,7} outside the inked edges, a further

Table I. Forlì ENT Department TransOral Robotic Surgery procedures (May 2008-January 2015).

333 cases:	
Benign diseases	Malignant diseases
199 OSAHS (BOT Reduction+Supraglottoplasty)	21 Tonsil Cancers (Radical Tonsillectomy)
45 Lingual Tonsil Hyperplasia	18 Tongue Base Cancers (Partial BOT resection)
3 Vallecular Fibroma	8 Supraglottic Cancers (Supraglottic laryngectomy)
3 Glottic-Supraglottic Obstruction/Adhesion (Lysis)	5 Lingual Tonsil Lymphomas
2 Velo-Pharyngeal Insufficiency (Veloplasty)	4 Posterior Pharyngeal Wall Cancer (Partial pharyngectomy)
1 Tongue Base Lymphangioma	4 Piriform Sinus Cancer (Partial Pharyngectomy)
1 Palate Pemphigoid Adhesion (Veloplasty)	2 Laryngeal Cancers (Total laryngectomy)
1 Lingual Thyroidectomy	1 Palate Cancer
1 Laryngocele	1 Retromolar Trigone + 1 lingual marginal cancer
1 Piriform Sinus Fistula (closure)	1 Nasopharyngeal Cancer (Nasopharyngectomy)
1 Tongue Base Lymphangioma	1 Glottic Cancer (Cordectomy)
	2 Parapharyngeal Tumours (Liposarcoma, Pleomorphic adenoma)

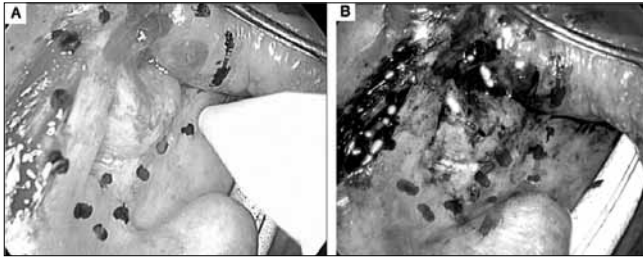


Fig. 1. A) Marking the margins of a squamous cell carcinoma of the left tonsil under white light vision. B) Defining surgical margins with narrow-band imaging (red line showing further extension of the resection line).

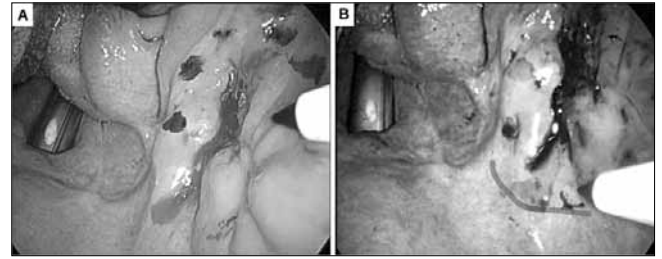


Fig. 2. A) Marking the margins of a squamous cell carcinoma of the right retromolar trigon in white light vision. B) Defining surgical margins with narrow-band imaging (red line showing the further extension of the resection line).

marking was done including that area (Figs. 1, 2). The daVinci® Surgical System surgical robot was positioned 30° angled on the right side of the patient. A 0 or 30° 8.5 mm endoscope was used with two 5-mm side arms Maryland dissectors and cautery. The operating surgeon was seated in the console, while the assistant was seated at the patient’s head. An emergency tracheostomy set and head and neck operative instruments tray were opened and kept on standby in case of airway problems or uncontrolled intra-operative bleeding. Visualised vessels were clipped prior to transaction. All surgical specimens were firstly oriented and then submitted to the pathologist for assessment of the status of margins with frozen sections. Both frozen and definitive surgical specimens were analysed by the head-neck specialised pathologist of our Institution. In case of positive or close or unclear margins by frozen sections, additional resections were carried out until frozen sections were negative for residual malignancy. According to other authors, we stated that clear margin was > 5 mm for oral cavity/pharyngeal tumours and > 1 mm for laryngeal cancers on microscopic evaluation⁷⁹. For the present study, only the first line superficial resection margins were included. Deep margins and secondary or tertiary superficial resection margins were excluded. All robotic procedures were performed as first surgeon by V.C. Neck dissection was either done concurrently during the “dead time” required for the frozen section examination (in case of cN+) or one week before (in case of major vessels close to the tumour showed by imaging) or 4 weeks after TORS (as elective neck dissection). According to our Tumour Board Policy, patients received adjuvant therapy if they had: (1) positive margins at definitive histologic report; (2) extra-capsular spread; (3) lymphovascular invasion; (4) perineural invasion; and/or (5) multiple positive nodes. Associations between variables and endpoints were tested with Fisher exact test or *t* tests, as appropriate. A 2-tailed P value < 0.05 was regarded as statistically significant. Statistical analysis was performed with STATA 12.0 software (Stata Corp., College Station, TX, USA).

Results

A total of 61 patients with head-neck biopsy proven cancers were evaluated. SCC represented the most frequent histologic finding in 58 patients (95.1%); one (1.6%) patient had a salivary adenocarcinoma and 2 (3.3%) patients suffered from mucosal melanoma. According to exclusion criteria, we excluded these cases from the analysis as they had histology different from SCC. Patients were divided into 2 groups: (1) 37 who underwent TORS and intra-operative NBI evaluation (NBI-TORS); (2) 21 who underwent TORS with standard intra-operative WLI (WLI-TORS). Demographic data and tumour staging for each group are summarised in Table II. Frozen section analysis of the margins on the primary surgical specimens showed a high rate of negative superficial lateral margins in the NBI-TORS group compared with the WLI-TORS group

Table II. Demographic data and tumour staging for each group.

	NBI-TORS (n = 37)		WLI-TORS (n = 21)		p
Mean Age ± SD	66.1 ± 9.9		66.3 ± 8.3		
Male:Female	24:13		16:5		
Tumour stage					
cT1	18		9		0.27
cT2	16		8		
cT3	2		4		
cT4	1		-		
pT1	18	14 oropharynx 1 hypopharynx 2 larynx 1 oral cavity	9	8 oropharynx 1 hypopharynx	0.24
pT2	17	14 oropharynx 2 hypopharynx 2 larynx 1 nasopharynx	8	8 oropharynx	
pT3	1	1 larynx	3	3 larynx	
pT4	2	2 larynx	1	1 larynx	

TORS: TransOral Robotic Surgery; NBI: Narrow Band Imaging; WLI: White Light Imaging; SD: Standard Deviation.

(87.9% vs. 57.9%, respectively, $p=0.02$). The sensitivity and specificity of the intra-operative use of NBI, respectively, was 72.5 and 66.7% with a negative predictive value of 87.9%.

Discussion

In recent years, chemo-radiation (CRT) has become standard treatment in the management of most oropharyngeal cancers, and an alternative choice in laryngeal cancers for the preservation of laryngeal function^{10,11}. However, radiotherapy has some adverse effects, such as xerostomia and dysphagia, and can induce late complications, such as trismus, osteoradionecrosis and, not only theoretically, late induced field cancerisation. Accordingly, there is an increasing interest in transoral surgical techniques that reduce operation-related morbidity and improve the patients' quality of life, offering a low morbidity alternative to chemoradiation. Recently, Weinstein et al.¹⁰ reported that the disease control and survival rates as well as the safety of TORS using the daVinci® Surgical System for the surgical treatment of oropharyngeal cancer were comparable to standard treatments. Since then, TORS has become part of the surgical armamentarium in the treatment of malignant and benign diseases¹³. Furthermore, comparable oncologic and functional results with CRT has been shown in several trials¹⁴⁻¹⁶. Nevertheless, the likelihood of positive margins after TORS ranged from 0-12%¹⁵⁻¹⁹, although a recent survey in US reported positive margins up to 20.2% of TORS patients¹. These patients would require further adjuvant treatments such as CRT, which would reduce the basic advantage of TORS. Cooper et al.²⁰ have shown that adjuvant CRT is associated with an increased risk of severe adverse events. On the other hand, the philosophical approach by TORS requires minimal sufficient resection of the lesion in order to clear safely the tumour without excessive removal of normal tissue to obtain a real minimally-invasive resection with less risk of late functional impairments¹². The key point is to be able to properly locate the superficial resection line as close as possible to the lesion to avoid over-resection and far enough to the tumour margins in order to prevent recurrence. However, there is no universal agreement on how much normal tissue should be removed around a tumour to reduce the risk of local recurrence from incomplete resection⁹. Furthermore, the thermal injury delivered to tissue by the monopolar scalpel of the robotic arm might create false positive margins and the pathologist should be aware of this surgical artefact²¹. The rationale of the intra-operative use of additional optical imaging in our TORS setting is to minimise as much as possible surgical resections with a suspicious mucosal pattern close to the main tumour and reduce the rate of positive superficial margins. Concomitantly, in two different case series, Patsias et al.²² showed that the use of high resolution

microendoscopy imaging during TORS for oropharyngeal cancers might provide real time histological assessment of tumour margins, while Tateya et al.²³ evaluated the feasibility and efficacy of NBI in determining the extent of resection during TORS for oropharyngeal cancer. In previous studies, NBI was used to assess the extent of pharyngeal and oesophageal tumours,⁴ and in a preoperative setting to enhance surgical margins in duodenal papilla cancers²⁴. The reported sensitivities and accuracies for the diagnosis of superficial cancer spread in the oropharynx and hypopharynx were 7.7 and 62.9% for WLI, respectively, compared with 100 and 86.7% for NBI, respectively^{4,24}. Our study has shown that the use of the NBI in controlling tumour resection might improve the chance to obtain disease-free margins without excessive removal of normal tissue (unnecessary over-resection). The sensitivity and specificity in defining tumour-free margins was 72.5 and 66.7%, respectively. Of note, the learning curve in TORS might theoretically be a potential bias in reducing the rate of positive margins over time; however, a recent study of 168 head-neck cancers treated with TORS showed no significant reduction in the rate of positive resection margins over other factors such as operative time²⁵. The limits of intra-operative use of this technique are highlighted during TORS sessions: (1) NBI improves visualisation of suspicious cancer patterns only on lateral superficial margins of the lesion resection; (2) the technique may be not be reliable on a surgical field after resection for assessing lateral margins because of the blood blinding the view on the same frequency spectrum; (3) NBI is not suitable to assess deep margins because it was developed to discern a specific mucosal pattern without any information on different tissues. However, in a recent study, preliminary data showed that the use of the NBI with magnifying endoscopy might predict the depth of invasion in laryngo-pharyngeal cancer²⁶. Nevertheless, NBI might be a reliable and safe tool in the surgical framework and does not increase either operative time or costs. On the contrary, a primary resection with tumour-free margins does not impose any time consuming additional resection (surgical and histological times).

Conclusions

The superficial enhancement of tumour margins provided by NBI associated with magnification and 3-dimensional view of the surgical field might increase the ability to achieve an oncologically safe resection in challenging anatomical areas.

Acknowledgements

The authors wish to thank the pathologist Matteo Costantini for his outstanding activity and for actively supporting the Head and Neck Multidisciplinary Tumour Board of our Institution.

References

- 1 Chen MM, Roman SA, Kraus DH et al. *Transoral robotic surgery: a population-level analysis*. *Otolaryngol Head Neck Surg* 2014;150:968-75.
- 2 Muto M, Minashi K, Yano T et al. *Early detection of superficial squamous cell carcinoma in the head and neck region and esophagus by narrow band imaging: a multicenter randomized controlled trial*. *J Clin Oncol* 2010;28:1566-72.
- 3 Katada C, Nakayama M, Tanabe S et al. *Narrow band imaging for detecting metachronous superficial oropharyngeal and hypopharyngeal squamous cell carcinoma after chemoradiotherapy for head and neck cancers*. *Laryngoscope* 2008;118:1787-90.
- 4 Matsuba H, Katada C, Masaki T et al. *Diagnosis of the extent of advanced oropharyngeal and hypopharyngeal cancers by narrow band imaging with magnifying endoscopy*. *Laryngoscope* 2011;121:753-9.
- 5 Edge SB, Byrd DR, Compton CC, et al., editors. *American Joint Committee on Cancer Staging Manual*. 7th ed. New York: Springer; 2009.
- 6 Takano JH, Yakushiji T, Kamiyama I et al. *Detecting early oral cancer: narrow-band imaging system observation of the oral mucosa microvasculature*. *Int J Oral Maxillofac Surg* 2010;39:208-13.
- 7 Bertino G, Cacciola S, Fernandes WB Jr, et al. *Effectiveness of narrow band imaging in the detection of premalignant and malignant lesions of the larynx: Validation of a new endoscopic clinical classification*. *Head Neck* 2015;37:215-22.
- 8 Meier JD, Oliver DA, Varvares MA. *Surgical margin determination in head and neck oncology: current clinical practice. The results of an International American Head and Neck Society Member Survey*. *Head Neck* 2005;27:952-8.
- 9 Hinni ML, Ferlito A, Brandwein-Gensler MS, et al. *Surgical margins in head and neck cancer: a contemporary review*. *Head Neck* 2013;35:1362-70.
- 10 Denis F, Garaud P, Bardet E et al. *Final results of the 94-01 French Head and Neck Oncology and Radiotherapy Group randomized trial comparing radiotherapy alone with concomitant radiochemotherapy in advanced-stage oropharynx carcinoma*. *J Clin Oncol* 2004;22:69-76.
- 11 Machtay M, Rosenthal DI, Algazy KM, et al. *Pilot study of organ preservation multimodality therapy for locally advanced resectable oropharyngeal carcinoma*. *Am J Clin Oncol* 2000;23:509-15.
- 12 Weinstein GS, O'Malley BW Jr, Cohen MA, et al. *Transoral robotic surgery for advanced oropharyngeal carcinoma*. *Arch Otolaryngol Head Neck Surg* 2010;136:1079-85.
- 13 Pellini R, Mercante G, Ruscito P, et al. *Ectopic lingual goiter treated by transoral robotic surgery*. *Acta Otorhinolaryngol Ital* 2013;33:343-6.
- 14 Genden EM, Kotz T, Tong CCL, et al. *Transoral robotic resection and reconstruction for head and neck cancer*. *Laryngoscope* 2011;121:1668-74.
- 15 Durmus K, Apuhan T, Ozer E. *Transoral robotic surgery for retromolar trigone tumours*. *Acta Otorhinolaryngol Ital* 2013;33:425-7.
- 16 Mercante G, Ruscito P, Pellini R et al. *Transoral robotic surgery (TORS) for tongue base tumours*. *Acta Otorhinolaryngol Ital* 2013;33:230-5.
- 17 Yu H, Friedlander DF, Patel S, et al. *The current status of robotic oncologic surgery*. *CA Cancer J Clin* 2013;63:45-56.
- 18 Blanco RGF, Fakry C, Ha PK, et al. *Transoral robotic surgery experience in 44 cases*. *J Laparoendosc Adv Surg Tech A* 2013;23:800-907.
- 19 White H, Ford S, Bush B, et al. *Salvage surgery for recurrent cancers of the oropharynx: comparing TORS with standard open surgical approaches*. *JAMA Otolaryngol Head Neck Surg* 2013;139:773-8.
- 20 Cooper JS, Pajak TF, Forastiere AA, et al. *Postoperative concurrent radiotherapy and chemotherapy for high-risk squamous-cell carcinoma of the head and neck*. *N Engl J Med* 2004;350:1937-44.
- 21 Mannelli G, Meccariello G, Deganello A, et al. *Impact of low-thermal-injury devices on margin status in laryngeal cancer. An experimental ex vivo study*. *Oral Oncol* 2014;50:32-9.
- 22 Patsias A, Giraldez-Rodriguez L, Polydorides A et al. *Feasibility of transoral robotic-assisted high resolution microendoscopic imaging of oropharyngeal squamous cell carcinoma*. *Head Neck* 2014 Oct 17 [Epub ahead of print].
- 23 Tateya I, Ishikawa S, Morita S, et al. *Magnifying endoscopy with narrow band imaging to determine the extent of resection in transoral robotic surgery of oropharyngeal cancer*. *Case Rep Otolaryngol* 2014;2014:604737.
- 24 Itoi T, Tsuji S, Sofuni A, et al. *A novel approach emphasizing preoperative margin enhancement of tumour of the major duodenal papilla with narrow-band imaging in comparison to indigo carmine chromoendoscopy*. *Gastrointestinal Endoscopy* 2009;69:136-4.
- 25 White HN, Frederick J, Zimmerman T, et al. *Learning curve for transoral robotic surgery: a 4-year analysis*. *JAMA Otolaryngol Head Neck Surg* 2013;139:564-7.
- 26 Tateya I, Morita S, Muto M, et al. *Magnifying endoscope with NBI To predict the depth of invasion in laryngo-pharyngeal cancer*. *Laryngoscope* 2015;125:1124-9.

Received: November 26, 2014 - Accepted: March 8, 2015

Address for correspondence: Giuseppe Meccariello, ENT, Head-Neck Surgery and Oral Surgery Unit, Department of Special Surgery, "Morgagni Pierantoni Hospital", Forlì, Italy. Tel. +39 054 3735656. E-mail: drmeccariello@gmail.com

HEAD AND NECK

Salvage surgery in post-chemoradiation laryngeal and hypopharyngeal carcinoma: outcome and review

Chirurgia di salvataggio nel carcinoma della laringe o dell'ipofaringe post-chemioradioterapia: risultati e revisione della letteratura

L. VAN DER PUTTEN^{1,2}, R. DE BREE^{1,3}, P.A. DOORNAERT⁴, J. BUTER⁵, S.E.J. EERENSTEIN¹, D.H.F. RIETVELD⁴, D.J. KUIK⁶, C.R. LEEMANS¹

¹ Department of Otolaryngology-Head and Neck Surgery, VU University Medical Center, Amsterdam, The Netherlands; ² Department of Otolaryngology, Medical Center Alkmaar, Alkmaar, The Netherlands; ³ Department of Head and Neck Surgical Oncology, UMC Utrecht Cancer Center, UMCU Utrecht, Utrecht, The Netherlands; ⁴ Department of Radiation Oncology, VU University Medical Center, Amsterdam, The Netherlands; ⁵ Department of Medical Oncology, VU University Medical Center, Amsterdam, The Netherlands; ⁶ Department of Clinical Epidemiology and Biostatistics, VU University Medical Center, Amsterdam, The Netherlands

SUMMARY

Our objective was to evaluate recurrence patterns of hypopharyngeal and laryngeal carcinoma after chemoradiation and options for salvage surgery, with special emphasis on elderly patients. In a retrospective study all patients who underwent chemoradiation for hypopharyngeal and laryngeal carcinoma in a tertiary care academic center from 1990 through 2010 were evaluated. Primary outcome measures were the survival and complication rates of patients undergoing salvage surgery, especially in elderly patients. Secondary outcome measures were the predictors for salvage surgery for patients with locoregional recurrence after failed chemoradiotherapy. A review of the literature was performed. Of the 136 included patients, 60 patients had recurrent locoregional disease, of whom 22 underwent salvage surgery. Fifteen patients underwent a total laryngectomy with neck dissection(s) and 7 neck dissection without primary tumour surgery. Independent predictors for salvage surgery within the group of 60 patients with recurrent disease, were age under the median of 59 years ($p = 0.036$) and larynx vs. hypopharynx ($p = 0.002$) in multivariate analyses. The complication rate was 68% (14% major and 54% minor), with fistulas in 23% of the patients. Significantly more wound related complications occurred in patients with current excessive alcohol use ($p = 0.04$). Five-year disease free control rate of 35%, overall survival rate of 27% and disease specific survival rate of 35% were found. For the 38 patients who were not suitable for salvage surgery, median survival was 12 months. Patients in whom the tumour was controlled had a 5-year overall survival of 70%. In patients selected for salvage surgery age was not predictive for complications and survival. In conclusion, at two years follow-up after chemoradiation 40% of the patients were diagnosed with recurrent locoregional disease. One third underwent salvage surgery with 35% 5-year disease specific survival and 14% major complications. Older patients selected for salvage surgery had a similar complication rate and survival as younger patients.

KEY WORDS: Laryngeal cancer • Hypopharyngeal cancer • Salvage surgery • Chemoradiation • Complications • Survival • Elderly • Review

RIASSUNTO

Il nostro obiettivo è stato quello di valutare i pattern di recidiva dei carcinomi della laringe e dell'ipofaringe dopo chemioradioterapia, e le opzioni chirurgiche per un trattamento di salvataggio, con particolare attenzione ai pazienti anziani. Sono stati valutati retrospettivamente tutti i pazienti sottoposti a chemioradioterapia per carcinoma dell'ipofaringe e della laringe dal 1990 al 2010, trattati presso un policlinico universitario. Le principali misure dell'outcome sono state la sopravvivenza e il tasso di complicanze dei pazienti sottoposti a chirurgia di salvataggio. Sono stati valutati i fattori predittivi per la chirurgia di salvataggio nei pazienti con recidiva locoregionale dopo fallimento radiochemioterapico. È stata infine eseguita una revisione della letteratura. Dei 136 pazienti inclusi nello studio, 60 hanno avuto una recidiva locoregionale e 22 di questi sono stati sottoposti a chirurgia di salvataggio. 15 pazienti sono stati sottoposti a una laringectomia totale con svuotamento e 7 pazienti sono stati sottoposti solo a svuotamento laterocervicale. Nel gruppo dei 60 pazienti con recidiva di malattia, i fattori predittivi per la chirurgia di salvataggio emersi all'analisi multivariata sono stati l'età inferiore a 59 anni ($p = 0,036$) e la localizzazione laringea rispetto a quella ipofaringea ($p = 0,002$). La percentuale di complicanze registrata è stata del 68% (14% maggiori e 54% minori), con il 23% di fistole. Nei pazienti soggetti ad abuso di sostanze alcoliche si è registrata una maggiore quantità di complicanze relative alla ferita chirurgica ($p = 0,04$). Il controllo di malattia a 5 anni è stato del 35%, la sopravvivenza è stata del 27% e la sopravvivenza cancro specifica è stata del 35%. La sopravvivenza mediana per i 38 pazienti non sottoponibili a chirurgia di salvataggio è stata di 12 mesi. Per i pazienti nei quali si è ottenuto un controllo di malattia la sopravvivenza a 5 anni è stata del 70%. Per i pazienti sottoposti a chirurgia di salvataggio l'età non ha rappresentato un fattore predittivo né della sopravvivenza né del tasso di complicanze. In conclusione dopo due anni di follow-up dalla chemioradioterapia è stata diagnosticata una recidiva locoregionale nel 40% dei pazienti. Un terzo è stato sottoposto a chirurgia di salvataggio con una sopravvivenza cancro specifica a 5 anni del 35% e un 14% di complicanze maggiori. I pazienti anziani, selezionati per la chirurgia di salvataggio, hanno avuto un tasso di sopravvivenza e di complicanze maggiori sovrapponibili a quelli dei pazienti più giovani.

PAROLE CHIAVE: Cancro della laringe • Cancro dell'ipofaringe • Chirurgia di salvataggio • Chemioradioterapia • Complicazioni • Sopravvivenza • Anziani • Revisione della letteratura

Introduction

Treatment of advanced stage squamous cell carcinoma of larynx and hypopharynx constitutes a challenging situation. Cisplatin-based chemoradiation is an established treatment for selected moderately advanced laryngeal and hypopharyngeal carcinoma, as it may be organ and function sparing¹⁻⁴.

For recurrent disease, salvage laryngectomy or neck dissection may be available as a curative option for selected patients. However, the complication rate of salvage surgery after chemoradiation is relatively high. Wound healing problems are a well-known consequence of surgery in irradiated patients. Fistula rates of 11-58% after salvage laryngectomy are reported⁵⁻¹¹. Due to further locoregional recurrence after salvage laryngectomy, distant metastases, second primaries and other causes, the 5-year overall survival is in the range of 31-57%¹²⁻¹⁵. The literature suffers from heterogeneity as to tumour site, previous therapy and salvage therapy.

Herein, we aim to provide insight into the recurrence pattern after chemoradiation for laryngeal and hypopharyngeal carcinoma and the options for salvage surgery. We were specifically interested in the complications after salvage surgery, with focus on age. Moreover, the outcome of patients after salvage surgery is evaluated.

Materials and methods

Patients

Sixty patients with locoregional disease after chemoradiation were identified from a database of 136 patients with laryngeal or hypopharyngeal squamous cell carcinoma treated by chemoradiation with curative intent between January 1990-April 2010. The hospital charts of these patients were retrospectively reviewed. In all patients response to chemoradiation was evaluated within or at 3 months after treatment, unless patients had died during or shortly after the chemoradiation. Resectability prior to treatment was determined by physical examination, imaging and endoscopy. Approval of the Medical Ethics Committee of the VU University Medical Center in Amsterdam was obtained. Patient and treatment characteristics are shown in Table I.

We defined chemoradiation as the combined use of cisplatin based chemotherapy and/or targeted therapy and radiotherapy for the primary treatment. Different schemes are used. Fourteen patients were treated according to an alternating scheme (cisplatin 20 mg/kg and 5-FU 200 mg/kg (i.v.) in week 1, 4, 7 and 10; radiotherapy in week 2, 3, 5, 6, 8 and 9, total dose 60 Gy) and 13 according to a sequential scheme (cisplatin 100 mg/kg and 5-FU 1000 mg/kg i.v., 4 courses; followed by 7 weeks radiotherapy, total dose 70 Gy). Twenty-four patients were treated with concomitant intravenous administration of 3 × 100 mg/m² cisplatin

Table I. Patient characteristics of 60 patients with locoregional disease after chemoradiation.

Variables	Number	Percentage (%)
Gender		
Male	51	85
Female	9	15
T-stage (prior to chemoradiation)		
T2	3	5
T3	30	50
T4	27	45
N-stage (prior to chemoradiation)		
N0	15	25
N1	7	12
N2a	3	5
N2b	13	22
N2c	17	28
N3	5	8
Primary site		
Hypopharynx	35	58
Larynx	25	42
Operability		
Unresectable	4	7
Organ preservation approach	56	93
Chemoradiation schedule		
Cisplatin IA [*]	2	3
Cisplatin IV [*]	24	40
Cisplatin/5-FU alternating ^{**}	14	24
Cisplatin/5-FU sequential ^{***}	13	22
Cetuximab ^{****}	5	8
Cetuximab/TPF/Cisplatin or carboplatin ^{*****}	2	3

^{*}Concurrent four intra-arterial cisplatin (150 mg/m²) infusions or three intravenous cisplatin (100 mg/m²) infusions. In both schemes patients were radiated with 70 Gy irradiation (6-7 weeks); ^{**}cisplatin 20 mg/kg and 5-FU 200 mg/kg intravenously in week 1, 4, 7, 10; radiotherapy in week 2, 3, 5, 6, 8, 9, total dose 60 Gy; ^{***}cisplatin 100 mg/kg and 5-FU 1000 mg/kg intravenously, 4 courses; followed by 7 weeks radiotherapy, total dose 70 Gy; ^{****}weekly cetuximab in combination with 7 weeks radiotherapy, total dose 70 Gy; ^{*****}2-4 courses of TPF (Docetaxel, Platinum, Fluorouracil), followed by cisplatin or carboplatin with concurrent 70 Gy radiotherapy (7 weeks), in some patients cetuximab was given during this treatment.

on day 1, 22 and 43 with simultaneous radiotherapy. Two patients were treated according to the intra-arterial chemoradiation schedule consisting of four consecutive weekly selective intra-arterial infusions of cisplatin (150 mg/m²) followed by intravenous sodium thiosulphate rescue combined with simultaneous radiotherapy. All patients were irradiated daily for 6-7 weeks to a total dose of 70 Gy (2 Gy per fraction, 5-6/week). Two patients were treated according to the concomitant intravenous cisplatin protocol, in combination with cetuximab. Five patients received weekly cetuximab (loading dose 400 mg/m², followed by weekly 250 mg/m²) with daily radiotherapy for 7 weeks to a total dose of 70 Gy. Both sides of the neck were radiated in all patients, regardless of the lymph node status.

Definitions

Postoperative complications were categorised into surgical complications (fistula, infection, necrosis, haemorrhage and chyle leakage), pneumonia and other complications (e.g. spondylodiscitis). Complications were classified as major if they required re-operation.

Statistics

Statistical analysis was performed with SPSS 15.0. Survival rates were calculated with the Kaplan-Meier method, with follow-up intervals calculated from the date of salvage surgery. Univariate analysis of survival parameters was done using the log-rank test. Univariate analyses of complication patterns were assessed by utilizing the χ^2 -test or the independent-samples T-test whenever applicable. Multivariate analysis of survival was performed with Cox regression. A model developed by Tan et al.¹⁶ with stratification factors for survival, was applied to our population.

Results

After a median follow-up of 25 months (range 0-130 months), 60 patients (44%) had presented with recurrent disease. One-third of the patients with recurrent disease (n = 22) underwent salvage surgery for local, regional or

locoregional disease. This is 16% of the total group of patients initially treated by chemoradiation. Twenty-four percent of patients with laryngeal carcinoma vs. 10% of patients with hypopharyngeal carcinoma underwent salvage surgery. Two-thirds of patients (n = 38) were not suitable for salvage surgery because of distant metastases (n = 30), poor general condition of the patient (n = 3), refusal of surgery by the patient (n = 1) or unresectability of the tumour (n = 4).

Of the 6 patients with an initial unresectable tumour, 4 patients developed recurrent disease, which was not statistically different from the organ preservation (initial resectable) group. Two patients developed distant metastases and 2 patients were diagnosed with persistent unresectable local disease. Independent predictors for salvage surgery within the group of 60 patients with recurrent disease, were age younger than 59 years (p = 0.036) and larynx vs. hypopharynx (p = 0.002) in multivariate analyses. Gender, T- and N-stage were not associated with surgery for salvage. The median interval between radiotherapy and recurrence for the 22 patients was 4 months.

The study population consisted of 19 males and 3 females with a median age of 59 years (range: 40-69 years), with primary tumours in larynx (n = 15) and hypopharynx (n = 7) (Table II).

Table II. Patient and salvage surgery characteristics.

Patient	Gender	Age	T	N	Site	Recurrence	Larynx	ND*	Reconstruction	Subsequent reconstruction
1	F	52	4	1	Hypopharynx	Local	Laryngectomy	Bilateral	FRFF+PM	PM
2	M	57	3	2b	Larynx	Regional	-	Unilateral	PC	
3	M	64	4	0	Larynx	Local	Laryngectomy	Unilateral	PM	
4	M	63	4	0	Larynx	Local	Laryngectomy	Bilateral	PM	PM
5	M	62	4	0	Larynx	Local	Laryngectomy	Unilateral	PM	
6	M	59	3	2c	Hypopharynx	Regional	-	Bilateral	PM	
7	M	41	3	0	Hypopharynx	Local	Laryngectomy	Unilateral	PM	
8	M	55	4	2c	Larynx	Local	Laryngectomy	Bilateral	PM	
9	M	67	4	0	Larynx	Local	Laryngectomy	Bilateral	PM	
10	M	57	3	2b	Larynx	Local	Laryngectomy	Bilateral	PM	
11	M	52	4	3	Hypopharynx	Regional	-	Unilateral	PM	
12	M	49	3	2a	Larynx	Regional	-	Unilateral	PC	\$
13	M	54	4	2c	Larynx	Locoregional	Laryngectomy	Bilateral	PC	
14	M	58	2	2b	Hypopharynx	Regional	-	Unilateral	PC	
15	M	53	3	2c	Larynx	Local	Laryngectomy	Bilateral	PM	
16	M	55	3	0	Larynx	Local	Laryngectomy	Bilateral	PM	
17	M	61	3	2c	Hypopharynx	Regional	-	Unilateral	PM	
18	F	59	3	0	Larynx	Local	Laryngectomy	Bilateral	PM	
19	M	69	4	0	Larynx	Local	Laryngectomy	Bilateral	PM	
20	F	67	3	1	Larynx	Local	Laryngectomy	Bilateral	PM	
21	M	58	4	3	Hypopharynx	Local	Laryngectomy	Bilateral	PM	
22	M	64	3	2c	Larynx	Regional	-	Unilateral	PM	

* 1 year after ND: total salvage laryngectomy with FRFF and PM, followed by a second PM for complications. ND: neck dissection; PC: primary closed; PM: pectoralis major flap; FRFF: free radial forearm flap.

Neck dissection was performed in all patients. In 15 patients the salvage operation consisted of a total laryngectomy with unilateral ($n = 2$) or bilateral ($n = 13$) neck dissection. In 7 patients the surgery was limited to a neck dissection because the primary was controlled.

Histopathological examination of total laryngectomy with neck dissection showed negative resection margins in 11 patients (74%), close margins in 2 patients (13%) and microscopic positive margins in 2 patients (13%). Of the patients with neck dissection without laryngectomy 6 had negative resection margins (86%) and 1 microscopic positive margins (14%). No difference in histopathological results between the larynx and hypopharynx was found. Of the two patients with positive margins one was treated with postoperative radiotherapy, but he developed a local recurrence for which he received palliative chemotherapy. One of the patients with close margins developed a recurrence at the stoma and oesophagus, and underwent palliative radiotherapy and chemotherapy.

Reconstruction

The pectoralis major myocutaneous or myofascial pectoralis major (PM) flap was the most often used flap after total laryngectomy with or without pharyngectomy. Primary closure was only possible with smaller defects. With larger defects, when between one-third and three-quarters of the pharyngeal circumference has been resected, reconstruction was performed by utilising a pectoralis major myocutaneous PM flap. A circumferential pharyngeal defect not extending into the chest was free radial forearm flap (FRFF). A myofascial PM flap was also used to reinforce pharyngeal defects¹⁷. The mucosal defect was closed primarily in 9 of the 15 patients (60%), reconstructed with a PM flap in 5 patients, and reconstructed with a free radial forearm flap (FRFF) in 1 patient. A PM flap to prevent wound healing problems was used in 9 of the 15 patients with a total laryngectomy and in 4 of the 7 patients with a neck dissection without laryngectomy.

Postoperative complications

No perioperative death occurred. Postoperative complications were observed in 15 (68%) of the 22 patients (Table III). Three patients experienced major complications that required re-operation. This concerned fistula in two patients and a bleeding in one patient that were closed with a (second) PM flap during re-operation. Most of the complications concerned wound healing problems ($n = 13$; 59%), as fistula ($n = 5$), wound dehiscence or wound infection ($n = 7$) or haemorrhage ($n = 1$). Other complications were pneumonia and spondylodiscitis in 2 patients.

Univariate analysis showed significantly more wound healing problems in patients with excessive alcohol intake (8 of 16 patients (50%) vs. none of 5 patients, $p = 0.04$). Furthermore, none of the following parameters were predictive for the development of postopera-

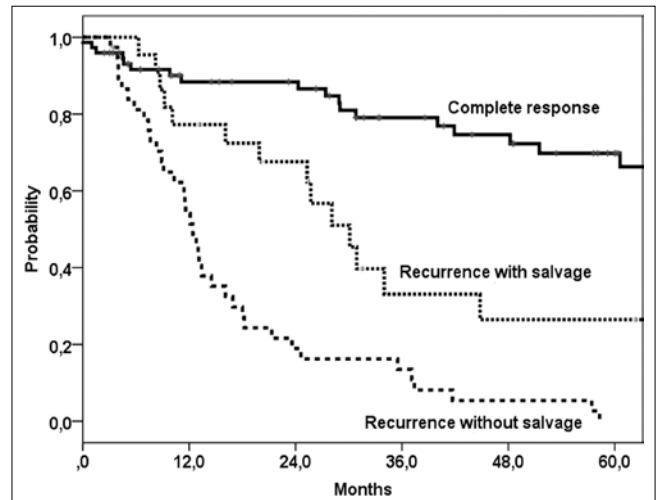


Fig. 1. Five-year survival after the last treatment (chemoradiation or salvage surgery).

tive complications: tobacco use or excessive alcohol intake at the time of presentation for the primary tumour, T- or N-stage, site of the primary tumour and age under the median of 59 years. No significant reduction in overall complications, wound related complications or fistula was found in our group of patients with a PM flap after neck dissection compared to patients with a primarily closed neck dissection.

Survival

Overall, 5-year disease free control rate was 35%, with 5-year locoregional and distant metastases control rates of 54% and 77%, respectively. Five-year overall survival was 27% (median 30 months) (Fig. 1), and disease specific survival was 35% after salvage surgery. For the 38 patients with residual or recurrent disease after chemoradiation who were not suitable for salvage surgery median survival was 12 months. Patients with tumour control ($n = 76$) had a 5-year survival of 70% (median 96 months) (Fig. 1). In uni- and multivariate analyses no significant

Table III. Postoperative complications for the total salvage surgery group, the group with an opened pharynx vs. the group with a closed pharynx.

Complications	Total		Pharynx open		Pharynx closed	
	N	%	N	%	N	%
None	7	31%	4	27%	3	43%
Wound healing	13	59%	9	59%	4	57%
- Infection or dehiscence	7	31%	5	32%	2	29%
- Haemorrhage	1	5%	0	0%	1	14%
- Fistula	5	23%	4	27%	1	14%
Pneumonia	1	5%	1	7%	0	0%
Other	1	5%	1	7%	0	0%
Total	22	100%	15	100%	7	100%

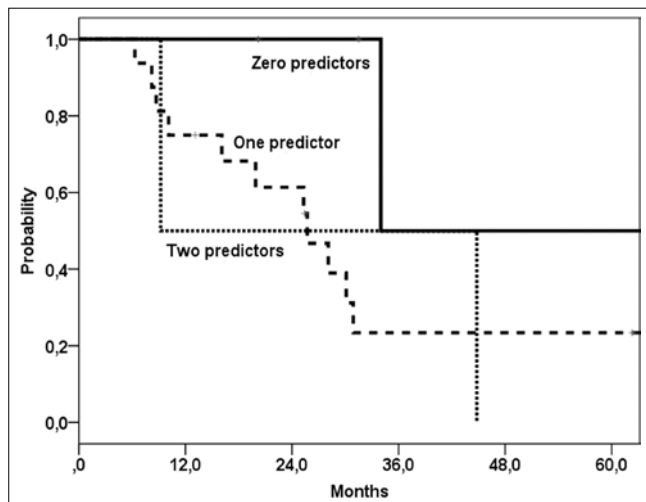


Fig. 2. Survival after salvage surgery with model according to Tan et al.¹⁶ Comparison between patients with zero, one or two of the following presalvage predictors: stage IV vs. other stages and simultaneous locoregional vs. local or regional failure. No significant difference between the three groups was found.

predictors for overall survival after salvage surgery were found. Thus, age under or above the median 60 years was not a predictor factor for survival. The model of Tan et al.¹⁶ stratified patients with none, one or two of the following predictors for post salvage overall survival: stage IV (*vs.* other stages) and simultaneous (*vs.* local or regional) failure. When this model was applied to our population, no significant differences between the groups could be found (Fig. 2), although the group with stage IV disease showed a worse overall survival compared to patients with stage II or III disease (Fig. 3).

With a median length of follow-up after salvage surgery of 26 months (range 6-127 months), recurrent disease was found in 12 of the 22 patients (64%). These recurrences included local and/or regional recurrences in 8 patients and distant metastases in 4 patients. Local recurrences, regional recurrences and distant metastasis developed after a median interval of 6.5 months (range 2.5-14.3), 7.5 months (range 4.4-14.3) and 3.7 months (range 0-28.2) after salvage surgery, respectively.

Discussion

In this study, 37% of the patients with local and/or regional recurrences after chemoradiation for a laryngeal or hypopharyngeal tumour underwent salvage surgery, which is similar to rates reported by other authors, 33-66%^{7 14 16 18}. A larger proportion of patients with recurrent laryngeal than hypopharyngeal tumours underwent salvage surgery. This is in accordance with the report by Esteller et al.¹⁸ Independent predictors for salvage surgery within in the group of patients with locoregional failure, were age less than 59 year and larynx primary (*vs.* hypopharynx).

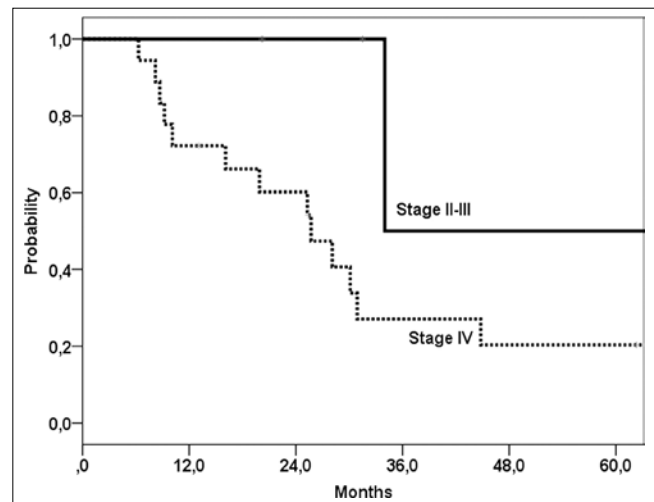


Fig. 3. Survival after salvage surgery with model according to Tan et al.¹⁶ Comparison between patients initial stage IV vs. initial non-stage IV disease. A trend ($p = 0.05$) towards a worse survival for patients with initial stage IV disease was found.

Fifteen patients underwent laryngectomy with neck dissection and 7 patients neck dissection only.

The rates of complications after salvage surgery are known to be high, with wound related complications and especially pharyngocutaneous fistula as a major problem. In this study 23% of patients developed a fistula. Review of the literature shows complication rates of 5-78%, with fistula in 4-73% of the patients (Table IV). Studies are difficult to compare, because of lack of homogeneity in patients (tumour site, stage) and in primary treatment (radiotherapy, chemoradiation).

If wound healing problems are likely, pedicled PM flaps are very useful to cover important structures in the neck with well vascularised, non-irradiated tissue. In the present study, in 59% of the patients a PM flap was used for prevention of wound related complications. Unfortunately, no significant reduction in overall complications, wound related complications or fistula was found in our group of patients with a PM flap after neck dissection compared to patients with a primarily closed neck dissection. In our population only patients with considerable postradiation effects who were considered to be prone to wound healing problems underwent reconstruction with PM flap in the neck. Most studies evaluating reconstructive methods are conducted in patients undergoing salvage laryngectomy (Table V). Similar to our results, no difference in the incidence of local wound complications or fistula between the groups with and without PM flap was found by Gil et al.⁵ and Righini et al.¹⁹ Although it was an effective technique to prevent major complications, free vascularised tissue reinforcement did not alter the overall fistula rate as compared to when no flap was used, as reported by Fung et al.²⁰ Smith et al.²¹ reported a significant reduction in

Table IV. Previous studies on complications and survival outcome in patients with salvage surgery after chemoradiotherapy for squamous cell carcinoma of the hypopharynx and larynx.

Authors	Year	N	Site	Comp	Fistula	LR	OS	DSS	Remarks
Stoeckli ⁷	2000	36	L	28%	14%			63% (5 y)	RT and CRT
Stoeckli ⁷	2000	9	H	40%	11%			20% (5 y)	RT and CRT
Leon ¹⁴	2001	28	L	21%	17%		57% (5 y)		endoresection
Weber ³⁵	2003	75	L	~59%	~30%	74% (2 y)	69-71% (2 y)		
Ganly ²⁶	2005	38	L	53%	32%				
Clark ¹³	2006	138	L/H	70% (salvage)	31%			31% (5 y) (salvage)	PT: none, RT, CRT
Fung ²⁰	2007	14	L		29%				Interposition graft. ngopharyngectomy defects
Furuta ⁴⁴	2008	34	L	47% wound	24%				
Gil ⁵	2009	18	L		39%				PL/TL, RT and CRT
Patel ⁶	2009	17	L		24%				CRT or RT?
Relic ⁴⁵	2009	16	L/H		73%			38% (3 y)	1 PL
Tsou ⁸	2010	48	H		58%				
Paleri ⁴⁶	2011	>350	L			87% (2 y)	83% (3 y)	91% (2 y)	RT and CRT, PL
vd Putten ¹⁵	2011	120	L			70% (5 y) 79% (5 y) regional	50% (5 y)	58% (5 y)	RT and CRT, TL
Klozar ⁴⁷	2012	208	L/H		34%				RT and CRT
Sewnaik ⁴⁸	2012	24	L/H	92%					
Patel ⁹	2013	359	L/H		27%				RT and CRT, primLE
Li ¹²	2013	100	L			70% (5 y)		55-70% (5 y)	RT and CRT, survival
Basheeth ⁴⁹	2013	45	L/H	44%					Major complications, NO
Suzuki ⁵⁰	2013	24	H	33%				50% (2 y)	
Sayles ¹⁰	2014	33 st	L/H		34%				
Timmermans ³¹	2014	98	L/H		26%				RT and CRT, primLE
Omura ⁵¹	2014	42	H					40% (3 y)	RT and CRT, ICT
Powell ⁵²	2014	45	L/H		22%				
Suslu ¹¹	2015	151	L/H		13%				RT and CRT, ICT
Sassler ³⁰	1995	18	HN	61% major	50%				Sequential CRT
Newman ⁵³	1997	17	HN	35%	20%				
Lavertu ³⁴	1998	26	HN	46%	4%				
Goodwin ³⁷	2000	109	HN	20%	6%			Med 21.5 months	PT: surgery, RT, CRT (17%)
Goodwin ³⁷	2000	1633	HN	39%				39% (5 y)	PT: surgery, RT, CRT
Agra ⁵⁴	2003	124	HN	78% (CRT)					PT: surgery, RT, CRT
Gleich ⁵⁵	2004	48	HN			20% (5 y)		15% (5 y)	Local recurrence
Taussky ⁵⁶	2005	17	HN N	76%	24%			46% (3 y) 13% (5 y)	RT and CRT
Morgan ⁵⁷	2007	38	HN	11%	5%				Local compl 23%
Encinas ⁵⁸	2007	26	HN	31%					Article not available
Richey ³⁹	2007	38	HN	24%		42% (2 y)		27-60% (1,2 y)	
Tan ¹⁶	2010	38	HN	63%				43% (2 y) 37% (5 y)	
Inohara ³⁶	2010	30	HN	30%	7%			74-87% (3 y)	
Esteller ¹⁸	2011	32	HN	28%	19%			34% (5 y)	
Simon ⁵⁹	2011	21	HN	33%	10%				
Leon ⁶⁰	2015	24	HN	63% 13%				26%(5 y) 70%(5 y)	CRT Bioradiotherapy

(continues)

Table IV. Previous studies on complications and survival outcome in patients with salvage surgery after chemoradiotherapy for squamous cell carcinoma of the hypopharynx and larynx (follows).

Authors	Year	N	Site	Comp	Fistula	LR	OS	DSS	Remarks
Present study		22	HN	73%	23%	58% (5 y)	27% (5 y)	36% (5 y)	
Davidson ²⁷	1999	34	N	38%	12%				37% CRT
Stenson ⁶¹	2000	69	N	25%	10%				
Newkirk ⁶²	2001	33	N						13 CRT, 20 RT.
Grabnbauer ⁶³	2003	56	N	25%	4%		44%(5 y)	55%	Planned ND
Kutler ⁶⁴	2004		N	~30%					Only abstract
Brizel ⁶⁵	2004	52	N	8% major		75% (4 y)	77%(4 y)		Planned ND in N2-3. survival cCR
Frank ⁶⁶	2005	39	N	5% surgical					
vd Putten ⁶⁷	2007	61	N			79% (5 y)	36% (5 y)		
Nouraei ⁶⁸	2008	41	N			95% (5 y)		64% (5 y)	Survival hemineck
Vedrine ⁶⁹	2008	28	N	14% severe					
Christopoulos ⁷⁰	2008	32	N	13%					
Lango ⁷¹	2009	65	N	18%	5%				55% CRT
Relic ⁴⁵	2009	12	N	8%					
Hillel ⁷²	2009	41	N	17%					
Bremke ⁷³	2009	25	N	24%					
Goguen ²⁸	2010	105	N	37%					
Robbins ⁷⁴	2012	30	N					60% (5 y)	SSND, CRT
Yirbesoglu ⁷⁵	2013	44	N			71-73% (3 y)	55-64% (3 y)		

* Systematic review; y: year; Com: complications, fistul: fistula, LR: locoregional control rate, OS: overall survival, DSS: disease specific survival, L: larynx, H: hypopharynx, HN: head and neck, N: neck, y: year, DFS: disease free survival, CRT: chemoradiotherapy, RT: radiotherapy, CT: chemotherapy, ND: neck dissection, PT: previous treatment, PL: partial laryngectomy, TL: total laryngectomy, primLE: primary laryngectomy, SSND: super selective neck dissection, st: studies, ICT: induction chemotherapy.

Table V. Comparison of pharyngocutaneous fistula in patients with salvage laryngectomy with and without flap reinforcement. In two studies, besides for reinforcement, the flap was also used to reconstruct pharyngeal defects^{21,23}.

Authors	Year	N	Site	Flap	Fistula	WC	Fistula No flap	WC No flap	p	Remarks
Righini ¹⁹	2005	60	larynx	PMMF	23%		50%		0.06	Radiotherapy
			larynx	PMMF	13%		73%		0.018	Subgroup: diabetes mellitus, vascular history, poor nutritional status
Fung ²⁰	2007	41	larynx	FVT	29%	0%	30%	15%	n.s.	
Patel ⁶	2009	17	larynx	PMF	0%		57%		0.02	(Chemo)radiotherapy
Gil ⁵	2009	80	larynx	PMMF	27%		24%		n.s.	PMMF 64% CRT, nonPMMF 25% CRT
Smith ²¹	2003	223	larynx	PMF	<1%		23%			
Withrow ²³	2007	37	larynx	FRFF	18%		50%			FRFF 41% CRT, nonFRFF 35% CRT
Patel ⁹	2013	359	larynx	PMF	15%		34%		0.02	(Chemo)radiotherapy
				FVT	25%				0.07	
Powell ⁵²	2014	45	larynx	FVT/PMF	0%		26%			
Sayles ¹⁰	2014	33 studies	larynx	Onlay flap	10%		28%		0.001	(Chemo)radiotherapy
Paleri ²²	2014	591	larynx							Pooled relative risk 0.63 (reduction one third compared to no flap)

* Systematic review; WC: wound complications, p: p-value, PMMF: pectoralis major myofascial flap, FVT: free vascularised tissue, PMF: pectoralis major flap, FRFF: free radial forearm flap, CRT: chemoradiotherapy.

fistula formation in patients with as compared to patients without PM flap reconstruction, but the percentage of patients with initial chemoradiation vs. primary surgery was not described. Sayles et al.¹⁰ performed a review and meta-analysis of 33 studies, and found only 10% fistula for salvage laryngectomy with onlay flap-reinforced closure

compared to 28% fistula for salvage laryngectomy when no flap was used. Recently Paleri et al.²² described in a systematic review of nearly 600 patients a reduced risk of fistula by one-third in patients who have flap reconstruction/reinforcement. Reconstruction of the mucosal defect using a PM flap may be associated with a higher rate of

fistulae as compared to primary closure whereas a PM flap used as layer between mucosa and skin may reduce the risk of fistula formation. According to Righini et al.¹⁹, fistula formation in postradiotherapy salvage surgery was reduced from 73% to 13% when a flap was used in the subgroup of patients with diabetes mellitus, a history of vascular disease or a poor nutritional status. Tsoe et al.⁸ and Withrow et al.²³ suggest to reconstruct laryngectomy defects with an ALT (anterolateral thigh) or FRFF flap, as the incidence of fistula was low in their study.

Besides hypoalbuminaemia, neck dissection, comorbidities with diabetes mellitus or ischaemic heart disease, Tsoe et al.⁸ found that reconstruction of the pharynx with primary closure had a statistically significant increased rate of fistula formation. On the contrary, Shemen et al.²⁴ and Herranz et al.²⁵ found an increase in complication rate when flap reconstruction was required. These patients had no history of radiation, and probably had a greater defect when a flap was required. Ganly et al.²⁶ found no association between wound complications and flap reconstruction or neck dissection. The only significant independent predictor found was chemoradiation. Other suggested potential predictors for increased wound complications and fistula are: postoperative haemoglobin level lower than 12.5 g/dl, albumin level less than 40 g/l, prior tracheotomy, preoperative radio- and/or chemotherapy, concurrent neck dissection, radical neck dissection, poor nutritional status, tobacco and excessive alcohol use, poor renal and hepatic function, radiotherapy doses in excess of 70 Gy, early removal of drains (within 3 days of operation), vacuum drain duration and surgery extended to the pharynx or hypopharynx cancer^{11 27-31}. We found more wound related complications in patients with current excessive alcohol use. This might be caused by immunosuppression due to ethanol, or alcohol-related lifestyle factors such as certain dietary deficiencies owing to unevenly composed diets³².

Whether the interval between chemoradiotherapy and salvage surgery influences the risk of fistula formation remains uncertain. Increased incidence of wound complications was reported when the interval was shorter^{23 25 33}. However, Lavertu et al.³⁴ and Weber et al.³⁵ found no significant difference between groups with short and longer interval between chemoradiation and salvage surgery. Inohara et al.³⁶ found no difference in complication incidence between salvage surgery for persistent or recurrent disease. We also did not find an association between interval and complication rate.

Comparing our results in patients with salvage laryngectomy: a) after previous radiotherapy in a previous study¹⁵; to b) after previous chemoradiotherapy in the present study, shows a worse 5-year prognosis for local disease control (58% vs. 70%) and overall survival (27% vs. 50%) in the chemoradiotherapy group. The total complication rate is 73% after chemoradiotherapy vs. 56% after radiotherapy.

The 5-year overall survival of 27% is comparable to other series, with a relatively better survival for patients with recurrent laryngeal carcinoma (compared to hypopharyngeal) or patients with a regional recurrence (Table IV). Even after adjusting for covariates, Goodwin³⁷ found that a history of chemotherapy was associated with poorer survival after salvage surgery, suggesting a more aggressive tumour biology³⁸. Because of the low survival and high complication rates, the profit of salvage surgery is sometimes questioned. Salvage surgery is definitely worthwhile in a subset of patients. Reliable predictors for survival after salvage surgery are needed. Tan et al.¹⁶ suggested a model with stage IV tumours and concurrent local and regional failures as independent negative predictors. Esteller et al.¹⁸ found no significant differences in survival when analysed according to the classification of Tan. We found a worse survival for stage IV initial tumours. Other suggested potential predictors for a worse survival are: residual disease, older age, N3, positive resection margins and neck nodes with extranodal spread^{18 38 39}.

In this series age was an independent predictor for salvage surgery. Older patients were less frequently candidate for salvage surgery if recurrent tumour was diagnosed. Elderly patients with head and neck cancer generally have multiple and more severe comorbidity⁴⁰. Comorbidity is associated with a higher complication rate and poorer survival after major surgery⁴¹⁻⁴³. Selection of elderly patients based on comorbidity seems to be the explanation for the similar complication rate and survival after salvage surgery. Moreover, patients with severe comorbidity would not have been treated with chemoradiation in the first place and therefore not included in this study.

In conclusion, one third of the patients with local and/or regional disease after chemoradiation underwent salvage surgery. Most of the patients not suitable for salvage surgery had distant metastases. Forty percent of the laryngectomies needed a flap reconstruction to cover mucosal defects. Patients who were at forehand more prone to wound healing failures underwent reconstruction with a PM flap in the neck to prevent wound related complications. One in four patients developed a pharyngocutaneous fistula. Only current excessive alcohol use was associated with complications. No significant independent predictors of survival were identified. The 5-year overall survival rate was 27% after salvage surgery. Older patients with recurrent laryngeal or hypopharyngeal carcinoma after chemoradiation selected for salvage surgery have a similar complication and survival rate compared to younger patients.

Acknowledgement

The authors like to thank Dr. Annalisa M. Lo Galbo for translation in Italian.

References

- ¹ Forastiere AA, Goepfert H, Maor M, et al. *Concurrent chemotherapy and radiotherapy for organ preservation in advanced laryngeal cancer*. N Engl J Med 2003;349:2091-8.
- ² Wolf GT, Hong WK. *Induction chemotherapy for organ preservation in advanced laryngeal cancer: is there a role?* Head Neck 1995;17:279-83.
- ³ Lefebvre JL, Chevalier D, Luboinski B, et al. *Larynx preservation in pyriform sinus cancer: preliminary results of a European Organization for Research and Treatment of Cancer phase III trial. EORTC Head and Neck Cancer Cooperative Group*. J Natl Cancer Inst 1996;88:890-9.
- ⁴ Lefebvre JL, Rolland F, Tesselaar M, et al. *Phase 3 randomized trial on larynx preservation comparing sequential vs alternating chemotherapy and radiotherapy*. J Natl Cancer Inst 2009;101:142-52.
- ⁵ Gil Z, Gupta A, Kummer B, et al. *The role of pectoralis major muscle flap in salvage total laryngectomy*. Arch Otolaryngol Head Neck Surg 2009;135:1019-23.
- ⁶ Patel UA, Keni SP. *Pectoralis myofascial flap during salvage laryngectomy prevents pharyngocutaneous fistula*. Otolaryngol Head Neck Surg 2009;141:190-5.
- ⁷ Stoeckli SJ, Pawlik AB, Lipp M, et al. *Salvage surgery after failure of nonsurgical therapy for carcinoma of the larynx and hypopharynx*. Arch Otolaryngol Head Neck Surg 2000;126:1473-7.
- ⁸ Tsou YA, Hua CH, Lin, et al. *Comparison of pharyngocutaneous fistula between patients followed by primary laryngopharyngectomy and salvage laryngopharyngectomy for advanced hypopharyngeal cancer*. Head Neck 2010;32:1494-500.
- ⁹ Patel UA, Moore BA, Wax M, et al. *Impact of pharyngeal closure technique on fistula after salvage laryngectomy*. JAMA Otolaryngol Head Neck Surg 2013;139:1156-62.
- ¹⁰ Sayles M, Grant DG. *Preventing pharyngo-cutaneous fistula in total laryngectomy: a systematic review and meta-analysis*. Laryngoscope 2014;124:1150-63.
- ¹¹ Süslü N, Senirli RT, Günaydin RÖ, et al. *Pharyngocutaneous fistula after salvage laryngectomy*. Acta Otolaryngol 2015;11:1-7.
- ¹² Li M, Lorenz RR, Khan MJ, et al. *Salvage laryngectomy in patients with recurrent laryngeal cancer in the setting of nonoperative treatment failure*. Otolaryngol Head Neck Surg 2013;149:245-51.
- ¹³ Clark JR, de Almeida J, Gilbert R, et al. *Primary and salvage (hypo)pharyngectomy: Analysis and outcome*. Head Neck 2006;28:671-7.
- ¹⁴ Leon X, Quer M, Orus C, L, et al. *Results of salvage surgery for local or regional recurrence after larynx preservation with induction chemotherapy and radiotherapy*. Head Neck 2001;23:733-78.
- ¹⁵ van der Putten L, de Bree R, Kuik DJ, et al. *Salvage laryngectomy: oncological and functional outcome*. Oral Oncol 2011;47:296-301.
- ¹⁶ Tan HK, Giger R, Auperin A, et al. *Salvage surgery after concomitant chemoradiation in head and neck squamous cell carcinomas - stratification for postsalvage survival*. Head Neck 2010;32:139-47.
- ¹⁷ de Bree R, Rinaldo A, Genden EM, et al. *Modern reconstruction techniques for oral and pharyngeal defects after tumor resection*. Eur Arch Otorhinolaryngol 2008;265:1-9.
- ¹⁸ Esteller E, Vega MC, Lopez M, et al. *Salvage surgery after locoregional failure in head and neck carcinoma patients treated with chemoradiotherapy*. Eur Arch Otorhinolaryngol 2011;268:295-301.
- ¹⁹ Righini C, Lequeux T, Cuisnier O, et al. *The pectoralis myofascial flap in pharyngolaryngeal surgery after radiotherapy*. Eur Arch Otorhinolaryngol 2005;262:357-61.
- ²⁰ Fung K, Teknos TN, Vandenberg CD, et al. *Prevention of wound complications following salvage laryngectomy using free vascularized tissue*. Head Neck 2007;29:425-30.
- ²¹ Smith TJ, Burrage KJ, Ganguly P, et al. *Prevention of post-laryngectomy pharyngocutaneous fistula: the Memorial University experience*. J Otolaryngol 2003;32:222-5.
- ²² Paleri V, Drinnan M, van den Brekel MW, et al. *Vascularized tissue to reduce fistula following salvage total laryngectomy: a systematic review*. Laryngoscope 2014;124:1848-53.
- ²³ Withrow KP, Rosenthal EL, Gourin CG, et al. *Free tissue transfer to manage salvage laryngectomy defects after organ preservation failure*. Laryngoscope 2007;117:781-4.
- ²⁴ Shemen LJ, Spiro RH. *Complications following laryngectomy*. Head Neck Surg 1986;8:185-91.
- ²⁵ Herranz J, Sarandeses A, Fernandez MF, et al. *Complications after total laryngectomy in nonradiated laryngeal and hypopharyngeal carcinomas*. Otolaryngol Head Neck Surg 2000;122:892-8.
- ²⁶ Ganly I, Patel S, Matsuo J, et al. *Postoperative complications of salvage total laryngectomy*. Cancer 2005;103:2073-81.
- ²⁷ Davidson BJ, Newkirk KA, Harter KW, et al. *Complications from planned, posttreatment neck dissections*. Arch Otolaryngol Head Neck Surg 1999;125:401-5.
- ²⁸ Goguen LA, Chapuy CI, Li Y, et al. *Neck dissection after chemoradiotherapy: timing and complications*. Arch Otolaryngol Head Neck Surg 2010;136:1071-7.
- ²⁹ Paydarfar JA, Birkmeyer NJ. *Complications in head and neck surgery: a meta-analysis of postlaryngectomy pharyngocutaneous fistula*. Arch Otolaryngol Head Neck Surg 2006;132:67-72.
- ³⁰ Sassler AM, Esclamado RM, Wolf GT. *Surgery after organ preservation therapy. Analysis of wound complications*. Arch Otolaryngol Head Neck Surg 1995;121:162-5.
- ³¹ Timmermans AJ, Lansaat L, Theunissen EA, et al. *Predictive factors for pharyngocutaneous fistulization after total laryngectomy*. Ann Otol Rhinol Laryngol 2014;123:153-61.
- ³² Seitz HK, Stickele F. *Molecular mechanism of alcohol-mediated carcinogenesis*. Nat Rev Cancer 2007;7:599-612.
- ³³ Hanasono MM, Lin D, Wax MK, et al. *Closure of laryngectomy defects in the age of chemoradiation therapy*. Head Neck 2012;34:580-8.
- ³⁴ Lavertu P, Bonafede JP, Adelstein DJ, et al. *Comparison of surgical complications after organ-preservation therapy in patients with stage III or IV squamous cell head and neck cancer*. Arch Otolaryngol Head Neck Surg 1998;124:401-6.
- ³⁵ Weber RS, Berkey BA, Forastiere A, et al. *Outcome of salvage total laryngectomy following organ preservation therapy: the Radiation Therapy Oncology Group trial 91-11*. Arch Otolaryngol Head Neck Surg 2003;129:44-9.

- 36 Inohara H, Tomiyama Y, Yoshii T, et al. [Complications and clinical outcome of salvage surgery after concurrent chemoradiotherapy for advanced head and neck squamous cell carcinoma]. *Nippon Jibiinkoka Gakkai Kaiho* 2010;113:889-7.
- 37 Goodwin WJ, Jr. *Salvage surgery for patients with recurrent squamous cell carcinoma of the upper aerodigestive tract: when do the ends justify the means?* *Laryngoscope* 2000;110:1-18.
- 38 Zafereo ME, Hanasono MM, Rosenthal DI, et al. *The role of salvage surgery in patients with recurrent squamous cell carcinoma of the oropharynx.* *Cancer* 2009;115:5723-33.
- 39 Richey LM, Shores CG, George J, et al. *The effectiveness of salvage surgery after the failure of primary concomitant chemoradiation in head and neck cancer.* *Otolaryngol Head Neck Surg* 2007;136:98-103.
- 40 Peters TT, Langendijk JA, Plaat BE, et al. *Co-morbidity and treatment outcomes of elderly pharyngeal cancer patients: a matched control study.* *Oral Oncol* 2011;47:1159-64.
- 41 Borggreven PA, Kuik DJ, Langendijk JA, et al. *Severe co-morbidity negatively influences prognosis in patients with oral and oropharyngeal cancer after surgical treatment with microvascular reconstruction.* *Oral Oncol* 2005;41:358-64.
- 42 Oskam IM, Verdonck-de Leeuw IM, Aaronson NK, et al. *Quality of life as predictor of survival: a prospective study on patients treated with combined surgery and radiotherapy for advanced oral and oropharyngeal cancer.* *Radiother Oncol* 2010;97:258-62.
- 43 Gourin CG, Starmer HM, Herbert RJ, et al. *Short- and long-term outcomes of laryngeal cancer care in the elderly.* *Laryngoscope* 2015;125:924-33.
- 44 Furuta Y, Homma A, Oridate N, et al. *Surgical complications of salvage total laryngectomy following concurrent chemoradiotherapy.* *Int J Clin Oncol* 2008;13:521-527.
- 45 Relic A, Scheich M, Stapf J, et al. *Salvage surgery after induction chemotherapy with paclitaxel/cisplatin and primary radiotherapy for advanced laryngeal and hypopharyngeal carcinomas.* *Eur Arch Otorhinolaryngol* 2009;266:1799-805.
- 46 Paleri V, Thomas L, Basavaiah N, et al. *Oncologic outcomes of open conservation laryngectomy for radiorecurrent laryngeal carcinoma: A systematic review and meta-analysis of English-language literature.* *Cancer* 2011;117:2668-76.
- 47 Klozar J, Cada Z, Koslabova E. *Complications of total laryngectomy in the era of chemoradiation.* *Eur Arch Otorhinolaryngol* 2012;269:289-93.
- 48 Sewnaik A, Keereweer S, Al-Mamgani A, et al. *High complication risk of salvage surgery after chemoradiation failures.* *Acta Otolaryngol* 2012;132:96-100.
- 49 Basheeth N, O'Leary G, Sheahan P. *Elective neck dissection for no neck during salvage total laryngectomy: findings, complications, and oncological outcome.* *JAMA Otolaryngol Head Neck Surg* 2013;139:790-6.
- 50 Suzuki K, Hayashi R, Ebihara M, et al. *The effectiveness of chemoradiation therapy and salvage surgery for hypopharyngeal squamous cell carcinoma.* *Jpn J Clin Oncol* 2013;43:1210-7.
- 51 Omura G, Saito Y, Ando M, et al. *Salvage surgery for local residual or recurrent pharyngeal cancer after radiotherapy or chemoradiotherapy.* *Laryngoscope* 2014;124:2075-80.
- 52 Powell J, Ullal UR, Ahmed O, et al. *Tissue transfer to post-chemoradiation salvage laryngectomy defects to prevent pharyngocutaneous fistula: single-centre experience.* *J Laryngol Otol* 2014;1:1-3.
- 53 Newman JP, Terris DJ, Pinto HA, et al. *Surgical morbidity of neck dissection after chemoradiotherapy in advanced head and neck cancer.* *Ann Otol Rhinol Laryngol* 1997;106:117-22.
- 54 Agra IM, Carvalho AL, Pontes E, et al. *Postoperative complications after en bloc salvage surgery for head and neck cancer.* *Arch Otolaryngol Head Neck Surg* 2003;129:1317-21.
- 55 Gleich LL, Ryzenman J, Gluckman JL, et al. *Recurrent advanced (T3 or T4) head and neck squamous cell carcinoma: is salvage possible?* *Arch Otolaryngol Head Neck Surg* 2004;130:35-8.
- 56 Taussky D, Dulguerov P, Allal AS. *Salvage surgery after radical accelerated radiotherapy with concomitant boost technique for head and neck carcinomas.* *Head Neck* 2005;27:182-6.
- 57 Morgan JE, Breau RL, Suen JY, et al. *Surgical wound complications after intensive chemoradiotherapy for advanced squamous cell carcinoma of the head and neck.* *Arch Otolaryngol Head Neck Surg* 2007;133:10-4.
- 58 Encinas VA, Souviron ER, Rodriguez PA, et al. [Surgical complications in salvage surgery of patients with head and neck carcinomas treated with concomitant chemoradiotherapy (CCR)]. *Acta Otorrinolaringol Esp* 2007;58:454-7.
- 59 Simon C, Bulut C, Federspil PA, et al. *Assessment of peri- and postoperative complications and Karnofsky-performance status in head and neck cancer patients after radiation or chemoradiation that underwent surgery with regional or free-flap reconstruction for salvage, palliation, or to improve function.* *Radiat Oncol* 2011;6:109.
- 60 León X, Agüero A, López M, et al. *Salvage surgery after local recurrence in patients with head and neck carcinoma treated with chemoradiotherapy or bioradiotherapy.* *Auris Nasus Larynx* 2015;42:145-9.
- 61 Stenson KM, Haraf DJ, Pelzer H, et al. *The role of cervical lymphadenectomy after aggressive concomitant chemoradiotherapy: the feasibility of selective neck dissection.* *Arch Otolaryngol Head Neck Surg* 2000;126:950-6.
- 62 Newkirk KA, Cullen KJ, Harter KW, et al. *Planned neck dissection for advanced primary head and neck malignancy treated with organ preservation therapy: disease control and survival outcomes.* *Head Neck* 2001;23:73-9.
- 63 Grabenbauer GG, Rodel C, Ernst-Stecken A, et al. *Neck dissection following radiochemotherapy of advanced head and neck cancer - for selected cases only?* *Radiother Oncol* 2003;66:57-63.
- 64 Kutler DI, Patel SG, Shah JP. *The role of neck dissection following definitive chemoradiation.* *Oncology (Williston Park)* 2004;18:993-8.
- 65 Brizel DM, Prosnitz RG, Hunter S, et al. *Necessity for adjuvant neck dissection in setting of concurrent chemoradiation for advanced head-and-neck cancer.* *Int J Radiat Oncol Biol Phys* 2004;58:1418-23.
- 66 Frank DK, Hu KS, Culliney BE, et al. *Planned neck dissection after concomitant radiochemotherapy for advanced head and neck cancer.* *Laryngoscope* 2005;115:1015-20.
- 67 van der Putten L, van den Broek GB, de Bree R, et al. *Effectiveness of salvage selective and modified radical neck*

- dissection for regional pathologic lymphadenopathy after chemoradiation.* Head Neck 2009;31:593-603.
- ⁶⁸ Nouraei SA, Upile T, Al-Yaghchi C, et al. *Role of planned postchemoradiotherapy selective neck dissection in the multimodality management of head and neck cancer.* Laryngoscope 2008;118:797-803.
- ⁶⁹ Vedrine PO, Thariat J, Hitier M, et al. *Need for neck dissection after radiochemotherapy? A study of the French GETTEC Group.* Laryngoscope 2008;118:1775-80.
- ⁷⁰ Christopoulos A, Nguyen-Tan PF, Tabet JC, et al. *Neck dissection following concurrent chemoradiation for advanced head and neck carcinoma: pathologic findings and complications.* J Otolaryngol Head Neck Surg 2008;37:452-6.
- ⁷¹ Lango MN, Andrews GA, Ahmad S, et al. *Postradiotherapy neck dissection for head and neck squamous cell carcinoma: pattern of pathologic residual carcinoma and prognosis.* Head Neck 2009;31:328-37.
- ⁷² Hillel AT, Fakhry C, Pai SI, et al. *Selective versus comprehensive neck dissection after chemoradiation for advanced oropharyngeal squamous cell carcinoma.* Otolaryngol Head Neck Surg 2009;141:737-42.
- ⁷³ Bremke M, Barth PJ, Sesterhenn AM, et al. *Prospective study on neck dissection after primary chemoradiation therapy in stage IV pharyngeal cancer.* Anticancer Res 2009;29:2645-53.
- ⁷⁴ Robbins KT, Dhiwakar M, Vieira F, et al. *Efficacy of super-selective neck dissection following chemoradiation for advanced head and neck cancer.* Oral Oncol 2012;48:1185-9.
- ⁷⁵ Yirmibesoglu E, Fried D, Shores C, et al. *Incidence of subclinical nodal disease at the time of salvage surgery for locally recurrent head and neck cancer initially treated with definitive radiation therapy.* Am J Clin Oncol 2013;36:475-80.

Received: December 2, 2014 - Accepted: April 15, 2015

RHINOLOGY

Transorbital transnasal endoscopic combined approach to the anterior and middle skull base: a laboratory investigation

Approccio endoscopico combinato transnasale e transorbitario alla fossa cranica anteriore e media: studio su cadavere

A. ALQAHTANI^{1,2}, G. PADOAN², G. SEGNINI³, D. LEPERA², S. FORTUNATO³, I. DALLAN³, A. PISTOCHINI², S. ABDULRAHMAN², V. ABBATE⁴, B. HIRT⁵, P. CASTELNUOVO²

¹ Department of Otorhinolaryngology/Head and neck surgery, Prince Sultan Military Medical City, Riyadh, Saudi Arabia;

² Department of Otorhinolaryngology, University of Insubria, Varese, Italy; ³ First Otorhinolaryngology unit, Azienda Ospedaliera Universitaria Pisana, Pisa, Italy; ⁴ Maxillofacial Department, University of Naples "Federico II", Naples, Italy;

⁵ Department of Otorhinolaryngology-Head and Neck Surgery, University of Tubingen Medical Center, Tubingen, Germany

SUMMARY

Orbital approaches provide significant trajectory to the skull base and are used with differently designed pathways. The aim of this study is to investigate the feasibility of a combined transorbital and transnasal approach to the anterior and middle cranial fossa. Cadaveric dissection of five silicon-injected heads was used. A total of 10 bilateral transorbital approaches and 5 extended endonasal approaches were performed. Identification of surgical landmarks, main anatomical structures, feasibility of a combined approach and reconstruction of the superior orbital defect were examined. Rod lens endoscope (with 0° and 45° lenses) and endoscopic instruments were used to complete the dissection. The transorbital approach showed good versatility and provides the surgeon with a direct route to the anterior and middle cranial fossa. The transorbital avascular plane showed no conflict with major nerves or vessels. Large exposure area from crista galli to the third ventricle was demonstrated with significant control of different neurovascular structures. A combined transorbital transnasal approach provides considerable value in terms of extent of exposure and free hand movement of the two surgeons, and allows better visualisation and control of the ventral skull base, thus overcoming the current surgical limits of a single approach. Combination of these two minimally invasive approaches should reduce overall morbidity. Clinical trials are needed to evaluate the virtual applications of this approach.

KEY WORDS: Skull base • Transorbital • Transnasal • Endoscopic • Reconstruction • Minimally invasive

RIASSUNTO

Gli approcci transorbitari permettono di ottenere un'ampia via d'accesso al basicranio e sono utilizzati in diverse procedure chirurgiche. Lo scopo di questo studio è valutare la fattibilità di un approccio endoscopico combinato transorbitario e transnasale alla fossa cranica anteriore e media. Su cinque teste iniettate con silicone, sono stati eseguiti un totale di 10 approcci endoscopici transorbitari e 5 "extended endonasal approach" (EEA). Durante le procedure sono stati identificati i punti di repere chirurgici e le strutture anatomiche principali, valutando la fattibilità dell'approccio combinato e della successiva ricostruzione del tetto orbitario. Per eseguire la dissezione sono stati utilizzati endoscopi rigidi con sistema a lente cilindrica 0° e 45° e una strumentazione endoscopica dedicata. L'approccio transorbitario ha mostrato grande versatilità ed ha permesso al chirurgo di ottenere un corridoio diretto alla fossa cranica anteriore e media. Il piano transorbitario avascolare non era in conflitto con vasi o nervi maggiori. La dissezione ha mostrato una vasta esposizione del basicranio, dalla crista galli fino al terzo ventricolo, assicurando un controllo efficace sulle strutture neurovascolari circostanti. L'approccio combinato transorbitario e transnasale ha portato dei vantaggi significativi sia nell'ampiezza dell'esposizione che nella manovrabilità della strumentazione chirurgica. L'approccio endoscopico combinato transnasale e transorbitario ha dimostrato una migliore visualizzazione del basicranio ventrale e di poter superare alcune attuali limitazioni dei due singoli approcci. Inoltre la combinazione di due approcci mini-invasivi dovrebbe contribuire a ridurre la morbilità chirurgica. Sono tuttavia necessari studi clinici per validare questo approccio.

PAROLE CHIAVE: Basicranio • Transnasale • Endoscopia • Ricostruzione • Mini invasivo

Acta Otorhinolaryngol Ital 2015;35:173-179

Introduction

Several approaches to ventral anterior and middle cranial fossa have been described¹. In recent years, the indications of extended endonasal approach have rapidly expanded to include a wide spectrum of central skull base pathologies^{2,3}.

With all the merits of this approach, it allows limited access to lesions that are crossing neurovascular structures or laterally seated^{4,5}. Diminished visualisation in such cases might lead to incomplete resection or devastating complications. Comparatively, traditional external approaches have wide exposure and control of the lesion, but are associated with

increased postoperative functional and cosmetic sequelae. Thus, the need for a technique that minimises the morbidity of endonasal and external approaches without compromising resectability is desired.

Transorbital approaches have been used to treat orbital lesions⁶⁻⁸. The peculiar position and extent in the ventral skull base place the orbit in the limelight as a desirable corridor to the skull base.

Ciporen and Moe et al. demonstrated four transorbital approaches in which each of targeted different area of the skull base^{9,10}.

Herein, we demonstrate the feasibility of combined endonasal and transorbital approach to the anterior and middle cranial base along with evaluation of skull base reconstruction.

Materials and methods

Five cadaveric specimens (10 sides) with intravascular injection of colored silicone were dissected in the anatomy laboratory of University of Tubingen Medical Center following approval by the local institutional ethics board.

Rod-lens Hopkins endoscopes (Karl Storz, Tuttlingen Germany) of 4 mm in diameter and 18 cm in length were used with 0° and 45° lenses and were coupled to a high-definition cameras and monitors (Karl Storz, Tuttlingen Germany). High-speed drills with straight and angled hand pieces, and diamond and cutting burrs were used along with paranasal sinus and skull base endoscopic instruments (Karl Storz, Tuttlingen, Germany). All procedures were documented by high definition camera and AIDA recording system (Karl Storz, Tuttlingen, Germany). A total of 15 procedures were

performed, five extended endonasal approaches and 10 bilateral transorbital approaches. Two surgeons dissected the specimens in parallel, standing on both sides of the specimen and using two endoscopes and monitors. One surgeon performed the endonasal approach, while the other performed the transorbital approach.

Surgical steps

The extended endonasal approach was performed on 5 specimens. Bilateral wide maxillary antrostomy, bilateral complete sphenoidectomy, septectomy, frontal sinusotomy (Draf type III) followed by transcribriform, transplanum, transtuberculum, and transsellar resection were performed in all specimens. Additionally, each specimen underwent a transorbital approach through transpalpebral incision. Transverse supratarsal skin incision was around 10 mm above the upper eyelid edge. The incision went through orbicularis muscle as well. To avoid injury of the orbital septum, the myo-cutaneous flap was dissected and elevated superiorly and tangentially to orbicularis muscle until reaching the superior bony orbital rim (Fig. 1). The periostium was cut against the bone of the orbital rim to create the plane for superior orbital wall dissection. Attention must be paid in preserving the supraorbital and supratrochlear neurovascular bundles, which are situated at the junction of medial 1/3 and lateral 2/3 of superior orbital rim. The periorbita was preserved and dissected down carefully by an elevator until reaching the anterior and posterior ethmoidal arteries medially, optic nerve posteriorly and superior orbital fissure posterolaterally (Fig. 2). Subsequently, a 0° endoscope was intro-

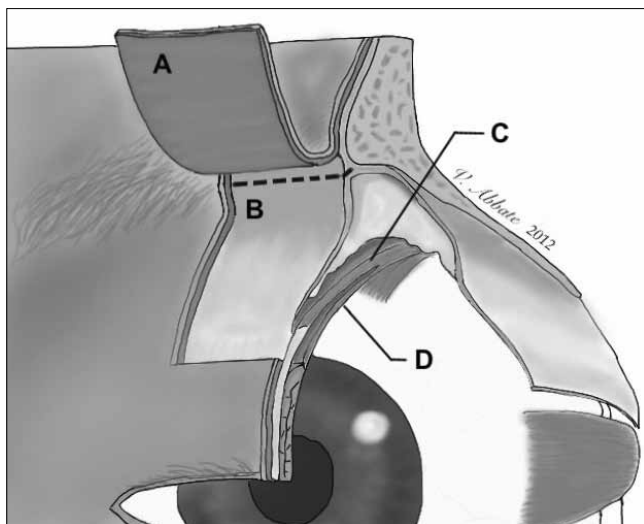


Fig. 1. Left eye 3D cross-section view shows the plane of the transorbital approach and the supratarsal skin incision that is 10 mm above the tarsus, extending from the middle third of the upper eyelid to the lateral cantus. (A) Elevated musculocutaneous flap, (B) dashed line shows the correct septal incision that reach the subperiosteal orbital roof plane, (C) levator palpebrae superioris, (D) superior tarsal muscle (Müller muscle).

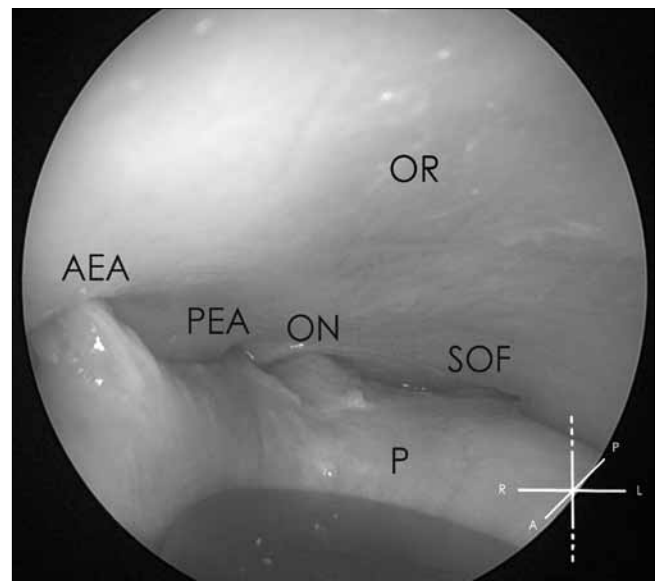


Fig. 2. Endoscopic view of the left eye shows the major landmarks for designing the craniectomy in the orbital roof (OR): anterior ethmoidal artery (AEA), posterior ethmoidal artery (PEA), optic nerve (ON) and superior orbital fissure (SOF). Malleable retractor applies pressure over the periorbita (P).

duced to control the subsequent steps. Mini-craniectomy was performed in the weakest point of superior orbital wall using a high-speed diamond drill. A piece of silastic sheet was applied to protect the orbit during this step and a malleable retractor pushed the orbit downwards to gain space. Widening of the craniectomy was accomplished using Kerrison punch forceps. The medial limit for the craniectomy was the anterior and posterior ethmoidal arteries. The medial orbital wall and lateral portion of the fovea ethmoidalis were preserved to support the skull base reconstruction. The dura was then incised carefully at the edges of the craniectomy.

Transorbital intracranial endoscopic exploration was carried out to identify the important anatomical structures that can be reached. The ipsilateral and contralateral anterior cranial fossa were explored as well as the middle cranial fossa.

Thereafter, endonasal and transorbital combined exploration was performed by two surgeons through the two approaches to identify structures in the anterior and middle cranial fossa jointly. One surgeon had the access through an endonasal route with an independent monitor and the other has access through a transorbital route with another independent monitor. Accessibility and visualisation of important structures were assessed during this step. Cooperative dissection was performed in the form of bone drilling, precise cutting of the dura and handling important structures such as the optic nerve, cavernous/supra-clinoid internal carotid artery (ICA) and sellar/suprasellar structures. The surgeons alternated the roles and instruments during this part to assess the range of motion and maneuverability. Visualization through one route and dissection through the other or combined dissection were all performed.

A multilayer technique was used for skull base reconstruction. Intracranial intradural layer with synthetic graft was used followed by muco-periosteal septal graft that was used

in overlay fashion to cover the superior orbital wall defect. The main outcome measure of this study was to determine the feasibility of this combined approach in the anterior and middle cranial fossa by assessing the extent of the dissection, the ability to synchronously work intracranially and to perform superior orbital wall reconstruction.

Results

The transorbital endoscopic approach provides the surgeon with a direct route to the anterior and middle cranial fossa. The endoscopic plane is at the same level of the structures of the ventral skull base. Intracranial intradural exploration with 0° and 45° endoscopes demonstrated the accessibility of different areas. The following structures can be seen from anterior to posterior direction: posterior wall of frontal sinus, crista galli, frontal lobe, cribriform plate, olfactory tract, planum sphenoidal, tuberculum sellae, anterior/posterior clinoid process, cavernous ICA, supraclinoid ICA, anterior communicating artery, diaphragmatic sellae, pituitary gland, hypophyseal stalk, superolateral portion of cavernous sinus, oculomotor nerve, optic nerve, optic chiasm, optic tract and intracranial cisterns (chiasmatic, carotid, sylvian and lamina terminalis) (Fig. 3).

The transnasal extended approach combined with a transorbital endoscopic approach showed higher visualisation and tissue handling than either single approach alone. The combined approach also provided the surgeon with full visualisation and control of the optic nerve and supraclinoid carotid. Bi-portal intracranial cooperative dissection between the two surgeons was excellent in terms of the capability of lightening deep-seated structures, exchanging roles in dissection and assistance in skull base reconstruction.

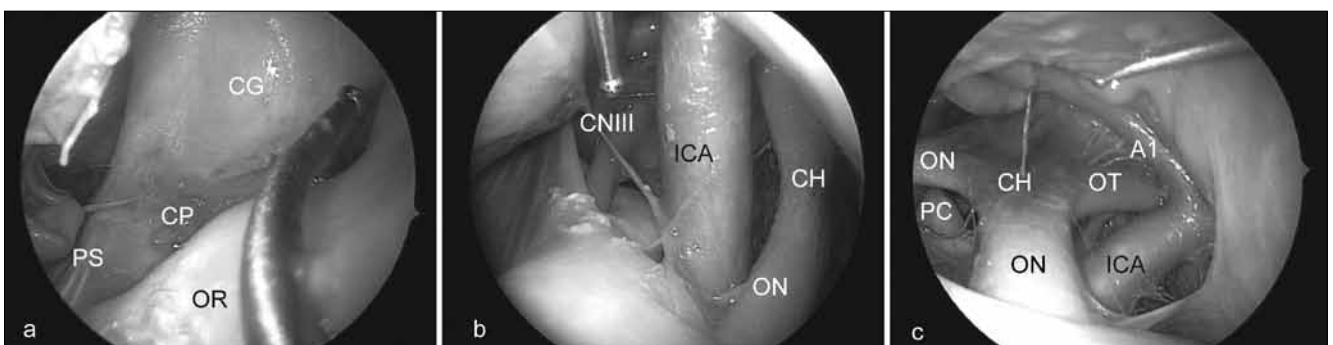


Fig. 3. Endoscopic intracranial intradural exploration through superior orbital wall craniectomy. a) Right-sided anterior cranial fossa is viewed using a 45° endoscope. A curved probe is used along with an angled endoscope; b) by using a 0° endoscope on the right side, major neurovascular structures can be approached immediately once passing the craniectomy without crossing major structures. The supraclinoid internal carotid artery (ICA), optic nerve (ON) and cavernous sinus are easily visualised; c) left-sided middle cranial fossa is widely accessible with using 0° endoscope. Lesions involving or crossing optic nerve or ICA can be clearly visualised through this approach. (CG) crista galli, (CP) cribriform plate, (PS) planum sphenoidale, (OR) orbital roof, (CNIII) third cranial nerve, (OT) optic tract, (CH) optic chiasm, (PC) posterior clinoid process and (A1) pre-communicating artery.

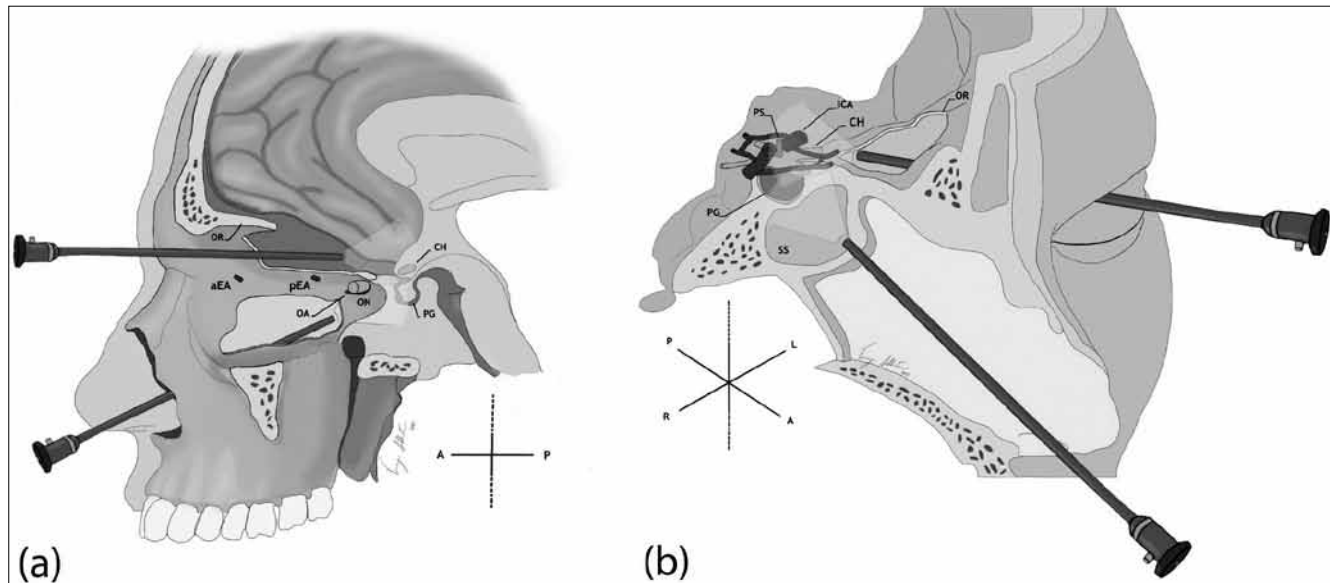


Fig. 4. Cross-sectional a) sagittal and b) parasagittal view show the visual field of the two endoscopes with the combined transorbital and transnasal approach. To allow a correct view, the orbital content and part of the lamina papyracea have been removed in (a). Transorbital approach provides coplanar trajectory of skull base while endonasal view provide basal control. (OR) orbital roof, (aEA) anterior ethmoid artery, (pEA) posterior ethmoid artery, (OA) ophthalmic artery, (ON) optic nerve, (PG) pituitary gland, (CH) optic chiasma, (PS) pituitary stalk, (SS) sphenoid sinus, (ICA) internal carotid artery.

Meticulous incision and myo-cutaneous flap elevation is essential to avoid orbital complications. Keeping the plane just under orbicularis oculi muscle will prevent injury to the septum. Preserving the orbital septum makes injury of levator palpebrae superioris muscle or periorbital markedly avoidable. The plane of dissection is avascular which eases flap elevation.

The anterior and posterior ethmoidal arteries are considered landmarks for the medial limit of the craniectomy except in case of pneumatized supraorbital recess. A pre-operative CT scan and CT navigation system can help in localising the proper site of craniectomy. However, the size and location of the craniectomy can be adjusted according to the pathology.

We found that standard skull base instruments are satisfactory in the combined approach. However, in order to protect the orbit from introducing angled instruments and to minimise the size of craniectomy, specially designed instruments, such as straight malleable-tips instruments, should be available.

Orbital roof reconstruction with multilayer technique was adequate. The endonasal skull base reconstruction follows the regular principles that have been explained in the literature¹¹.

Discussion

The transorbital endoscopic approach to the skull base provides a panoramic view of frontobasal area. Through variable size craniectomy in the superior orbital wall, the surgeon can access a wide range of structures in the ante-

rior-posterior axis from posterior wall of frontal sinus to the third ventricle and from para-median to lateral position. Designing the craniectomy to be in close-distance allows early cerebrospinal fluid (CSF) release by opening the cisterns before dissecting the pathology. As a result, frontal lobe sinks spontaneously due to gravity-related relaxation will minimise brain retraction. In addition, performing craniectomy close to the lesion permits short working distance to the tumour without crossing neurovascular structures. Furthermore, transorbital access to the anterior and posterior ethmoidal arteries is possible at the very beginning of the procedure. Thus, ligation of these arteries devascularises the lesion early.

The transnasal transorbital endoscopic combined approach improves visualisation of the field (Fig. 4). One of the merits of this combined approach is control of optic nerve and supraclinoid ICA in the form of 360° visualisation. This advantage is of utmost importance in cases of lesions that might extend laterally or superiorly crossing specifically optic nerve or ICA. Creating a bone window just anterior to the optic nerve along with the transnasal approach permits a direct 4-wall access to the nerve.

Synchronous work of two surgeons through 2 portals and 2 endoscopes with 2 monitors helps in dissection, visualisation and guiding each other (Fig. 5). Alternating instruments and the roles between the two surgeons was significantly beneficial. Standing of the surgeons on each side of the patient's head while one works through an endonasal route and the other through a contralateral transorbital route creates a large working space between the two surgeon's hands and promotes better maneuver-

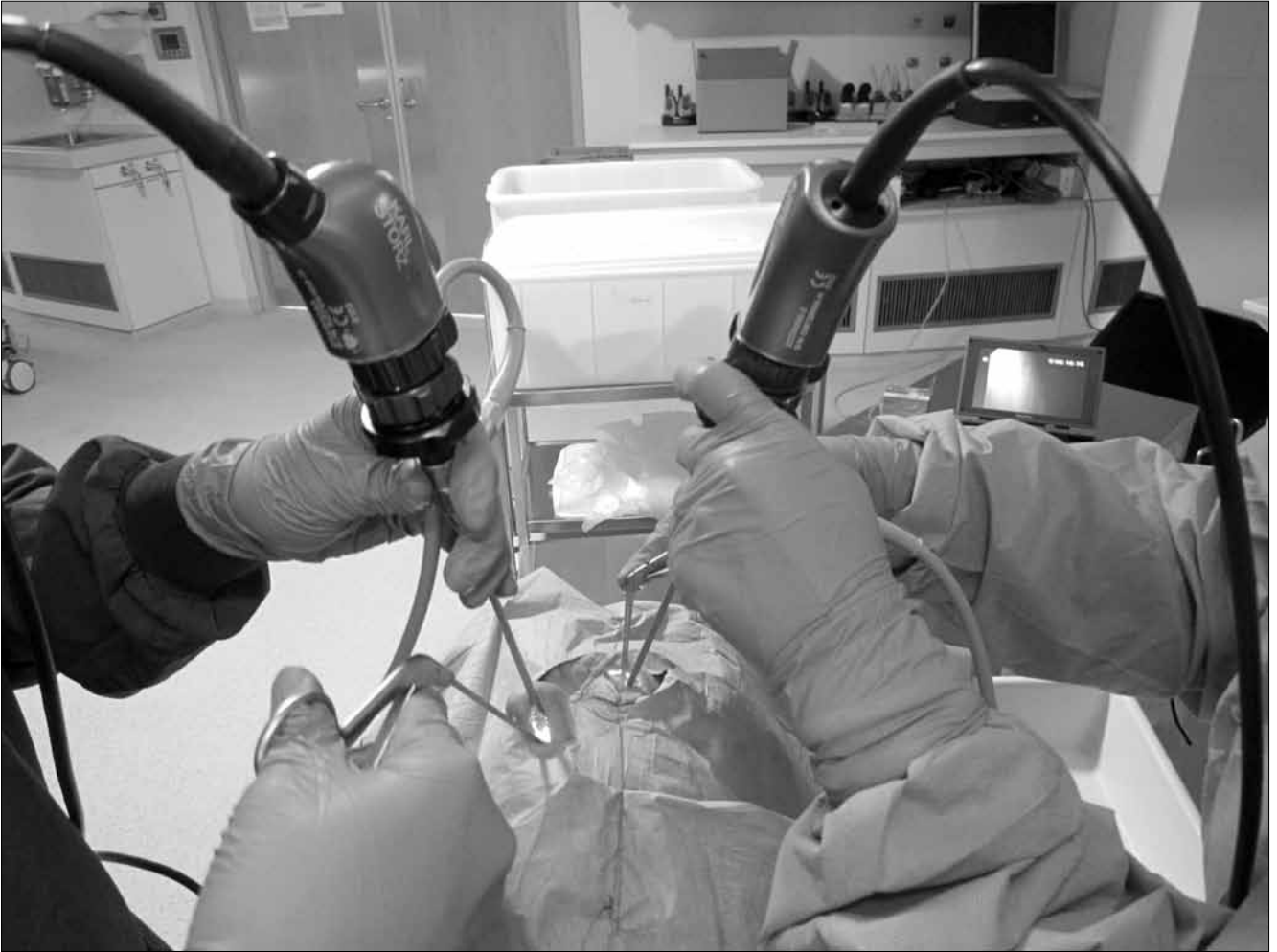


Fig. 5. Illustration of the position of the two surgeons during the dissection, one surgeon on the right side using a transnasal corridor and the other surgeon on the left side using a transorbital corridor. Note the space in the operative field that enables the surgeons to move freely without crossing each other.

ability and freedom that is not provided by a single portal. The “two-team” concept is strengthened since there is no conflict of hands in the operative field.

The additional advantages of this approach are excellent cosmetic results since the incision is within the eyelid natural wrinkle lines, applicable effective skull base reconstruction, less expected morbidity and minimum need for post-operative intensive care admission as well as total days of hospitalisation.

A variety of benign and malignant tumours could be addressed efficiently with these combined corridors like craniopharyngioma, pituitary macroadenoma and meningioma (especially speno-orbital type).

An expanded endonasal approach is now well recognised as part of the armamentarium of surgical techniques in central skull base surgery¹²⁻¹⁶. However, extension of lesions lateral to the central part of the skull base, lesions bounding important neurovascular structures, large-size lesions and poor visualisation in some areas are some limitations of this approach¹⁷⁻²¹. For such cases, com-

binated external approach is needed for better control^{3 4 22}. Many traditional external techniques have been described to manage lesions in the anterior and middle cranial fossa, but significant complications have been reported^{7 23-27}.

The concept of minimally invasive surgery was behind the initiation of keyhole techniques such as the supraorbital approach. Perneczky and others introduced eyebrow incision that provides endoscopic and microscopic large exposure of the operative field through a small craniectomy²⁸⁻³⁴. However, this approach carries some disadvantages that are related to the approach and not to the use of the endoscope. Some of these disadvantages are: scalp anaesthesia due to supratrochlear or supraorbital injury, transient postoperative frontalis muscle palsy due to risk of frontal branch of facial nerve injury, CSF fistula through an occult frontal sinus opening or frontal sinusitis and mucocele as a consequence of inadvertent traversing frontal sinus^{30 35}. Cosmetic results of inappropriate fixation of the bone flap or improper clogging of the burr-hole and saw lines should be considered as well. Hyper-

pneumatised frontal sinus with lateral extension is a major limit for this approach³⁰.

Utilising a transorbital corridor to reach the orbital roof while preserving orbital rim has been studied by Moe et al.¹⁰. They described four transorbital corridors to different areas, namely: superior eyelid crease, lateral retro-canthal, medial precaruncular and preseptal lower eyelid corridors. They reported successful results without significant neurological, orbital or medical complications in the 20 transorbital procedures that were recorded in their series⁹.

Maximum attention should be taken to the orbit when performing the approach. Use of corneal protector or transient tarsorrhaphy, applying silastic sheet or malleable retractor for the periorbita, watchful insertion of instruments and periodic relief of the globe pressure will minimise the risk of unfavourable orbital morbidity^{10 36}. With careful manipulation of the globe, morbidity is almost negligible. In contrast to what we expect, the globe can withstand certain pressures even for long procedures³⁶.

There are some limitations to this approach. It needs a well-qualified team of both an otolaryngologist experienced in rhinology and a neurosurgeon with endoscopic skull base and vascular experience. The anatomical limitation of this approach is the degree of supraorbital recess pneumatisation. In case of high pneumatisation posteriorly and laterally, the craniectomy might be limited and another approach should be used³⁷. Lateral extension of frontal sinus should not be a restriction for this approach, but rather for the supraorbital craniectomy approach³⁰.

Ultimately, clinical trials could endorse this concept and clinically validate the safety and practicality of the combined approach. Thereafter, comparative studies of the different endoscopic approaches to the anterior and middle cranial fossa should follow.

Conclusions

In selected cases, the possibility of minimally invasive skull base surgery can be provided with a transorbital transnasal endoscopic combined approach. Wide range of exposure from posterior wall of frontal sinus to the retrosellar area can be demonstrated. Direct trajectory, clear visualisation and synchronous dissection between the two surgeons are a fruitful aspect of this approach. Multidisciplinary work and careful orbital manipulation will minimise the risk of orbital complications. Clinical applications and limitations can be verified clearly with further clinical review.

References

- 1 Rachinger W, Grau S, Tonn JC. *Different microsurgical approaches to meningiomas of the anterior cranial base*. Acta Neurochir (Wien) 2010;152:931-9.

- 2 Castelnuovo P, Dallan I, Battaglia P, et al. *Endoscopic endonasal skull base surgery: past, present and future*. Eur Arch Otorhinolaryngol 2010;267:649-63.
- 3 Nicolai P, Battaglia P, Bignami M, et al. *Endoscopic surgery for malignant tumors of the sinonasal tract and adjacent skull base: a 10-year experience*. Am J Rhinol 2008;22:308-16.
- 4 Castelnuovo P, Belli E, Bignami M, et al. *Endoscopic nasal and anterior craniotomy resection for malignant nasothmoid tumors involving the anterior skull base*. Skull Base 2006;16:15-8.
- 5 Snyderman CH, Carrau RL, Kassam AB, et al. *Endoscopic skull base surgery: principles of endonasal oncological surgery*. J Surg Oncol 2008;97:658-64.
- 6 Chu EA, Quinones-Hinojosa A, Boahene KD. *Trans-blepharoplasty orbitofrontal craniotomy for repair of lateral and posterior frontal sinus cerebrospinal fluid leak*. Otolaryngol Head Neck Surg 2010;142:906-8.
- 7 Raza SM, Conway JE, Li KW, et al. *A modified frontal-nasal-orbital approach to midline lesions of the anterior cranial fossa and skull base: technical note with case illustrations*. Neurosurg Rev 2010;33:63-70.
- 8 Raza SM, Quinones-Hinojosa A, Lim M, et al. *The transconjunctival transorbital approach: a keyhole approach to the midline anterior skull base*. World Neurosurg 2013;80:864-71.
- 9 Ciporen JN, Moe KS, Ramanathan D, et al. *Multiportal endoscopic approaches to the central skull base: a cadaveric study*. World Neurosurg 2010;73:705-12.
- 10 Moe KS, Bergeron CM, Ellenbogen RG. *Transorbital neuroendoscopic surgery*. Neurosurgery 2010;67(3 Suppl Operative):16-28.
- 11 Locatelli D, Rampa F, Acchiardi I, et al. *Endoscopic endonasal approaches for repair of cerebrospinal fluid leaks: nine-year experience*. Neurosurgery 2006;58(Suppl 2):246-56, discussion 256-7.
- 12 AlQahtani A, Turri-Zanoni M, Dallan I, et al. *Endoscopic endonasal resection of sinonasal and skull base malignancies in children: feasibility and outcomes*. Childs Nerv Syst 2012;28:1905-10.
- 13 AlWeri A, Jho HD. *Endoscopic endonasal approaches to the cavernous sinus: surgical approaches*. Neurosurgery 2001;49:354-60.
- 14 Dave S, Bared A, Casiano RR. *Surgical outcomes and safety of transnasal endoscopic resection for anterior skull tumors*. Otolaryngol Head Neck Surg 2007;136:920-7.
- 15 Lund VJ, Stammberger H, Nicolai P, et al. *European Rhinologic Society Advisory Board on endoscopic techniques in the management of nose, paranasal sinus and skull base tumors: European position paper on endoscopic management of tumors of the nose, paranasal sinuses and skull base*. Rhinol Suppl 2010;22:1-143.
- 16 Nicolai P, Castelnuovo P, Lombardi D, et al. *Role of endoscopic surgery in the management of selected malignant epithelial neoplasms of the naso-ethmoidal complex*. Head Neck 2007;29:1075-82.
- 17 Berhouma M, Jacquesson T, Jouanneau E. *The fully endoscopic supraorbital trans-eyebrow keyhole approach to the anterior and middle skull base*. Acta Neurochir (Wien) 2011;153:1949-54.
- 18 Dehdashti AR, Ganna A, Witterick I, et al. *Expanded endo-*

- scopic endonasal approach for anterior cranial base and parasellar lesions: indications and limitations.* Neurosurgery 2009;64:677-87.
- ¹⁹ De Divitiis E, Cavallo LM, Esposito F, et al. *Extended endoscopic transsphenoidal approach for tuberculum sellae meningiomas.* Neurosurgery 2008;62(Suppl 3):1192-201.
- ²⁰ Kasemsiri P, Carrau RL, Prevedello DM, et al. *Indications and limitations of endoscopic skull base surgery.* Future Neurology 2012;7:263-77.
- ²¹ Snyderman CH, Pant H, Carrau RL, et al. *What are the limits of endoscopic sinus surgery? The expanded endonasal approach to the skull base.* Keio J Med. 2009;58:152-60.
- ²² Batra PS, Citardi MJ, Worley S, et al. *Resection of anterior skull base tumors: Comparison of combined traditional and endoscopic techniques.* Am J Rhinol 2005;19:521-8.
- ²³ Al-Mefty O. *Supraorbital-pterional approach to skull base lesions.* Neurosurgery 1987;21:474-7.
- ²⁴ Burduk PK, Kaźmierczak W, Dalke K, et al. *Craniofacial resection for tumors of paranasal sinuses involving the anterior skull base.* Otolaryngol Pol 2012;66:96-101.
- ²⁵ Elbabaa SK, Al-Mefty O. *Craniofacial approach for anterior skull-base lesions.* Atlas Oral Maxillofac Surg Clin North Am 2010;18:151-60.
- ²⁶ Wang T, Wang X, Li M, et al. *Surgical approaches of anterior skull base tumors.* Lin Chung Er Bi Yan Hou Tou Jing Wai Ke Za Zhi 2007;21:50-1.
- ²⁷ Ganly I, Patel SG, Singh B, et al. *Complications of craniofacial resection for malignant tumors of the skull base: Report of an International Collaborative Study.* Head Neck 2005;27:445-51.
- ²⁸ Melamed I, Merkin V, Korn A, et al. *The supraorbital approach: an alternative to traditional exposure for the surgical management of anterior fossa and parasellar pathology.* Minim Invasive Neurosurg 2005;48:259-63.
- ²⁹ Obeid F, Al-Mefty O. *Recurrence of olfactory groove meningiomas.* Neurosurgery 2003;53:534-42.
- ³⁰ Kabil MS, Shahinian HK. *Application of the supraorbital endoscopic approach to tumors of the anterior cranial base.* J Craniofac Surg 2005;16:1070-4.
- ³¹ Andaluz N, Romano A, Reddy LV, et al. *Eyelid approach to the anterior cranial base.* J Neurosurg 2008;109:341-6.
- ³² Feiz-Erfan I, Spetzler RF, Horn EM, et al. *Proposed classification for the transbasal approach and its modifications.* Skull Base 2008;18:29-47.
- ³³ Jallo GI, Bognar L. *Eyebrow surgery: the supraciliary craniotomy: technical note.* Neurosurgery 2006;59:E157-8.
- ³⁴ Reisch R, Perneczky A. *Ten-year experience with the supraorbital subfrontal approach through an eyebrow skin incision.* Neurosurgery 2005;57:242-55.
- ³⁵ Owusu Boahene KD, Lim M, Chu E, et al. *Transpalpebral orbitofrontal craniotomy: a minimally invasive approach to anterior cranial vault lesions.* Skull Base 2010;20:237-44.
- ³⁶ Sellari-Franceschini S, Lenzi R, Santoro A, et al. *Lateral wall orbital decompression in Graves' orbitopathy.* Int J Oral Maxillofac Surg 2010;39:16-20.
- ³⁷ Gardner PA, Kassam AB, Rothfus WE, et al. *Preoperative and intraoperative imaging for endoscopic endonasal approaches to the skull base.* Otolaryngol Clin N Am 2008;41:215-30, 915-8.

Received: March 4, 2015 - Accepted March 8, 2015

VESTIBOLOGY

Vertigo in childhood: proposal for a diagnostic algorithm based upon clinical experience

La vertigine nell'infanzia: un algoritmo diagnostico alla luce dell'esperienza clinica

A.P. CASANI, I. DALLAN, E. NAVARI, S. SELLARI FRANCESCHINI, N. CERCHIAI

Department of Medical and Surgical Pathology, Otorhinolaryngology Unit, Pisa University Hospital, Italy

SUMMARY

The aim of this paper is to analyse, after clinical experience with a series of patients with established diagnoses and review of the literature, all relevant anamnestic features in order to build a simple diagnostic algorithm for vertigo in childhood. This study is a retrospective chart review. A series of 37 children underwent complete clinical and instrumental vestibular examination. Only neurological disorders or genetic diseases represented exclusion criteria. All diagnoses were reviewed after applying the most recent diagnostic guidelines. In our experience, the most common aetiology for dizziness is vestibular migraine (38%), followed by acute labyrinthitis/neuritis (16%) and somatoform vertigo (16%). Benign paroxysmal vertigo was diagnosed in 4 patients (11%) and paroxysmal torticollis was diagnosed in a 1-year-old child. In 8% (3 patients) of cases, the dizziness had a post-traumatic origin: 1 canalolithiasis of the posterior semicircular canal and 2 labyrinthine concussions, respectively. Menière's disease was diagnosed in 2 cases. A bilateral vestibular failure of unknown origin caused chronic dizziness in 1 patient. In conclusion, this algorithm could represent a good tool for guiding clinical suspicion to correct diagnostic assessment in dizzy children where no neurological findings are detectable. The algorithm has just a few simple steps, based mainly on two aspects to be investigated early: temporal features of vertigo and presence of hearing impairment. A different algorithm has been proposed for cases in which a traumatic origin is suspected.

KEY WORDS: Vertigo • Benign paroxysmal vertigo • Head trauma • Diagnostic algorithm • Vestibular migraine

RIASSUNTO

In questo articolo vengono analizzate, alla luce dell'esperienza clinica e della conoscenza della Letteratura più recente in merito, tutte le caratteristiche anamnestiche della vertigine in età pediatrica, con lo scopo di costruire un semplice algoritmo diagnostico applicabile ai casi di vertigine in età pediatrica. Lo studio si basa sull'analisi retrospettiva dei reperti clinici e strumentali di 37 bambini sottoposti a completa valutazione otoneurologica per riferita sintomatologia vertiginosa. Tutte le diagnosi sono state confermate applicando i più recenti criteri diagnostici internazionali. Nella nostra casistica la più comune causa di vertigine in età pediatrica è risultata quella di origine emicranica (38%), seguita dalla nevrite vestibolare (16%) e dalla vertigine psicogena (16%). La vertigine parossistica benigna dell'infanzia è stata diagnosticata in 4 pazienti (11%), mentre il torcicollo parossistico in 1 bambino di un anno. In un 8% (3 pazienti) la vertigine aveva un'origine post-traumatica. La Malattia di Ménière è stata diagnosticata in 2 casi (5%). Una vestibolopatia bilaterale di origine sconosciuta è stata riconosciuta come causa di una dizziness cronica in un paziente. In conclusione, questo algoritmo può rappresentare un ottimo strumento per guidare il sospetto clinico del medico verso una corretta formulazione della diagnosi nel bambino vertiginoso senza chiari segni di coinvolgimento neurologico. L'algoritmo ha pochi semplici step, basati principalmente su due aspetti fondamentali: andamento temporale della vertigine e presenza di sintomi uditivi. Un algoritmo differente è stato costruito per i casi di vertigine post-trauma cranico.

PAROLE CHIAVE: *Vertigine nell'infanzia • Vertigine parossistica benigna dell'infanzia • Trauma cranico • Algoritmo diagnostico • Vertigine emicranica*

Acta Otorhinolaryngol Ital 2015;35:180-185

Introduction

Vertigo is relatively rare in childhood, in contrast to adults; an erroneous perception of movement can be due, in the child as in the adult, to an anomaly in the normal function of the three major sensory systems that supply this information: the visual system, vestibular system, and somatosensory system. The main epidemiological studies demonstrate a prevalence of dizziness during childhood

from 0.45 to 15%¹⁻⁶; this wide range is obviously related to differences in study design, method of data collection, and inclusion and exclusion criteria. At the same time, a remarkable disparity between children and adults regarding different pathologies is noticeable underlined: in example, benign paroxysmal positional vertigo (BPPV) is the most frequent cause of vertigo in adults, but is not common in children^{4,6,7}. These aspects explain why the prevalence of different pathologies appears to change dramatically as the

child's age increases (i.e. somatoform disorder and vestibular migraine are more common in adolescence than in younger children)⁷. A recent review analysed 9 studies (724 subjects) confirming that benign paroxysmal vertigo (BPV) (15.68%), vestibular migraine (VM) (27.82%), vestibular neuritis (VN) (9.81%) and psychogenic disorders (8.28%) are the most frequent causes of vertigo, while Menière's Disease (MD), BPPV and orthostatic hypotension are rare in childhood⁸.

However, prevalence studies may be affected by several variables: firstly, the child often may find it difficult to exactly describe the dizzy symptomatology (true vertigo, unsteadiness, imbalance, light-headedness) and, because of this, any complaint of dizziness should be considered in the broad context of the dizzy child for diagnostic purposes; secondly, some peripheral vestibular disorders may be very short-lived because of rapid and early compensation; finally, balance disorders in children can appear with various features and lead to delays in postural-motor control development and recurrent falls. Furthermore, vertigo in children constantly creates a profound sense of anxiety both in parents and physicians leading to an excessive number of prescriptions for functional testing and imaging examinations that are often unsuitable for a proper therapeutic approach.

In this paper, we present our series of paediatric patients, with particular attention given to clinical aspects and diagnostic challenges. The aim of this study is to analyse, after clinical experience (a series of patients with established diagnoses) and review of the literature, all relevant anamnestic features in order to propose a simple diagnostic algorithm for vertigo in childhood. This proposed algorithm can be easily employed before starting clinical and instrumental examination.

Materials and methods

This study is a retrospective chart review. Our series of patients was obtained applying a filter by age to our digital archive (Microsoft Access[®] – Microsoft[®]), starting from January 2011 to December 2013. Of 591 patients, 37 children were enrolled for our study. With the aim to include all types of pathologies causing dizziness, no true exclusion criteria were applied: only patients with established neurological disorders or genetic diseases were excluded. The database contained all clinical data regarding age at first visit, type and number of vertigo spells, associated symptoms and general health problems. All patients underwent a complete bedside otoneurological examination (search for spontaneous, positional nystagmus, head shaking test and head impulse test were performed). The Dix-Hallpike test was used to detect a positioning nystagmus. Ocular movements examination (horizontal and vertical eye movements, horizontal and vertical gaze tests, smooth pursuit, saccades) was performed with a software-guided infrared eye-tracking system (HORTMANN Vestlab 100 - Vide-

onystagmography System[®], GN Otometrics[®], Taastrup, Denmark). Bithermal caloric test was performed with the Fitzgerald-Hallpike parameters: 125 cc of water (44°C for the hot stimulus and 30°C for the cold stimulus) administered in the outer ear canal within 30 sec; canal paresis (CP) was considered significant if > 25%. Vestibular evoked myogenic potentials (VEMPs) were performed with a binaural air-conducted 500 Hz filtered tone burst (MK12, Amplifon[®], Milan, Italy) decreasing from 130 dB SPL to 110 dB SPL and detected on the sternocleidomastoid muscle (cVEMPs). The Romberg and Unterberger tests with and without vision were used to clinically assess postural control and gait. Static posturography was performed with a force platform using dedicated software. BPV and paroxysmal torticollis (PT) were diagnosed according with the International Headache Society (ICHD-III beta) diagnostic criteria⁹. The 1995 Committee on Hearing and Equilibrium guidelines for the diagnosis and evaluation of therapy in Menière's disease (MD)¹⁰ were employed to classify MD. A "definite" or "possible" vestibular migraine (VM) was diagnosed according to the revised HIS criteria¹¹ and more recently to the 2012 Barany Society classification¹². The ICD-10 criteria were applied (together with psychiatrists) to diagnose somatoform vertigo. Chronic subjective dizziness was diagnosed according to the Mayo Clinic criteria¹³. Audiological assessment through tympanometry and pure tone audiometry was performed in the majority of cases. Further tests such as auditory brainstem response (ABR), electroencephalography (EEG), computerised tomography and MRI scan of the brain were carried out where indicated (patients in which a migraineous origin of the dizziness was suspected are usually referred by us to the neurology clinic to exclude central pathologies).

Results

The cohort included 37 children and adolescents, 21 males (age range 1-17, mean age 12.1 years) and 16 females (age range 8-16, mean age 13.4 years). Family history for migraine was found in 18 patients (48%). One 16-year-old girl was on medication (anxiolytic) and was referred to us by the Psychiatry Unit. Panic disorder (PD) and generalised anxiety disorder (GDA) were already diagnosed in 1 and 2 subjects, respectively. Two patients suffered from febrile seizures. Two children suffered from head trauma approximately 1 month before. Of the 37 cases, 16 were reported to suffer from headaches.

Eye movement examination was reliable in 31 patients and showed mildly broken smooth pursuits in 6 VM patients and a typical positional paroxysmal nystagmus in one child; no spontaneous nystagmus was detected in any case, and no abnormalities of the saccades or during doll's eyes manoeuvres were found. A head shaking nystagmus was present in 3 cases; clinical head impulse test (cHIT) was reliable and clearly positive in 3 patients.

The bithermal caloric test was performed in 33 patients and showed a significant CP in 6 patients affected by VN (5 unilateral, 1 bilateral), while 5 cases (suffering from migraine) showed asymmetry of the caloric response that was not classifiable as a clear CP according to Jongkees' formulae. Since we consider that audiological assessment is a key point in the evaluation of a dizzy child, tympanometry and pure tone audiometry was performed in 35 of 37 patients. In the majority of cases tests were within normal limits, while in 5 cases some audiological abnormalities were found: in 2 cases hearing loss affected unilaterally of low frequencies and in 2 cases it involved high frequencies (1 case unilaterally, 1 case bilaterally); 1 patient, diagnosed with homolateral delayed endolymphatic hydrops (DEH), reported the onset of deep sudden sensoryneural hearing loss 9 years before. Posturography was performed in 32 patients and was pathological in 4 cases. VEMPs were performed in 33 patients and were evocable in 29 (78%): the presence of chronic middle ear effusion was excluded.

The most common aetiology for dizziness was vestibular migraine (14 patients, 38%), followed by acute labyrinthitis/neuritis (6 patients, 16%) and somatoform vertigo (6 patients, 16%). According to IHS criteria for childhood periodic syndromes, BPV was diagnosed in 4 patients (corresponding to 11%) and paroxysmal torticollis was diagnosed in a 1-year-old child.

As expected, the mean age of the group with vestibular migraine was older (13.6 years) than that of the children with BPV or PT (7 years). In 3 patients, the dizziness had a post-traumatic origin: in 1 case we diagnosed a BPPV (typical paroxysmal nystagmus) and in 2 patients dizziness was caused by labyrinthine concussion. According to

AAO-HNS criteria, there were 2 cases (5%) of MD, one of which was homolateral DEH. In the latter case, a bilateral vestibular failure of unknown origin caused chronic dizziness in an 8-year-old child. No MRI abnormalities of the brain or the inner ear were found in our series. The diagnoses are summarised in Figure 1.

Discussion

Vertigo in childhood is often characterised by nuanced and short-lasting symptoms. Furthermore, some aspects of the pathology, such as gait disorders or balance alterations, can be attributed to mild problems of coordination or small delays in the motor development (motor milestones). In addition, in our clinical experience, children are often treated at the same time by different types of specialists including paediatricians, psychiatrists, neurologists, otolaryngologists and ophthalmologists. Moreover, the considerable neural plasticity in childhood justifies a better tolerability to vertigo with shorter duration of symptoms and a relatively self-limiting nature of the syndrome compared with adults. Nevertheless, vertigo in children must be given adequate consideration since it can be the only symptom of a broad spectrum of diseases, including central nervous system neoplasms or malformations of the inner ear. Vertigo and dizziness, especially in childhood, can produce an excessive number of prescriptions for useless and expensive testing without obtaining any help in therapeutic decision-making. This is often due to the anxiety resulting from a lack of knowledge; a clear diagnostic protocol or algorithm is also missing.

Vestibular migraine, BPV, VN and somatoform vertigo are the most common causes of vertigo in children^{7 8 14}. Several studies show some differences regarding the prevalence of the single pathologies causing dizziness (CSD and somatoform vertigo are often underestimated), but the majority of authors agree that BPPV and MD are infrequent causes of vertigo in children^{7 15}; on the other hand, others believe that the incidence of MD in children might be underestimated¹⁶, but the overlapping symptomatology between MD and VM could explain this discrepancies. Some vestibular manifestations can appear while getting up in the morning or lying down on the bed, suggesting positional paroxysmal vertigo or orthostatic hypotension. In our series, BPPV was diagnosed in only one case (post-traumatic BPPV after a minor head injury); only two girls reported symptoms suggesting orthostatic hypotension, but no drop in blood pressure was detected. However, vestibular migraine and somatoform vertigo are quite common in children and are often associated, especially in females: in a recent study, the prevalence rate for somatoform disorder in children and adolescents was 2.5% based on ICD 10 criteria, whereas the rest of the psychogenic causes were depression, panic disorder and obsessive-compulsive disorder¹⁷. CSD is now defined as a psychiatric disorder that has 3 features: (1) persistent non-vertiginous dizziness lasting

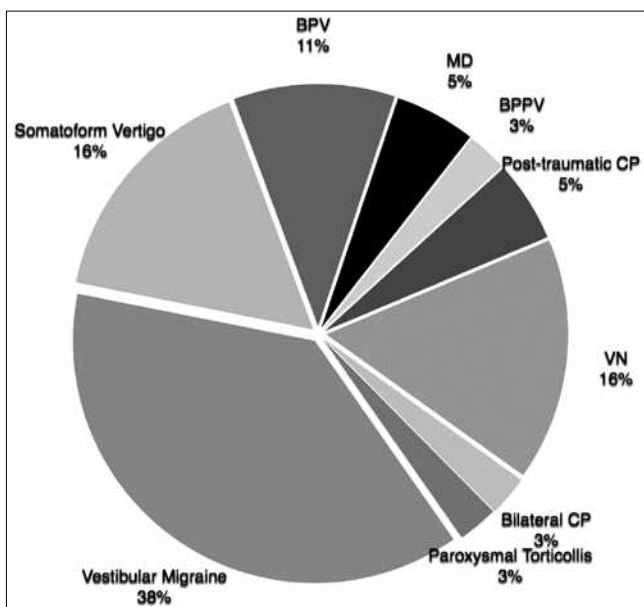


Fig. 1. Frequency of vertigo syndrome in children. CP: canal paresis; VN: vestibular neuritis; BPPV: benign paroxysmal positional vertigo; BPV: benign paroxysmal vertigo; MD: Menière's disease.

3 months or more; (2) hypersensitivity to motion stimuli; (3) difficulty with precision visual tasks; patients may also give histories of past episodes of vertigo, suggesting that a pre-existing vestibular disorder could act as a triggering event¹³. A typical VM vertigo attack is characterised by rotatory vertigo lasting minutes to hours and followed or accompanied by headache and sensitivity to light and noise. In children as in adults, vestibular symptoms of migraine may be precritical, critical and postcritical (respectively before, during and after vestibular symptoms)¹⁸. Motion sickness, even associated with labyrinthine hyperaesthesia is an important characteristic of the child with migraine¹⁹. BPV in childhood is defined as a heterogeneous disorder that is characterised by recurrent brief episodic attacks of vertigo occurring without warning and resolving spontaneously in otherwise healthy children; it is part of the “Childhood Periodic Syndromes” and is now considered as a migraine precursor^{9,20}. Marcelli et al. reported either peripheral or central vestibular findings (spontaneous-positional nystagmus, post head-shaking nystagmus, BPPV, vibration-induced nystagmus, absence of vestibular evoked myo-

genic potentials) in 73% of VM patients¹⁸. In our series, a slight canal paresis was documented in 5 (35%) cases and central ocular findings (broken pursuits) in 6 (42%) of the VM patients. Only 1 of the VM patients had non-evocable cVEMPs. In 10% of cases aged 5 or 6 years, the dizziness seems to be caused by visual problems²¹; in our series, no visual problems were observed (only one child was sent to the ophthalmologist because of a squint). In case of multiple short attacks of rotatory vertigo, diagnosis of vestibular paroxysmia should be considered; in our series, no MRI findings suggesting a neuromuscular conflict with the 8th nerve were reported²².

An excessive number of MRI (or CT) scans is often performed in vertiginous children: this is probably due to poor knowledge and/or to medico-legal motivations. These scans seem to be negative in 57% of all cases and positive in the majority of patients (83%), but only where neurological signs were detected during anamnesis or clinical examination³.

In order to provide better clinical orientation, we propose a diagnostic algorithm based on the clinical history that

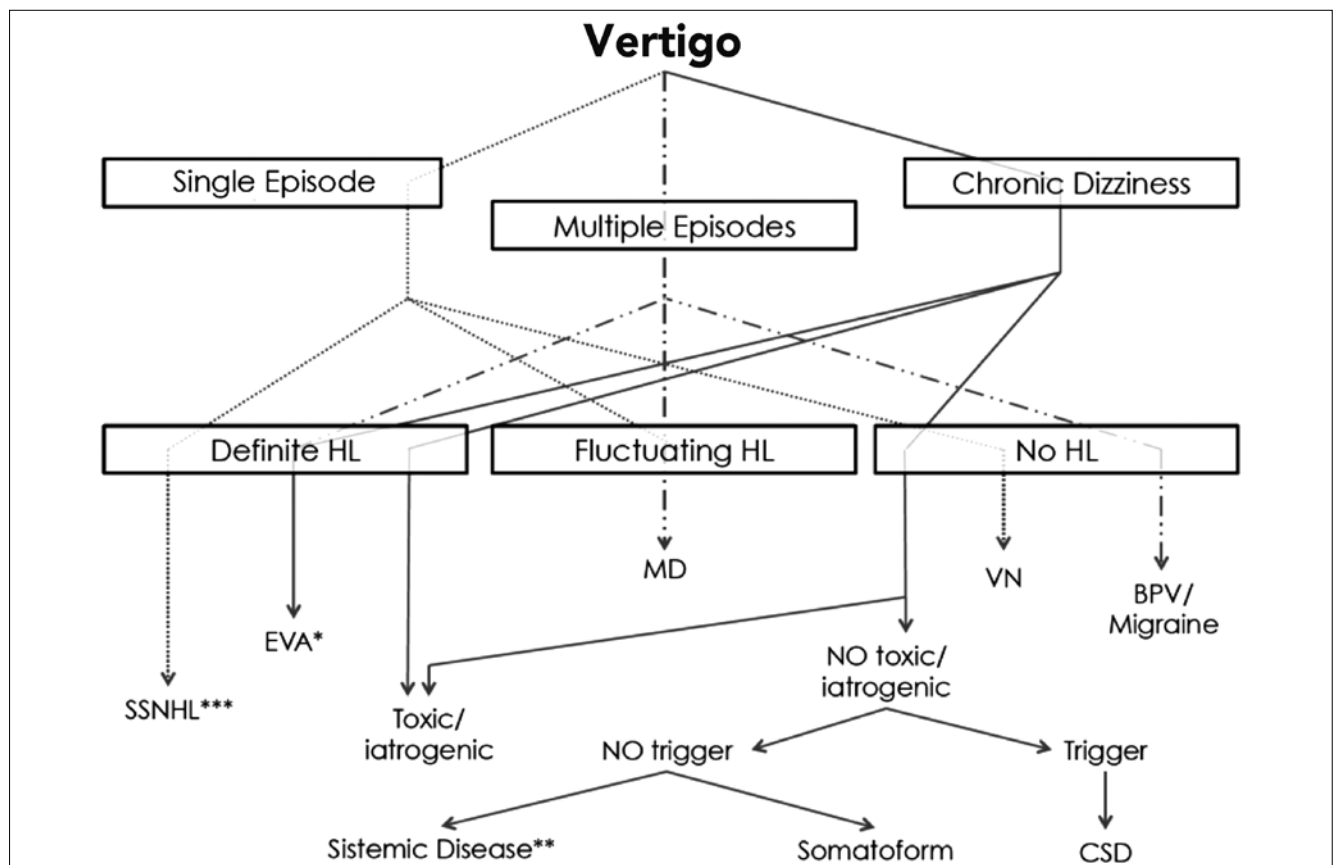


Fig. 2. Diagnostic algorithm for paediatric vertigo based on clinical history; the two main checkpoints of the anamnesis should consider temporal features (number of acute episodes/chronic dizziness) and hearing impairment. BPPV: benign paroxysmal positional vertigo; CSD: chronic subjective dizziness; SSNHL: sudden sensory-neural hearing loss; EVA: enlarged vestibular aqueduct; MD: Menière's disease; trigger: single or multiple event causing development of CSD; VN: vestibular neuritis; BPV: benign paroxysmal vertigo; HL: hearing loss; * includes genetic syndromes and inner ear malformations; ** diabetes, hypothyroidism, electrolytic disturbances; *** a vascular cause should also be considered (heart malformations).

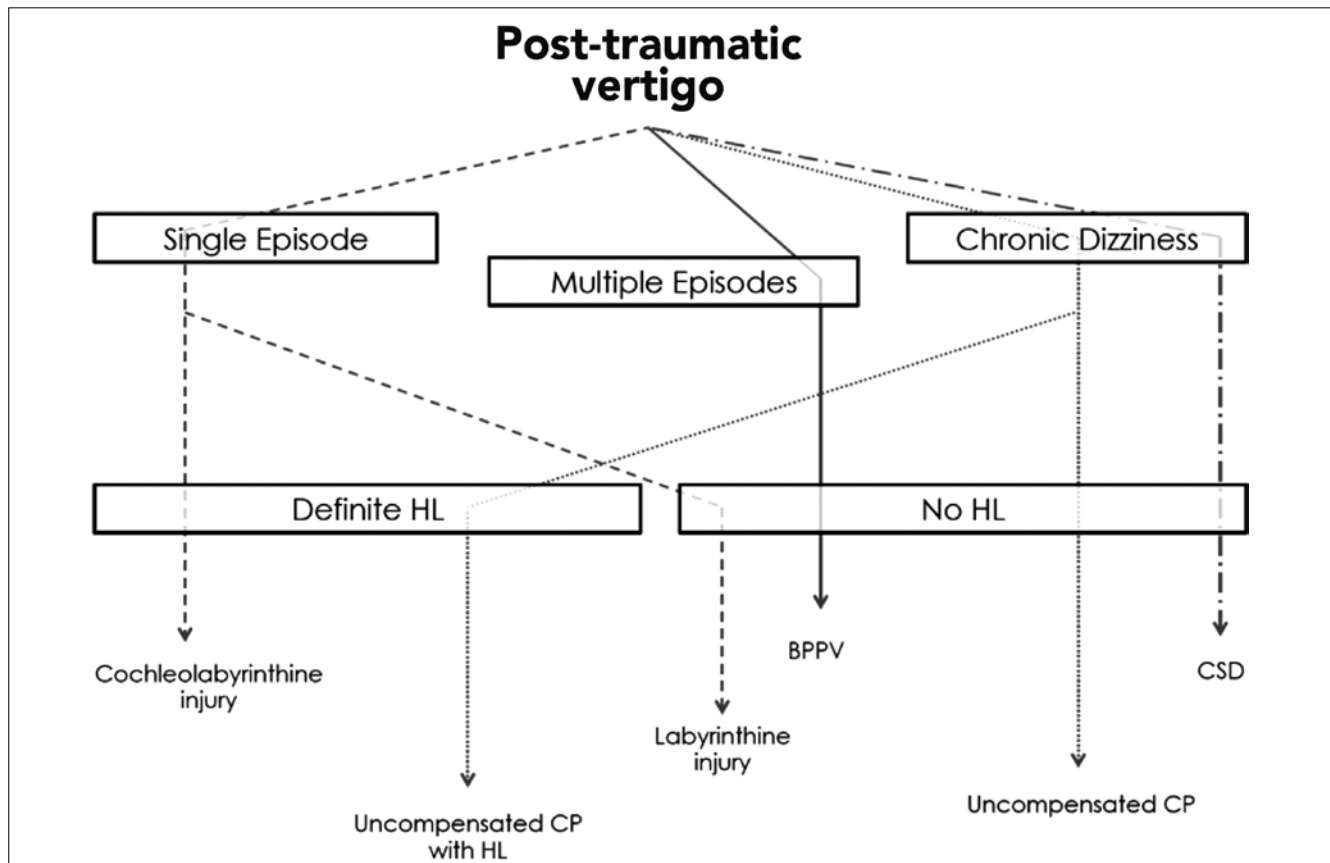


Fig. 3. Diagnostic algorithm based on anamnesis for post-traumatic complaints of dizziness. CP: canal paresis; BPPV: benign paroxysmal positional vertigo; CSD: chronic subjective dizziness; HL: hearing loss.

can be employed in all young dizzy patients (without neurological signs and/or loss of consciousness). On the basis of both literature and clinical experience, we retain that a diagnostic algorithm could be based mainly on two aspects of early clinical investigation: temporal features (number of acute episodes/chronic dizziness) and presence (or absence) of hearing loss (HL) (Figs. 2, 3). Separate considerations should be made for cases in which a traumatic origin is supposed; for this reason a different algorithm, leading to different diagnoses (such as post-traumatic BPPV or cochlear-labyrinthine concussion), has been proposed (Fig. 3). We underline the importance of considering psychogenic disturbances as important causes of chronic dizziness: symptoms should be checked basing on the CSD diagnostic criteria, taking in account any previous disease (or acute event) acting as a trigger. Before that, an iatrogenic origin should be excluded (Fig. 2). In this study the employment of the algorithm provided a diagnosis that has been compared with specific diagnostic criteria and with a negative brain scan.

This study has the following limitations: (1) the video-HIT device was available only for the last two years and was not used in all patients; (2) this is a retrospective chart review suggesting a diagnostic algorithm that must be validated.

Conclusions

We retain that this algorithm will be a good method for guiding diagnosis in dizzy children where no neurological findings are detectable: the algorithm has only few simple steps and does not require any medical device, helping the clinician to distinguish the symptoms and guide clinical suspicion to a correct diagnostic assessment. Further investigations (preferably prospective and controlled studies) are required to confirm its reliability in reducing the number of MRI scans in cases in which a clear diagnosis is not reached.

References

- ¹ Russell G, Abu-Arafah I. *Paroxysmal vertigo in children: an epidemiological study*. Int J Pediatr Otorhinolaryngol 1999;49(Suppl 1):105-9.
- ² Bower CM, Cotton RT. *The spectrum of vertigo in children*. Arch Otolaryngol Head Neck Surg 1995;121:911-5.
- ³ Niemensivu R, Pyykkö I, Kentala E. *Vertigo and imbalance in children: a retrospective study in a Helsinki University otorhinolaryngology clinic*. Arch. Otolaryngol Head Neck Surg 2005;131:996-1000.
- ⁴ Balatsouras DG, Kaberos A, Assimakopoulos D, et al. *Etiology of vertigo in children*. Int J Pediatr Otorhinolaryngol 2007;71:487-94.

- ⁵ Wiener-Vacher SR. *Vestibular disorders in children*. Int J Audiol 2008;47:578-83.
- ⁶ O'Reilly RC, Morlet T, Nicholas BD, et al. *Prevalence of vestibular and balance disorders in children*. Otol Neurotol 2010;31:1441-4.
- ⁷ Jahn K, Langhagen T, Schroeder AS, et al. *Vertigo and dizziness in childhood – update on diagnosis and treatment*. Neuropediatrics 2011;42:129-34.
- ⁸ Gioacchini FM, Alicandri-Ciuffelli M, Kaleci S, et al. *Prevalence and diagnosis of vestibular disorders in children: a review*. Int J Pediatr Otorhinolaryngol 2014;78:718-24.
- ⁹ Headache Classification Committee. *The international classification of headache disorders, cranial neuralgia and facial pain*. 2nd edition. Cephalalgia 2004;24(Suppl 1):1-160.
- ¹⁰ Committee on Hearing and Equilibrium guidelines for the diagnosis and evaluation of therapy in Menière's disease. Otolaryngol Head Neck Surg. 1995;113:181-5.
- ¹¹ Pakalnis A. *Pediatric migraine: new diagnostic strategies and treatment options*. Expert Rev Neurother 2006;6: 291-6.
- ¹² Lempert T, Olesen J, Furman J, et al. *Vestibular migraine: diagnostic criteria. Consensus document of the Barany Society and the International Headache Society*. J Vest Res 2012;22:167-72.
- ¹³ Ruckenstein MJ, Staab JP. *Chronic subjective dizziness*. Otolaryngol Clin N Am 2009;42:71-7.
- ¹⁴ Szirmai A. *Vestibular disorders in childhood and adolescents*. Eur Arch Otorhinolaryngol 2010;267:1801-4.
- ¹⁵ Gruber M, Cohen-Kerem R, Kaminer M, et al. *Vertigo in children and adolescents: characteristics and outcome*. Sci World J 2012;2012:109624.
- ¹⁶ Miyahara M, Hirayama M, Yuta A, et al. *Too young to talk of vertigo?* Lancet 2009;373:516.
- ¹⁷ Langhagen T, Schroeder AS, Rettinger N, et al. *Migraine-related vertigo and somatoform vertigo frequently occur in children and are often associated*. Neuropediatrics 2013;44:55-8.
- ¹⁸ Marcelli V, Furia T, Marciano E. *Vestibular pathways involvement in children with migraine: a neuro-otological study*. Headache 2010;50:71-6.
- ¹⁹ Szirmai Á, Farkas V. *Vestibular disorders in migrainous children and adolescents*. J Headache Pain 2000;1:39-42.
- ²⁰ Marcelli V, Russo A, Cristiano E, et al. *Benign paroxysmal vertigo of childhood: a 10-year observational follow-up*. Cephalalgia 2015;35:538-44.
- ²¹ Anoh-Tanon MJ, Brémond-Gignac D, Wiener-Vacher S. *Vertigo is an underestimated symptom of ocular disorders: dizzy children do not always need MRI*. Pediatr Neurol 2000;23:49-53.
- ²² Lehnen N, Langhagen T, Heinen F, et al. *Vestibular paroxysmia in children: a treatable cause of short vertigo attacks*. Dev Med Child Neurol 2014;22:1-4.

Received: October 20, 2014 - Accepted: February 3, 2015

OTOLOGY

Osseointegrated implants in patients with auricular defects: a case series study

Correzione di difetti del padiglione auricolare mediante epitesi fissate con impianti osteointegrati: casistica personale

E. MEVIO¹, L. FACCA², M. MULLACE¹, M. SBROCCA¹, E. GORINI¹, L. ARTESI¹, N. MEVIO¹

¹ Department of Otorhinolaryngology, Fornaroli Hospital, Magenta, Italy; ² F&S prosthesis workshop, Ariccia, Roma, Italy

RIASSUNTO

Several surgical solutions have been proposed for reconstruction of the auricle in patients whose ear is missing as a result of a traumatic accident, cancer resection, or a congenital condition. These include insertion of an autogenous rib cartilage framework or a porous polymeric material into an expanded postauricular pocket. Reconstruction with rib cartilage has given good results, but requires more than one surgical step and adverse events can occur at both the donor and acceptor site, while cases of prosthesis rejection have been described following application of polymeric prostheses with the expanded postauricular pocket technique. The use of a titanium dowel-retained silicone prosthetic pinna, fixed to temporal bone, has recently been proposed. This surgical technique is particularly indicated after resection of the pinna in cancer patients and in cases of traumatic auricular injury. Bone-anchored titanium implants provided the 15 patients in this study with a safe, reliable, adhesive-free method of anchoring auricular prostheses. The prostheses allowed recovery of normal appearance and all patients were completely satisfied with their reconstructions. No surgical complications, implant failures, or prosthetic failures were encountered.

KEY WORDS: Epithesis • Pinna defects • Osseointegrated implants

RIASSUNTO

Negli anni sono state proposte differenti tecniche chirurgiche per pazienti che presentavano alterazioni del padiglione auricolare in seguito a traumatismi accidentali con amputazione parziale o totale, resezioni per patologia neoplastica e malformazioni congenite. Tali soluzioni tecniche prevedevano l'inserimento di cartilagine costale autologa modellata o di materiali polimerici porosi posizionati in una tasca di espansione retroauricolare. La tecnica ricostruttiva mediante cartilagine costale ha dato buoni risultati, ma richiede più tempi chirurgici e possono inoltre verificarsi effetti collaterali sia a livello del sito di prelievo della cartilagine (sito donatore) sia a livello del sito ricevente. Mentre l'impiego di protesi costituite da materiali polimerici presenta un'alta percentuale di casi di rigetto a livello della tasca retroauricolare. Recentemente è stato proposto l'uso di una protesi del padiglione auricolare in silicone ancorata mediante pilastri in titanio, fissati all'osso temporale. Questa tecnica chirurgica è indicata in particolare dopo la resezione del padiglione auricolare nei casi di lesione traumatica auricolare o in pazienti oncologici. Sono stati trattati con impianti in titanio osteointegrati 15 pazienti. La metodica si è rivelata affidabile e sicura. La applicazione della protesi risulta più gradevole e più stabile perché grazie al sistema di impianti osteointegrati non è necessario l'utilizzo di adesivi di ancoraggio. Le protesi hanno consentito un ottimo risultato estetico e tutti i pazienti si sono dichiarati completamente soddisfatti. Non si sono verificate complicazioni chirurgiche né nella fase di preparazione né di applicazione delle protesi.

PAROLE CHIAVE: Epitesi • Patologia del padiglione auricolare • Impianti osteointegrati

Acta Otorhinolaryngol Ital 2015;35:186-190

Introduction

Absence of the pinna may be a congenital defect (microtia or anotia) or a condition acquired as a result of infection, cancer surgery, or traumatic injury. In the first case, it may be associated with malformations of the auditory canal, middle ear and inner ear. Whatever the cause, absence of the ear is a considerable aesthetic problem, which can often cause the patient severe psychological distress.

The defect can be repaired through reconstructive plastic surgery, which involves insertion, under the skin, of either an autogenous rib cartilage framework or a prosthesis made

of synthetic material. Alternatively, it is possible to use an auricular epithesis (prosthetic ear). Initially, these epitheses were held in place by adhesives which, however, gave poor results in terms of stability and were often associated with skin irritations. Now, however, there exists an excellent and innovative surgical technique allowing fixation of ear epitheses by bone-anchored titanium implants. Basically, this approach is an evolution of implants for dental prostheses proposed by Branemark in 1969 – used for 40 years in the field of odontostomatology – which the same author subsequently re-proposed as percutaneous craniofacial implants for use with bone conduction hearing aids^{1,2}.

The authors of the present paper describe their experience using these pinna prostheses in 15 patients and discuss the technique, also in the light of the most recent scientific literature.

Materials and methods

Case series: Our case series is composed of 15 patients (14 males and 1 female with a mean age of 28.06 years, range 16-56 years) (Table I). The aetiology was congenital in 10 patients (Fig. 1), who were affected by microtia, while the remaining 5 had post-traumatic mutilation (Fig. 2). Three of the patients with microtia (Fig. 3) and two of the patients affected by traumatic mutilation had previously undergone plastic reconstructive surgery with rib cartilage grafting and were not satisfied with the results. These patients wanted their previously reconstructed ear removed and replaced with an epithesis. One patient had previously undergone canaloplasty of the right external auditory meatus. None of the patients had comorbidities. The follow-up period ranged from 5 months to 2 years. After 6 weeks, all implants were osseointegrated and a retentive bar was fixed to the abutments.

The patients with microtia were offered the option of undergoing bone-anchored hearing aid (BAHA) implantation at the same time as the auricular rehabilitation with bone-anchored epitheses, but all declined, preferring to keep this as a possible option for a later stage.

Surgical procedure: Before the surgical field is prepared, and with the patient's face still fully and easily visible, the implant sites should be carefully marked, using methylene blue, down to the bone.

Two implants are normally sufficient for satisfactory retention. These are ideally placed approximately 20 mm from the centre of the external auditory canal opening or anticipated opening. They are positioned at 8 o'clock and 10:30 on the right side, and at 4 o'clock and 1:30 on the

left side. In the presence of a complete malformation, the supposed location of the external auditory canal is determined by considering a triangle traced on the contralateral hemiface using the following references: the line between the lateral canthus and the auditory canal, the line between the auditory canal and the labial commissure, and the angle formed by these two lines (Figs. 1-5).

We usually perform one-stage surgery, removing tags and remnants in cases of microtia and performing the necessary subcutaneous tissue reduction.

The one-stage surgical procedure can be used in adults to treat auricular defects involving non-irradiated tissue; the two-stage technique should usually be chosen for paediatric patients, and for the treatment of orbital and midface defects, and auricular defects in patients with poor bone quality³.

An incision is made 10 mm behind the anticipated implant site. Dissection is performed down to the periosteum. A cruciate incision is then performed at each implant site. The edges are raised with a raspatory.

Drilling begins using the guide drill with the spacer kept on 3 mm. Irrigation should be used during drilling. The bottom of the hole is repeatedly checked for bone at the base of the site. If there is adequate bone thickness drilling continues to a depth of 4 mm. The drill indicator will facilitate correct drill orientation. The next step is to widen the hole to the exact diameter using a 3 or 4 mm drill countersink. Irrigation should be guaranteed.

At this point, implant installation is performed. The low speed setting should be used for implant insertion. In compact cortical bone a torque setting of 40 Ncm is recommended, whereas, in soft bone a lower torque setting of 20 N-cm should be used.

The self-tapping fixture with the premounted fixture mount is seated inside the plastic ampoule in a titanium cylinder. It is then picked up with the connection to the handpiece, which is placed into the drill handpiece.

Table I. Characteristics of patients in the present study.

	Name	Age	Sex	Side	Disease	Previous Surgery
1	BG	17	M	Left	Traumatic mutilation	None
2	LC	25	M	Right	Grade III microtia	Plastic reconstruction
3	MI	17	M	Right	Grade III microtia	None
4	JA	34	M	Left	Traumatic mutilation	Plastic reconstruction
5	AB	44	M	Left	Grade III microtia	Plastic reconstruction
6	NM	38	M	Right	Grade III microtia	None
7	SM	16	M	Right	Grade III microtia	None
8	DM	37	M	Right	Grade III microtia	Plastic reconstruction
9	LVS	19	M	Left	Grade III microtia	None
10	MB	22	F	Right	Grade III microtia	None
11	CN	19	M	Right	Grade III microtia	None
12	RG	26	M	Left	Traumatic mutilation	Vistafix implant
13	VS	56	M	Right	Traumatic mutilation	None
14	FA	27	M	Right	Traumatic mutilation	Plastic reconstruction
15	GC	24	M	Right	Grade III microtia	Canaloplasty



Fig. 1. Grade III microtia, right ear: preoperative image in 3/4 right projection (left); postoperative image with prosthesis secured in position (right).

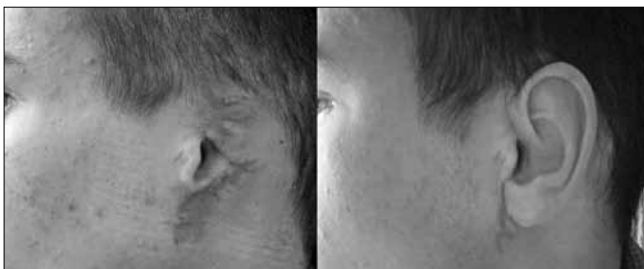

Fig. 2. Mutilation of the left auricular pinna caused by a traumatic accident. On the right: episthesis attached to a gold-platinum cylinder-and-bar system.

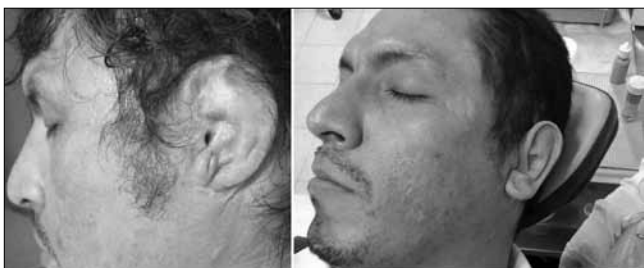

Fig. 3. Auricular rehabilitation (rib cartilage reconstruction performed elsewhere) in a patient with microtia. The patient was not satisfied with the previous reconstruction, which was removed and replaced with an episthesis (right).

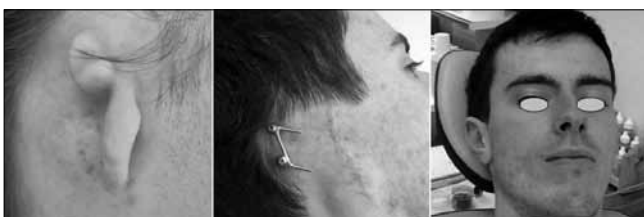

Fig. 4. A. Preoperative image of grade III microtia, right ear (left). Gold bar attached to two titanium implants (middle). Prosthetic pinna in place, clipped onto the gold bar (right).

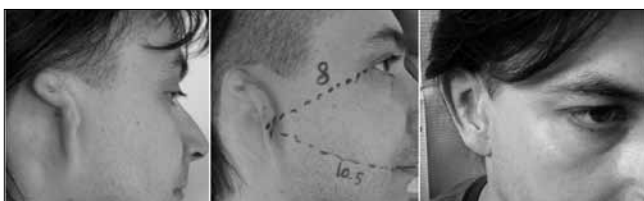

Fig. 5. Grade III microtia, right ear. The central image shows preoperative identification of the position of the external acoustic meatus on the basis of the distance of the contralateral meatus from, respectively, the lateral canthus and the labial commissure. On the right, the patient after treatment.

The implant is installed without cooling irrigation until the small grooves at the distal end of the implant are well within the canal. When the flange of the implant has seated, the handpiece will automatically stop.

The mount is removed using the Unigrip screwdriver and surgical wrench. The titanium standard abutment is picked up with the abutment holder and placed into the implant. We perform manual tightening, using the abutment screw, to 25 N-cm.

The skin is then repositioned over the implants. Holes are punched through the skin exactly over abutments with a biopsy punch. The skin is then sutured. Healing caps are positioned on the abutments.

A gauze dressing is applied in a figure of 8 (foam dressing, soft silicone wound contact layer or antiseptic dressing). The healing caps are thus held in place. All patients were discharged the day after surgery and were revised for the first dressing after 7 days. The patients underwent dressings every 7 days for a month.

It is important to wait 6 weeks before loading the implants. Following healing and stabilisation of the surgical site, the patient is sent to the anaplastology technician who will prepare the episthesis, modelling it on the contralateral ear and carefully matching the skin colour (Fig. 4, right). The silicone episthesis is created using a wax pattern. The definitive one has two sides: the inner one in an acrylic plate with clips that allow the attachment to a gold-platinum bar fixed to the abutments; the external one is made of soft silicone. Patients receive two epitheses of different colours: a pale one for winter and a tanned one for summer.

When the process of osseointegration is complete, the prosthesis, which has clips, is easily and securely attached to or removed from the gold-platinum cylinder-and-bar system (Fig. 4, middle).

Patients were evaluated for quality of life in the week before pinna reconstruction (T0) with the Short Form Health Survey (SF-12)⁴. Assessments were repeated after 3 months (T1). Statistical analysis was performed with Pearson correlations and the results were considered significant when $p \leq 0.05$.

Discussion

Absence of the ear (congenital or resulting from trauma or surgery) is a defect that can be resolved through reconstructive plastic surgery. This involves the insertion of either an autogenous rib cartilage framework or a prosthesis made from synthetic material into a subcutaneous pocket behind the ear, obtained through tissue expansion. A more recent technique is the use of epitheses made from synthetic material and secured by adhesives to the patient's skin. However, auricular reconstruction using rib cartilage has several disadvantages: it requires more than one surgical procedure, complications are very frequent, both at the implant site (infections, bleeding, haematoma, necrosis and skin graft or cartilage graft

exposure) and at the graft site (infections, haematoma, scarring). Moreover, patients are very often dissatisfied with the final outcome because the new ear looks considerably different from the contralateral one^{5,6}.

The use of prostheses made from porous polymer material (Medpore) inserted in subcutaneous pockets, proposed by Wellisz in 1993, is frequently complicated by partial or total rejection and further scarring problems⁷.

Conventional facial prosthetics has previously relied on the use of adhesives for retention. Pitfalls of the adhesive-retained prosthesis include skin irritation from the adhesives, unpredictability of retention, variability of positioning of the prosthesis and poor hygiene attributable to the tackiness of the adhesive as well as decreased life span of the prosthesis resulting in an increased number of remakes⁷.

A valid and excellent alternative is that of bone-anchored implants and application of an auricular epithesis. In this regard, titanium implant systems for bone-anchored hearing aids have shown how such prostheses can be attached safely, securely, reproducibly and without the need for adhesives^{3,8-10}. This procedure is suitable for patients who are unwilling to undergo plastic reconstructive surgery with rib cartilage, a challenging surgical procedure that involves more than one surgical step and is associated with a risk of complications at the donor (thoracic) site and/or the acceptor (implant) site¹¹. The use of osseointegrated implants is also the only possible solution in oncology patients who have previously undergone several surgical procedures and/or radiotherapy¹². Radiotherapy does not constitute a contraindication for this procedure, although implant loss is higher in irradiated sites than in non-irradiated sites. Granstrom reported that the adjunctive use of hyperbaric oxygen could reduce implant loss¹³. It is important to note the low cost of the vistafix implant (€ 1900) and epithesis (€ 2000). Above all, patients expressed their satisfaction regarding the short hospitalisation and reduced invasiveness compared to alternative therapies. Complications associated with this surgical technique are rare (10-15% of cases). Local skin infection around the fixture can occur, as can the formation of granulation tissue and keloids. These are complications that can be avoided or resolved using appropriate medication and topical treatments without loss of the fixture¹⁴.

Absolute contraindications to the use of titanium bone implants in prosthetic reconstruction of the auricle are exceptional and may be local or general conditions (respectively, osteitis and terminal illness or the presence of psychological disorders). Contraindications for general anaesthesia need not preclude use of these implants, since they can be positioned under local anaesthesia. This surgical technique is contraindicated in patients under 14 years of age, whose skull thickness is not sufficient to support the osseointegrated implant. Preoperative evaluation of bone thickness on CT scans should nevertheless be a mandatory part of the surgical planning in adults¹⁵⁻¹⁷.

All the patients in our series underwent one-stage surgery. As mentioned earlier, indications for one-stage surgery are auricular defects, adult patients and non-irradiated tissue, while a two-stage technique should be used in paediatric patients, and to treat orbital and midface defects, as well as auricular defects in patients with poor bone quality³.

None of the patients we treated experienced problems related to the implants (osseointegration failure or wound healing problems).

Conductive hearing loss due to malformations of the external and middle ear, present in all subjects affected by microtia, can be corrected by combining the placement of titanium implants for auricular rehabilitation with implantation of the fixture and abutment for a BAHA. In this way, both the sensory and the aesthetic problems can be resolved in a single operation. However, it should be pointed out that all the patients in our series refused to undergo BAHA implantation after testing the device prior to surgery; these patients, being well accustomed to hearing on only one side, found the increased auditory perception provided by the BAHA disorienting and irritating.

Conclusions

The pinna epithesis fixed with bone-anchored titanium implants technique is characterised by excellent aesthetic outcome and lasting results. All our patients expressed satisfaction with their prosthesis. Statistical analysis between T0 and T1 SF-12 score suggests a significant role in quality of life of patients who underwent pinna reconstruction. They had no adverse psychological reactions and were able to resume their usual physical activities without problems; indeed, thanks to the effectiveness of the anchoring system, the epithesis does not move when the patient exercises.

References

- 1 Brånemark PI, Adell R, Breine U, et al. *Intra-osseous anchorage of dental prostheses. I. Experimental studies*. Scand J Plast Reconstr Surg 1969;3:81-100.
- 2 Brånemark PI, Albrektsson T. *Titanium implants permanently penetrating human skin*. Scand J Plast Reconstr Surg 1982;16:17-21.
- 3 Wazen JJ, Wright R, Hatfield RB, et al. *Auricular rehabilitation with bone-anchored titanium implants*. Laryngoscope 1999;109:523-7.
- 4 Ware J Jr, Kosinski M, Keller SD. *A 12-Item Short-Form Health Survey: construction of scales and preliminary tests of reliability and validity*. Med Care 1996;34:220-33.
- 5 Brent B. *Microtia repair with rib cartilage grafts: a review of personal experience with 1000 cases*. Clin Plast Surg 2002;29:257-71.
- 6 Zhao Y, Wang Y, Zhuang H, et al. *Clinical evaluation of three total ear reconstruction methods*. J Plast Reconstr Aesthet Surg 2009;62:1550-4.

- 7 Wellisz T. *Reconstruction of the burned external ear using a Medpor porous polyethylene pivoting helix framework*. *Plast Reconstr Surg* 1993;91:811-8.
- 8 Tjellström A, Lindström J, Nylén O, et al. *The bone-anchored auricular episthesis*. *Laryngoscope* 1981;91:811-5.
- 9 Westin T, Tjellström A, Hammerlid E, et al. *Long-term study of quality and safety of osseointegration for the retention of auricular prostheses*. *Otolaryngol Head Neck Surg* 1999;121:133-43.
- 10 Federspil PA. *Ear epistheses as an alternative to autogenous reconstruction*. *Facial Plast Surg* 2009;25:190-203.
- 11 Gentile P, Bottini DJ, Gravante G, et al. *The use of bone-anchored implants for absent ear*. *J Craniofac Surg* 2008;19:744-7.
- 12 Wright RF, Zemnick C, Wazen JJ, et al. *Osseointegrated implants and auricular defects: a case series study*. *J Prosthodont* 2008;17:468-75.
- 13 Granström G. *Hyperbaric oxygen therapy decreases the rejection rate of osseointegrated implants after radiotherapy*. *Strahlenther Onkol* 1996;172(Suppl 2):20-1.
- 14 Giot JP, Labbé D, Soubeyrand E, et al. *Prosthetic reconstruction of the auricle: indications, techniques, and results*. *Semin Plast Surg* 2011;25:265-72.
- 15 Gumieiro EH, Dib LL, Jahn RS, et al. *Bone-anchored titanium implants for auricular rehabilitation: Case report and review of literature*. *Sao Paulo Medical Journal* 2009;127:160-5.
- 16 Curi MM, Oliveira MF, Molina G, et al. *Extraoral implants in the rehabilitation of craniofacial defects: implant and prosthesis survival rates and peri-implant soft tissue evaluation*. *J Oral Maxillofac Surg* 2012;70:1551-7.
- 17 Korus LJ, Wong JN, Wilkes GH. *Long-term follow-up of osseointegrated auricular reconstruction*. *Plast Reconstr Surg* 2011;127:630-6.

Received: June 2, 2014 - Accepted June 26, 2014

CLINICAL TECHNIQUES AND TECHNOLOGY

Auricular reconstruction of congenital microtia: personal experience in 225 cases

Ricostruzione auricolare in microtia congenita: esperienza personale in 225 casi

M. ANGHINONI, C. BAILLEUL, A.S. MAGRI

Head and Neck Department, Maxillo-Facial Surgery Division, University Hospital of Parma, Italy

SUMMARY

Microtia is a congenital disease with various degrees of severity, ranging from the presence of rudimentary and malformed vestigial structures to the total absence of the ear (anotia). The complex anatomy of the external ear and the necessity to provide good projection and symmetry make this reconstruction particularly difficult. The aim of this work is to report our surgical technique of microtic ear correction and to analyse the short and long term results. From 2000 to 2013, 210 patients affected by microtia were treated at the Maxillo-Facial Surgery Division, Head and Neck Department, University Hospital of Parma. The patient population consisted of 95 women and 115 men, aged from 7 to 49 years. A total of 225 reconstructions have been performed in two surgical stages basing of Firmin's technique with some modifications and refinements. The first stage consists in fabrication and grafting of a three-dimensional costal cartilage framework. The second stage is performed 5-6 months later: the reconstructed ear is raised up and an additional cartilaginous graft is used to increase its projection. A mastoid fascial flap together with a skin graft are then used to protect the cartilage graft. All reconstructions were performed without any major complication. The results have been considered satisfactory by all patients starting from the first surgical step. Low morbidity, the good results obtained and a high rate of patient satisfaction make our protocol an optimal choice for treatment of microtia. The surgeon's experience and postoperative patient care must be considered as essential aspects of treatment.

KEY WORDS: Ear • Ear reconstruction • Microtia • Auricular reconstruction

RIASSUNTO

La microtia è una malformazione congenita dell'orecchio caratterizzata da diversi gradi di severità sino alla totale assenza di ogni dettaglio riconoscibile (anotia). La complessità anatomica dell'orecchio esterno, nonché la necessità di assicurare una buona proiezione e simmetria con il padiglione auricolare controlaterale, ne rendono la ricostruzione particolarmente complessa. Lo scopo di questo lavoro è di presentare la nostra esperienza nella ricostruzione del padiglione auricolare e di analizzarne il risultato a medio e lungo termine. Dal 2000 al 2013 sono stati trattati 210 pazienti affetti da microtia monolaterale/bilaterale, per un totale di 225 ricostruzioni eseguite in due tempi chirurgici secondo la tecnica di Firmin, con l'apporto di alcune modifiche. Il primo tempo prevede il prelievo di cartilagine costale autologa che viene modellato e innestato. Nel secondo tempo, dopo 5/6 mesi, si realizza il solco retroauricolare con allestimento di lembo di fascia mastoidea e prelievo di cute libera. Il range di età varia da 7 a 49 anni; 115 pazienti sono di sesso maschile e 95 di sesso femminile. Verranno presentati i risultati, le complicanze a breve e a lungo termine, le indicazioni alla ricostruzione e le sue restrizioni. Sin dal primo tempo chirurgico la ricostruzione risulta esteticamente valida. Le limitate complicanze sia a breve che a lungo termine dimostrano la specializzazione del chirurgo e l'importanza di seguire attentamente il protocollo esposto.

PAROLE CHIAVE: Orecchio • Ricostruzione Auricolare • Microtia

Acta Otorhinolaryngol Ital 2015;35:191-197

Introduction

Microtia is a congenital anomaly of the external ear that can present with various degrees of severity from mild structural abnormalities to the complete absence of the external and middle ear. The malformation is characterised by unorganised cartilage remnants and a malpositioned lobule. The complete absence of any kind of external ear remnant is defined as anotia. Lobule displacement is related to the degree of facial hypoplasia, and the simultaneous absence of the auditory canal increases the severity of the anomaly.

The reported prevalence varies among countries from 0.83 to 17.4 per 10,000 births, and is considered to be higher in Hispanics, Asians, Native Americans and Andeans. Males are more often affected than females, the right ear is involved twice as frequently as the left and 70% of cases are unilateral¹. Microtia can occur as an isolated defect or as part of a spectrum of anomalies, especially in a first or second arch syndrome (e.g. Franceschetti-Klein syndrome, hemifacial microsomia, Goldenhar syndrome). Auricular reconstruction is currently one of the most challenging plastic facial procedures because of the

complexity of the three-dimensional shape of the ear and its bilaterality, with the consequent need for symmetrical placement on both sides of the face. In addition, the result depends on the local conditions of the recipient site. Thus, if the region has never been treated, then evaluations of skin mobility in the mastoid region, various depressions in the same area for failure pneumatization of the mastoid cells, low position of the hairline and presence of ectopic remnants should be assessed. Different considerations exist if ear reconstruction has been attempted previously.

The results are often unreliable because many surgeons try to correct these deformities using a variety of techniques, but few have adequate experience. As a consequence, the success rate is frequently low^{2,3}. The principles described by Tanzer⁴ and Brent^{5,6} are mainstays for all surgeons involved in ear reconstruction. They provide a scientific method, which serves as an excellent baseline for developing new ideas, underlining the necessity of a multistep procedure for auricular reconstruction to maximise the benefits of autologous rib grafting.

Various classifications are currently used to describe the microtic vestige of the ear. One of the most cited in the literature is that originally presented by Weerda in 1988⁷ and modified by Aguilar⁸, which describes three degrees of severity. In the first degree, the auricle is anatomically present and normal in shape, but smaller than standard dimensions. In the second degree, the ear is malformed, but some identifiable structures are present. The third degree is classically defined as 'peanut', when the anatomical ear structures are almost completely or completely absent (anotia).

However, in our department, we prefer the classification used by Nagata⁹, who catalogued microtic ears as lobular type and conchal type deformities. The first type is sausage-shaped (comparable with the Aguilar third degree). The second type is characterised by underdevelopment of the lobule, concha, external acoustic meatus, tragus and intertragal incisure. It can be further divided into the small and large conchal subtypes. Moreover, Firmin described specific surgical incisions for each type of malformation¹⁰.

In our department we use a protocol based on an accurate clinical evaluation to obtain reliable results. First, we take into account whether the microtic ear is part of a malformative spectrum or an isolated sign in order to plan the most appropriate surgical procedure. In the former case, the timing must also be considered during planning of the skeletal reconstruction.

Afterwards, to obtain a symmetrical reconstruction, it is important to evaluate the dimensions and position of the uninvolved ear, using it as a model. Taking anthropometric measurements is an important step in the preoperative study of the patient. Various systems have been reported, by Posnik in 1993¹¹ until Firmin in 2001^{3,12}, with different spatial relationships with the nasion and lip commissure

to determine the position of the reconstructed ear, an issue that requires special attention if the most symmetrical reconstruction possible is to be obtained.

Finally, we firmly believe that parental and patient compliance must also be considered. The success of this kind of surgery is related to both the aesthetic result and the cooperation and psychological postsurgical recovery of the patient¹³, based on realistic expectations.

In this article, we discuss the technical features that have allowed us to achieve stable and aesthetically satisfactory results. We will evaluate our approach, issues, implications and suggestions for further refinement of the surgical technique based on our experience.

Clinical technique and technology

During the 13-year period from 2000 to 2013, a total of 210 patients diagnosed with congenital microtia (195 unilateral and 15 bilateral) underwent a total of 225 ear reconstructions in our department. 115 patients were male and 95 were female. The majority of patients were aged 8 to 12 years; the mean age was 15.05 years, with a range from 7 to 49 years. 12 patients had undergone a previous operation at another institution. 127 patients had an associated syndrome: 113 had otomandibular syndrome or Goldenhar syndrome, and 14 had Franceschetti-Klein syndrome.

An X-ray film template was fashioned before reconstruction using the contralateral ear as a model. The desired canting was marked in relation to the nasal dorsum. The distances from the helix to the external cantus and from the lobule to lip commissure are used to achieve a specular position. A two-step auricular reconstruction was planned. During the first stage the ipsilateral costal cartilages are harvested⁹ to construct all anatomical segments. A slight oblique incision is made just above the costal margin, the muscle is divided and the sixth to eighth or ninth ribs are harvested. The cartilage used to construct the helix (8°) is removed with proper superficial and deep perichondrium, while the other ribs are removed leaving the deep perichondrium to permit regeneration and to avoid aesthetic defects in the chest profile. A suction drainage tube is positioned in the superficial layer to prevent haematoma formation, and a deep catheter is placed for infusion of anaesthetic drugs. The cartilage framework, obtained from a base block (sixth and seventh costal cartilages with synchondrosis, taking care to turn the anterior surface upside down to obtain a better profile), is carved to model the anti-helix, scapha and triangular fossa. The three-dimensional framework is then further refined using the film model to accentuate the fine details of the different structures (concha, helix and antihelix) located on different layers.

The various surgical steps have been reported in literature^{3,14} and are not analysed in detail herein. The techniques vary according to the anatomical details of ear shape and projection. To obtain a good reproduction of a

single detail, its projection should be increased over the normal anatomical feature. We often need to overgraft the antihelix using fragments obtained from the cartilage work. More accurate carving of the inner side of the helix is advisable, taking care to reconstruct the helix in one piece to avoid fractures and future distortions. Finally, the tragus and anti-tragus, that surround the intertragal incisure, are modelled.

The cartilage segments are joined using fine stainless steel wire. The unused cartilage is banked in the subcutaneous tissue at the donor site for the second stage of the procedure. Firmin's skin incision¹⁰ in the auricular region is either transfixed or a Z-type at the level of the remnant, respectively, if a typical conchal or lobule type microtia is present. The incision can be extended posteriorly in the mastoid region if it is necessary to transpose the lobule more posteriorly. The entire amorphous cartilage is excised and a cutaneous pocket is dissected with dimensions larger than those of the model for tension-free closure, avoiding the risk of skin necrosis and loss of the definition of cartilage convolutions. Good haemostasis is mandatory to avoid haematoma formation.

The framework is inserted and seated in its appropriate symmetrical position using the prefabricated template. Two vacuum suction drains are placed deep to the concha and around the helix respectively. After skin closure, the anatomical details of the framework are immediately evident with suction (Fig. 1). A non-compressive dressing is applied with paraffin gauze positioned to retain the reconstruction shape. The drains are maintained until the fourth to sixth postoperative day.

The second stage is generally carried out 6 months after the first. The procedure aims to increase the projection of the reconstructed ear and create the retroauricular sul-

cus. A skin incision is performed 3 to 5 mm posteriorly along the entire helix length. It is necessary to remove the hair bulbs present in the superior layer of the helix to improve the aesthetic result and the patient's psychological perception. The ear is elevated to obtain a correct auriculo-mastoid angle, and the cartilage banked in the first step is inserted in a semilunar shape beneath the framework¹⁵ and fixed with nylon stitches. In our first seven cases, the cartilage graft was covered with a superficial temporal fascia and skin graft. After we started to use a mastoid fascia to cover the cartilage graft. Mastoid fascial flap harvesting is performed easily and rapidly. We begin with a curvilinear incision located posteriorly about 3 to 4 cm from the cartilage graft. The dissection is subfascial posteriorly and deepens subperiosteal anteriorly to obtain an anterior pedicle with sufficient random vascularisation.

To decrease the size of the area to be grafted, the skin of the mastoid region is dissected and advanced, removing the hair bulbs, as closely as possible toward the created retroauricular groove. Finally, a skin graft (split-thickness graft harvested from the adjacent scalp) is positioned on the posterior surface of the ear. The graft is sutured in place with multiple quilting sutures to prevent any tenting of the graft itself. The final dressing is made of packed paraffin gauze and a sponge and is kept in place for 1 week.

Complications that occurred after the first stage of the surgery included eight cases of central skin necrosis, all in the first period of our experience. They were treated under local anaesthesia by excision of the necrotic area and primary closure. It was necessary to use a strip of superficial temporal fascia in only two cases. Fifteen cases of partial skin necrosis of the upper helix were treated using a small strip of superficial temporal fascia.

Patients experienced no severe complications, such as pneumothorax or pulmonary atelectasis. In two cases a small pleural lesion was immediately sutured with no postoperative consequences.

The exposure of metal wires, in agreement with the literature, was one of the complications that occurred during long-term follow-up.

After the second stage, neither cartilage exposure nor fascial flap necrosis were seen. In 10 patients, small necrotic areas of the skin grafts were treated with antibiotic ointment and secondary healing.

All patients were followed up after the first stage every day until the 10th postoperative day. Each patient was then seen at intervals of 2 weeks, 1 month, 3 months and 5 months after the operation. After the second stage, patients were followed up every 3 days until the 15th postoperative day, then at intervals of 1 month, 3 months, 6 months, 1 year and yearly after the operation.

At 6 months after the second stage, the results are considered stable as no significant modification have been seen during the successive follow-up.

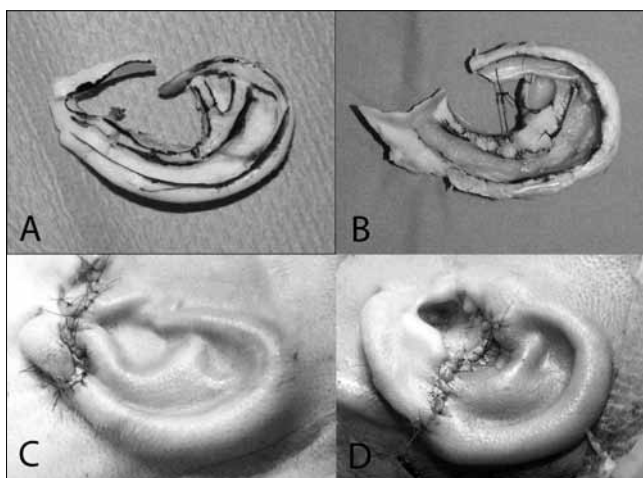


Fig. 1. A: complete framework reproducing all of the contours. B: framework in case of concha-type microtia reproducing all the contours except the tragus and antitragus. C: appearance at the end of the first stage procedure in a case of lobule-type microtia. D: aspect after the first stage procedure in a case of concha-type microtia.

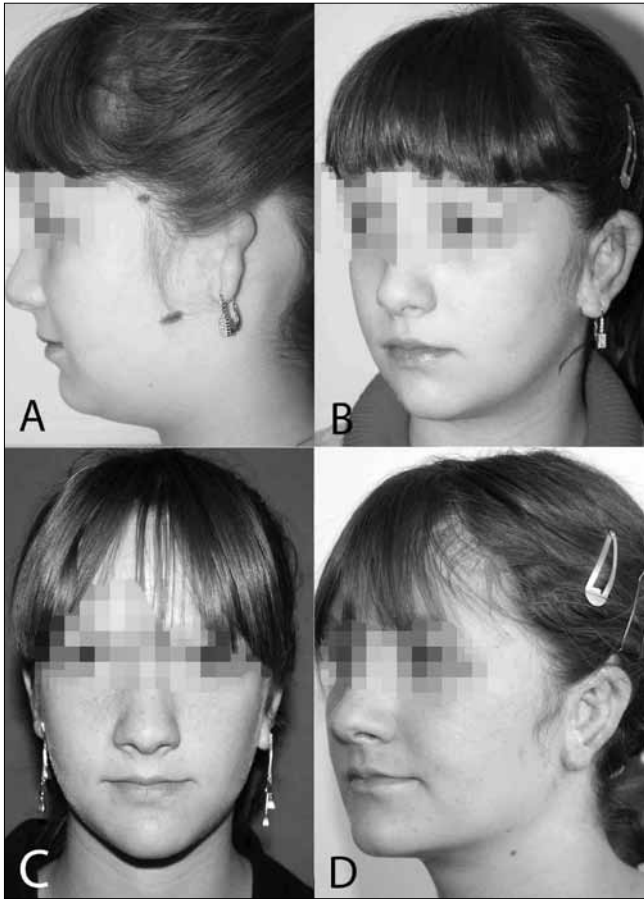


Fig. 2. Case 1. A: preoperative appearance of a lobule-type microtia in a 9-year-old child. B: 1 year after surgery. C: after 3 years. D: after 10 years, we can appreciate the stability of the result.

Figures 2-5 show the final results obtained in 6 patients who underwent the techniques described in this report.

Discussion

The ear is characterised by a complex cartilage anatomy that is covered by a very thin skin; consequently, its surgical reconstruction is difficult.

To complicate this problem, this anatomical structure projects bilaterally and symmetrically from the sides of the face. In recent years, psychological distress associated with aesthetic deformity has been managed using several techniques, as reported by Brent⁵, Nagata¹⁴⁻¹⁷ and Firmin^{10 18}. These authors utilised different reconstructive protocols, although the foundation of all is the placement of a rigid autologous cartilage structure, adequately modelled, under the auricular skin.

Based on the experience of the above-mentioned authors⁶, the use of alloplastic materials (silicone, Medpor®, etc.) does not ensure stable results. These materials are often poorly tolerated, and can cause skin ulcers, infections and extrusions, and are often unable to withstand even small injuries that can occur at any time. Otherwise, the use of homologous cartilage showed a high degree of resorption and distortion

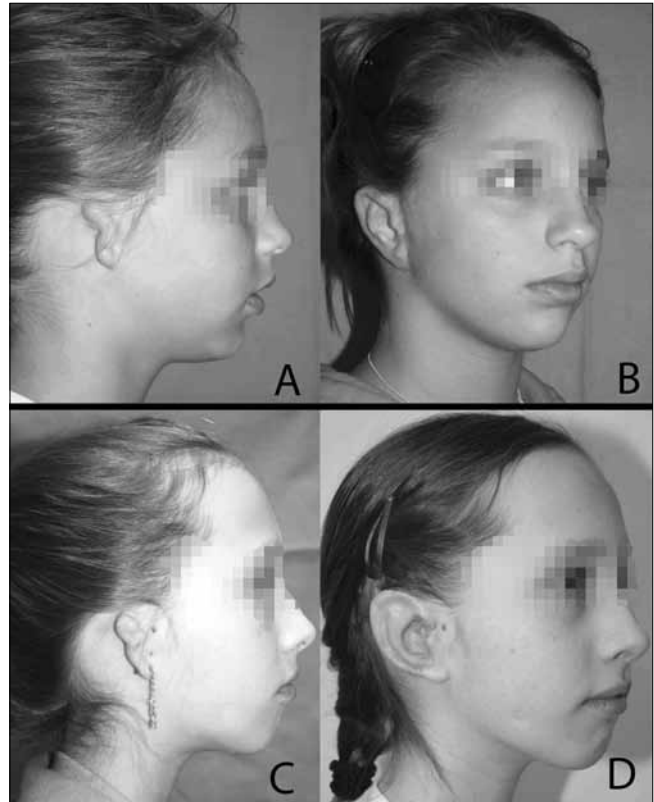


Fig. 3. A: Case 2: preoperative appearance of a lobule-type microtia in an 11-year-old girl. B: postoperative appearance. C: Case 3: preoperative appearance of a lobule-type microtia in a 10-year-old patient. D: final appearance.

within a few months after surgery. Recently, some authors have described a method using porous polyethylene framework covered by a large temporoparietal fascia¹⁹ to limit complications. According to Romo²⁰, this technique does not require artistic or technical skills on the part of the surgeon, but, in our opinion, it gives poor individual results.

Therefore, the autologous cartilage graft is currently the gold standard for reconstruction: the aesthetic results are excellent, the surgical option is psychologically well accepted, there are no consequences in case of trauma, and normal physical activity is not limited.

A satisfactory result is the most difficult to obtain in patients with an associated syndrome²¹; in such cases, microtia correction must be included in the global treatment of the facial anomaly. The correct surgical timing to overcome typical difficulties may not be easy to determine^{12 22}. Indeed, despite the fact that this reconstructive technique follows the same principles as standard microtia correction, the presence of facial asymmetries is a source of specific technical problems, such as properly positioning the ear in both the sagittal and vertical dimensions^{11 23}. For this reason, many authors prefer to postpone microtia correction after the skeletal treatment of the facial asymmetry in order

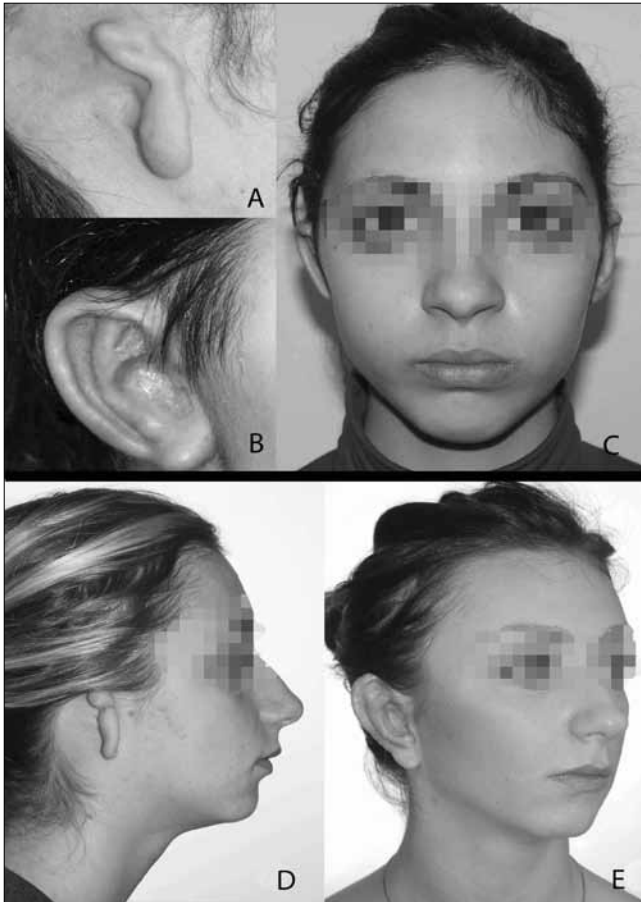

Fig. 4. Case 4. A: preoperative appearance of a lobule-type microtia in a 10-year-old girl. B: reconstructed ear. C: final appearance. D: Case 5: preoperative appearance of a lobule-type microtia in a 15-year-old patient. E: appearance after 5 years.

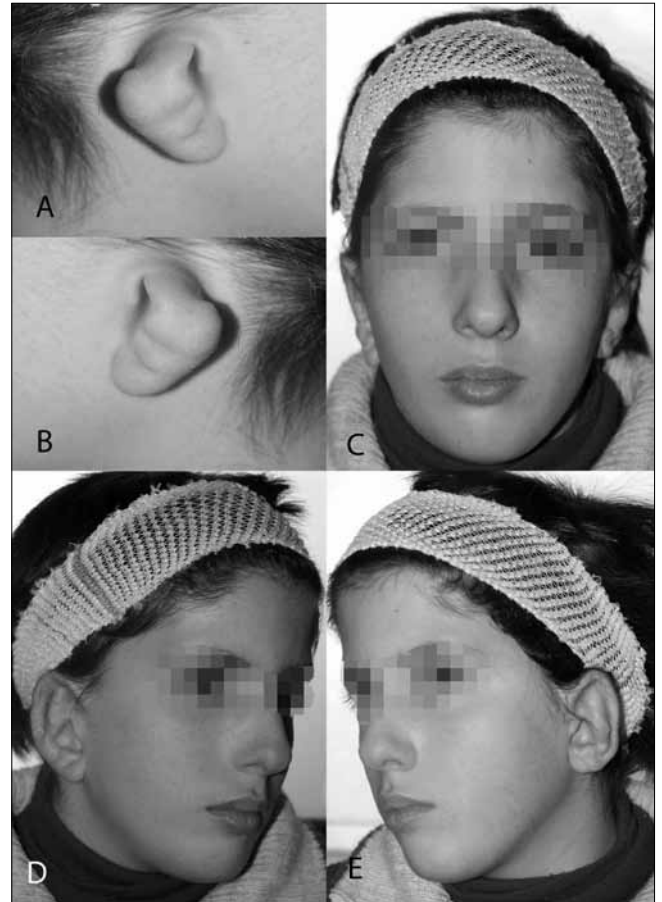


Fig. 5. Case 6: bilateral concha-type microtia in a 8-year-old child. A: preoperative appearance of the right ear. B: preoperative appearance of the left ear. C: postoperative frontal view. D: right reconstructed ear. E: left reconstructed ear.

to have more symmetrical reference points (labial commissure, lateral canthus, eyebrow, mandibular angle, etc.) for correct positioning of the reconstructed ear²².

In our experience²⁴, the ear reconstruction is the main request by paediatric patients and so can be performed before the skeletal correction. An exception is represented by cases of a severe mandibular hypoplasia in which there is a functional indication to reconstruct the mandible with a costal graft around 4 to 5 years of age.

In accordance with the literature^{10,25}, we do not undertake reconstruction of the ear before the age of 9 to 10 years, for several reasons. Although the ear reaches approximately 85% of its final size at about 3 years of age, its growth continues until maturity of the individual (with small changes in size and position)²⁶. The ear is considered fully developed by the age of 6 to 7 years, but it is better to wait for good development of the chest so that it is possible to obtain a sufficient amount of autologous costal cartilage. This permits the construction of a more elaborate structure without a risk of anatomical malformation of the donor site^{27,28}. Finally, compliance of the patient is extremely important in the postoperative period, and cooperation is better in children aged at least 9-10 years.

In only one case we performed the surgical procedure in a patient with bilateral microtia at the age of 7 years because of emerging psychosocial problems.

In our experience, it is extremely important that parents help their children to understand the importance of the correct time for surgery, informing and reassuring them of a good future reconstruction outcome. While waiting for the reconstruction, we do not recommend the use of temporary prostheses^{29,30} because they require a screw or removal of cartilaginous remnants for placement. The resulting scars may negatively interfere with the future reconstruction.

In patients with associated syndrome in whom there is an indication for surgical treatment of mandibular defects, if there are no specific functional problems, we postpone the mandibular surgery until 8 to 10 years of age. Thus, we take advantage of simultaneous performance of the ear reconstruction and mandibular procedures to reduce the number of operations needed for comprehensive rehabilitation of the face.

Different degrees of microtia and various concerns regarding the different anatomical features that require reconstruction exist. Normally, it is mandatory to reproduce the detailed anatomy of the entire ear. In certain cases the malformation does not include all the structures of the ear.

When the tragus, the intertragic incision, or the antitragus are normally developed, they will not be included in the framework. However, if these structures are present but deformed or insufficiently developed, it is better to sacrifice them and create a complete cartilage model.

In accordance with Firmin³, since 2002 the skin incision in the auricular region has been carried out with the transposition of a smaller lobe, but without the subcutaneous pedicle of the posterior skin flap as in Nagata's technique to avoid central necrosis. In this way, this complication is reduced, the surgical dissection is performed more easily and the position of the cartilaginous skeleton can be modulated. In our experience, a useful technique is to model a longer helix that reaches the lateral side of the lobe, avoiding an anatomical gap between the lobe and the helix that would be an aesthetically unpleasant feature.

At the end of the surgical procedure, we consider extremely important that two suction drains are placed and that the surgeon carefully assesses the immediate result which would be strictly similar with the final one. In case of doubt, immediate correction is mandatory. Possible minor future corrections must be avoided for greater patient comfort and to prevent additional manipulations and scarring. Moreover, the use of suction avoids haematoma formation, decreasing the risk of infection.

We believe that the thoracic incision should not exceed 5 to 7 cm in length. The decreased exposure of the operative field, partially compensated by the easy sliding of the dissected planes and by simple traction of the tissues, makes the harvesting slightly more difficult; however, it ensures the formation of a small scar.

Preservation of the deep perichondrium³¹ reduces the risks of bleeding and perforation of the pleura and ensures greater solidity of the deep plane in the donor site. With correct suturing of the muscle planes, the morphological aspect of chest profile is almost normal.

We consider reduction of postoperative pain mandatory to maintain the young patient's confidence and cooperation. Initially, we used continuous intravenous infusion of morphine and painkillers; however, we now prefer intercostal infusion of a local anaesthetic, deep in the donor site, in three boluses per day for 3 days, taking care to close the drainage hood for 1 h after the infusion.

The stability of the projection obtained after the second surgical step is currently discussed in international literature. Problems associated with resorption and shifting of the cartilage graft, up to a total loss of the cephalo-auricular angle depth, have been reported^{32,33}.

In general, unlike Nagata, we prefer to use a slightly larger (both in length and thickness) cartilage graft to counteract the inevitable shrinkage. We stabilise the graft with transfixing stitches from the cartilage to the conchal skin. In 20 cases, attempts to standardise the projection rate, we used a wedge-shaped Medpor deeply positioned, of

at least 6 mm in height. We insert one piece of cartilage, as a buffer, between the Medpor implant and the cartilage framework and a second piece posteriorly to protect the implant from the future injuries. The idea to overcome scar contraction with a non-absorbable material gave favourable results.

Recently, we also create a tunnel behind the framework to bury one or more pieces of cartilage under the retroauricular soft tissue after the elevation of the ear to obtain a correct projection¹⁰.

Another trick, applied in the second stage to maintain the depth of the retro-auricular sulcus, is the use of the superficial mastoid flap to cover only the new semilunar cartilage graft. Obviously, avoidance of dissection of the posterior face of the framework that is too superficial is mandatory to ensure skin graft survival. We have not experienced posterior exposure of the cartilage framework. Unlike the majority of authors^{3,15}, we prefer an superficial mastoid fascial flap to a temporalis fascial flap, since the superficial mastoid flap is easier and faster to dissect and insert²⁵. In the present study, we obtained excellent results, and no additional scarring, exposure of the cartilage grafts, or fascial necrosis occurred in any of the 210 patients treated.

We abandoned the use of the superficial temporal fascia after the first seven cases because of the advantage of its availability in cases of secondary complications. The skin graft for the sulcus is harvested from the adjacent region, which has the same texture as that of the healthy auricular region, with no residual scar and only minor pain¹⁸.

Conclusions

Auricular reconstruction procedures, regardless of the degree of deformity (isolated microtia or severe facial asymmetry), require careful planning. The experience of the surgeon, surgical technique, favourable local conditions and compliance of the patient and family are the elements required to obtain satisfactory functional and aesthetic results.

In agreement with previous authors^{5,12}, we believe that good outcome is dependent on the accuracy, patience and training of the surgeon in terms of modelling of ear cartilage details and maintaining the skin integrity of the auricular region.

In cases involving unfavourable local conditions (presence of scar tissue secondary to severe trauma, burns, or secondary reconstructions), additional techniques can be performed with different results, but the outcome will probably be less satisfactory.

References

- 1 Luguetti DV. *Microtia: epidemiology and genetics*. Am J Med Genet A 2012;158A:124-39.
- 2 Brent B. *Microtia repair with rib cartilage grafts. A review of personal experience with 1000 cases*. Clin Plast Surg 2002;29:257-71.

- ³ Firmin F. *State of the art autogenous ear reconstruction in cases of microtia*. *Adv Otorhinolaryngol* 2010;68:25-52.
- ⁴ Tanzer RC. *Total reconstruction of the external ear*. *Plast Reconstr Surg* 1959;23:1-15.
- ⁵ Brent B. *Auricular repair with autogenous rib cartilage grafts: two decades of experience with 600 cases*. *Plast Reconstr Surg* 1992;90(Suppl 3):355-74.
- ⁶ Brent B. *Technical advances in ear reconstruction with autogenous rib cartilage grafts: personal experience with 1200 cases*. *Plast Reconstr Surg* 1999;104:319-34.
- ⁷ Weerda H. *Classification of congenital deformities of the auricle*. *Facial Plast Surg* 1988;5(Suppl 5):385-8.
- ⁸ Aguilar EF. *Auricular reconstruction of congenital microtia (grade III)*. *Laryngoscope* 1996;106(Suppl 82):1-26.
- ⁹ Nagata S, Fukuda O. *A new reconstruction for the lobule type microtia*. *Jpn J Plast Reconstr Surg* 1987;7:689.
- ¹⁰ Firmin F. *A novel algorithm for autologous ear reconstruction*. *Semin Plast Surg* 2011;25:257-64.
- ¹¹ Posnick JC, Al-Qattan MM, Whitaker LA. *Assessment of the preferred vertical position of the ear*. *Plast Reconstr Surg* 1993;91(Suppl 7):1198-203.
- ¹² Firmin F, Guichard S. *La Microtie dans la dysplasie oto-mandibulaire*. *Ann Chir Plast Esthet* 2001;46:467-77.
- ¹³ Quatela VC, Thompson SK, Goldman ND. *Microtia reconstruction*. *Facial Plast Surg Clin North Am* 2006;14(Suppl 2):117-27.
- ¹⁴ Nagata S. *Modification of the stages in total reconstruction of the auricle: part I. Grafting the three-dimensional costal cartilage framework for lobule-type microtia*. *Plast Reconstr Surg* 1994;93:221-30.
- ¹⁵ Nagata S. *Modification of the stages in total reconstruction of the auricle: part IV. Ear elevation for the constructed auricle*. *Plast Reconstr Surg* 1994 ;93:254-66.
- ¹⁶ Nagata S. *Modification of the stages in total reconstruction of the auricle: part II. Grafting the three-dimensional costal cartilage framework for concha-type microtia*. *Plast Reconstr Surg* 1994;93:231-42.
- ¹⁷ Nagata S. *Modification of the stages in total reconstruction of the auricle: part III. Grafting the three-dimensional costal cartilage framework for small concha-type microtia*. *Plast Reconstr Surg* 1994;93:243-53.
- ¹⁸ Firmin F. *Ear reconstruction in cases of typical microtia. Personal experience based on 352 microtic ear corrections*. *Scand J Plast Reconstr Hand Surg* 1998;32(Suppl 1):35-47.
- ¹⁹ Reinisch JF, Lewin S. *Ear reconstruction using a porous polyethylene framework and temporoparietal fascia flap*. *Facial Plast Surg* 2009;25(Suppl 3):181-9.
- ²⁰ Romo T 3rd, Reitzen SD. *Aesthetic microtia reconstruction with Medpor*. *Facial Plast Surg* 2008;24:120-8.
- ²¹ Figueroa A, Pruzansky S. *The external ear, mandible and other components of hemifacial microsomia*. *J Max Fac Surg* 1982;10:200-11.
- ²² Yamada A. *External ear reconstruction in hemifacial microsomia*. *J Craniofac Surg* 2009;20(Suppl 2):1787-93.
- ²³ Thomson HG, Correa A. *Unilateral microtia reconstruction: is the position symmetrical?* *Plast Reconstr Surg* 1993;92(Suppl 5):852-7.
- ²⁴ Anghinoni M. *Malattie rare, malattie genetiche e distretto oro-cranio-facciale. Parte seconda; Sindrome del I e II arco branchiale*. Pisa: Edizioni ETS; 2002. p. 203.
- ²⁵ Siegert R, Weerda H, Magritz R. *Basic techniques in autogenous microtia repair*. *Facial Plast Surg* 2009;25:149-57.
- ²⁶ Bauer BS, Lin JL. *Ear, Microtia* [<http://emedicine.medsxope.com/article/129008>].
- ²⁷ Kanetoshi O, Kiyoshi N, Eiichi O. *Chest wall deformities and thoracic scoliosis after costal cartilage graft harvesting*. *Plast Reconstr Surg* 1997;99:1030-6.
- ²⁸ Thomson HG, Kim TY, Ein H. *Residual problems in chest donor sites after microtia reconstruction: a long-term study*. *Plast Reconstr Surg* 1993;95:961-8.
- ²⁹ Wilkes GH, Wolfaardt JF, Dent M. *Osseointegrated alloplastic versus autogenous ear reconstruction: criteria for treatment*. *Plast Reconstr Surg* 1994;93(Suppl 5):967-79.
- ³⁰ Thorne CH, Brect LE, Bradley JP. *Auricular reconstruction: indications for autogenous and prosthetic techniques*. *Plast Reconstr Surg* 2001;15:1241-52.
- ³¹ Nagata S. *A new method of total reconstruction of the auricle for microtia*. *Plast Reconstr Surg* 1993;92:187-201.
- ³² Tai Y, Tanaka S, Fukushima J. *Refinements in the elevation of reconstructed auricles in microtia*. *Plast Reconstr Surg* 2006;117:2414-23.
- ³³ Hou X, Zhang Q, Liu T. *Modification of the technique of ear framework fabrication for congenital microtia*. *J Craniofac Surg* 2012;23:1296-300.

Received: July 31, 2014 - Accepted: November 8, 2014

Address for correspondence: Marilena Anghinoni, Head and Neck Department, Maxillo-Facial Surgery Division, University Hospital of Parma, via Gramsci 14, 43100 Parma, Italy. Tel. +39 0521 703109. Fax: +39 0521 703080. E-mail: manghinoni@ao.pr.it

CLINICAL TECHNIQUES AND TECHNOLOGY

Mandibular reconstruction using fibula free flap harvested using a customised cutting guide: how we do it

Ricostruzione mandibolare con lembo microvascolare di fibula, allestito mediante utilizzo di guida di taglio customizzata: ecco come lo realizziamo

A. TARSITANO¹, L. CIOCCA², R. CIPRIANI³, R. SCOTTI², C. MARCHETTI¹¹ Maxillofacial Surgery Unit, Policlinico "S. Orsola-Malpighi", University of Bologna, Italy; ² Department of Biomedical and Neuromotorial Science, University of Bologna, Italy; ³ Plastic Surgery Unit, Policlinico S. Orsola-Malpighi, Bologna, Italy

SUMMARY

Free fibula flap is routinely used for mandibular reconstructions. For contouring the flap, multiple osteotomies should be shaped to reproduce the native mandibular contour. The bone segments should be fixed using a reconstructive plate. This plate is usually manually bent by the surgeon during surgery. This method is efficient, but during reconstruction it is complicated to reproduce the complex 3D conformation of the mandible and recreate a normal morphology with a mandibular profile as similar as possible to the original; any aberration in its structural alignment may lead to aesthetic and function alterations due to malocclusion or temporomandibular disorders. In order to achieve better morphological and functional outcomes, we have performed a customised flap harvest using cutting guides. This study demonstrates how we have performed customised mandibular reconstruction using CAD-CAM fibular cutting guides in 20 patients undergoing oncological segmental resection.

KEY WORDS: Fibula free flap • Mandibular reconstruction • CAD-CAM technique • Cutting guide

RIASSUNTO

Il lembo libero di fibula è routinariamente utilizzato per le ricostruzioni mandibolari. Al fine di ottenere una modellazione del lembo che consenta di ricostruire l'arco mandibolare, sono necessarie multiple osteotomie della fibula. Queste vengono, di norma, eseguite manualmente dal chirurgo; così come la modellazione della placca ricostruttiva che avrà il ruolo di solidarizzare i vari segmenti ossei di fibula. Questo metodo è consolidato, ma ha il difetto di essere incostante in termini di risultati estetici e molto operatore-dipendente. Si ricordi come alterazioni a livello del profilo mandibolare ricostruito costituiscono non solo un difetto estetico, ma possano inficiare anche la funzione articolare e masticatoria. Per queste ragioni vogliamo presentare il nostro workflow CAD-CAM utilizzato in 20 casi di ricostruzioni mandibolari customizzate, in cui il progetto chirurgico virtuale è stato trasferito in sala operatoria mediante l'utilizzo di guide di taglio ossee per la mandibola e la fibula.

PAROLE CHIAVE: Lembo libero di fibula • Ricostruzione mandibolare • Tecnica CAD-CAM • Guide di taglio

Acta Otorhinolaryngol Ital 2015;35:198-201

Introduction

Free flaps, combining a high success rate with low donor site morbidity, are considered the gold standard for the reconstruction of tissues lost during oncologic surgery¹⁻³. Free fibula flap is routinely used for large jaw reconstructions^{4,5}. This can be considered a safe surgical procedure even in elderly head and neck cancer patients¹.

For contouring the flap, multiple osteotomies should be shaped to reproduce the native mandibular contour. The bone segments should be fixed using a reconstructive plate. This plate is usually manually bent by the surgeon during surgery, eventually performing the pre-plating technique using the native mandible as a template, or

repositioning template^{4,6}. This method is efficient, but during reconstruction it is complicated to reproduce the complex 3D conformation of the mandible and recreate a normal morphology with a mandibular profile as similar as possible to the original; any aberration in its structural alignment may lead to aesthetic and function alterations due to malocclusion or temporomandibular disorders.

Modern techniques, such as computer-aided design/computer-aided manufacturing (CAD-CAM), offer new solutions for planning of maxillofacial reconstructive surgery in relation to aesthetic outcomes and the final prosthetic and functional rehabilitation⁷.

This study aimed to show how we have performed customised mandibular reconstruction using CAD-CAM fibular cutting guides in 20 patients undergoing oncological segmental resection.

Clinical techniques and technology

CAD-CAM-based mandibular reconstruction procedures using vascularised fibula free flap transfers were performed in 20 cases between 2011 and 2014 at Maxillofacial Surgery Unit of Policlinico "S. Orsola-Malpighi", Bologna, Italy. Histological tumour type, type of mandibular resection and number of fibular segments are summarised in Table I.

Virtual planning and CAD procedures were performed as described previously by our group³: planning began with the acquisition of a high-resolution CT-scan of the craniofacial region and the lower leg as a donor site.

DICOM format data were processed by the surgeons using CMF software, version 6.0 (Materialise, Lueven, Belgium). Using this software, the surgeon allowed creation of 3D virtual models of the maxillofacial skeleton and the fibula and simulation of mandibular and fibular osteotomies (Fig. 1).

The planned surgery was used to design and manufacture customised surgical cutting guides for mandible and fibula flap performed by Sintac s.r.l. Trento (Fig. 2).

The computer-aided design of the surgical device was conducted using Rhino software, version 4.0 (Robert McNeel & Associates, Seattle, WA, USA).

Table I. Histological classification, type of defect and type of flap.

Patient	Tumour	Resection	Fibula segments
Pt. 1	Ameloblastoma	B	1
Pt. 2	Fibrosarcoma	B+R+C	2
Pt. 3	Keratocyst	R+C	2
Pt. 4	Ameloblastoma	B+S	3
Pt. 5	Squamous cell carcinoma	B+SH	2
Pt. 6	Squamous cell carcinoma	S+B+R	3
Pt. 7	Osteosarcoma	B+S+B	3
Pt. 8	Squamous cell carcinoma	S+B	2
Pt. 9	Ameloblastoma	B+S+B	4
Pt. 10	Squamous cell carcinoma	C+R+B	2
Pt. 11	Squamous cell carcinoma	B	1
Pt. 12	Squamous cell carcinoma	B+S	3
Pt. 13	Squamous cell carcinoma	B+S+B	2
Pt. 14	Squamous cell carcinoma	S+B+R	3
Pt. 15	Ameloblastoma	R	1
Pt. 16	Aneurysmal cyst	B+S	3
Pt. 17	Ameloblastoma	R+B	3
Pt. 18	Squamous cell carcinoma	R+B	3
Pt. 19	Osteosarcoma	R+B	3
Pt. 20	Squamous cell carcinoma	B+S+B	3

C: condyle; R: ramus; B: body; S: symphysis.

Fibular osteotomy guides were used to allow the free flap to fit the defect accurately, as planned virtually preoperatively (Fig. 3). Reconstructive plates were manufactured by a direct metal laser sintering method, as described previously³. The customised reconstructive bone plate

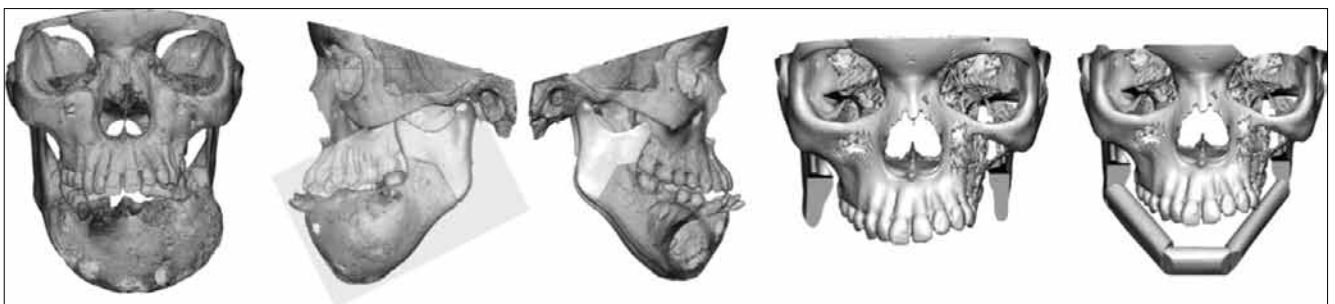


Fig. 1. 3D virtual models of the mandibular tumour (on the left); virtual simulation of surgical defect and reconstruction planned using three fibular bone segments (on the right).

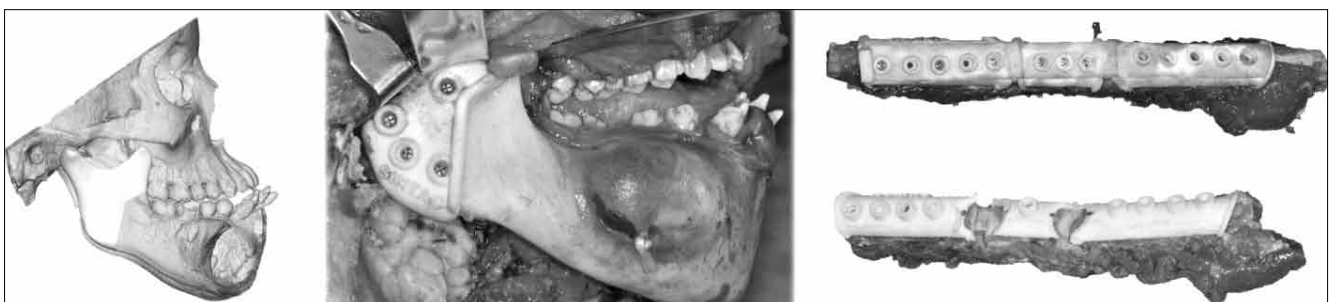

Fig. 2. Mandibular (left) and fibular (right) cutting guides used to perform osteotomies, exactly as pre-operatively planned.

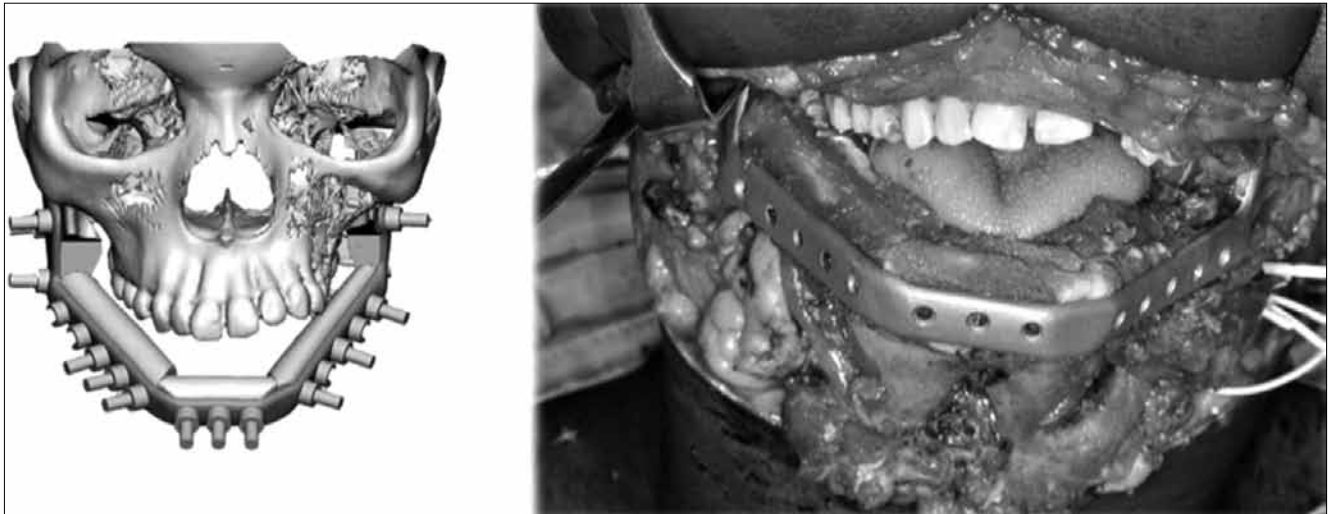

Fig. 3. Fibular segments insetting after cutting guide removal.




Fig. 4. Bone flap osteotomies performed using piezoelectric saw (Mectron s.p.a.).

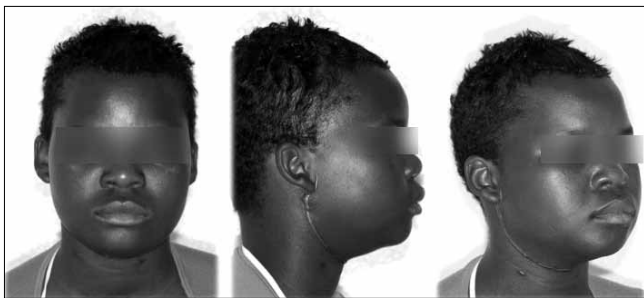


Fig. 5. Post-operative morphological appearance in a patient who underwent subtotal mandibulectomy and reconstruction using CAD-CAM technique.

that supported the fibula free flap was designed by thickening the outer surface of the healthy side of the mandible to obtain an ideal aesthetic contour and avoid bone deformities on the side affected by the tumour. Since the holes of the fixing screws of the guides are the same of those in the bone plate, it is very easy to insert all fibular segments in the final planned position anchored to the reconstructive plate.

Linear osteotomies and wedge osteotomies were performed using a piezoelectric device (Fig. 4). No microvascular complications, in terms of partial or total flap loss, were observed in any patient.

Discussion

CAD/CAM technologies have been introduced in the field of maxillofacial bone reconstruction to increase precision and reduce morbidity and operation time⁷.

This virtual environment permits ideal pre-surgical planning for reconstruction: native mandibular morphology can be obtained with a very high precision⁸. The mandibular cutting guide allowed the site and orientation of the planned osteotomies to be duplicated during surgery. Moreover, a custom-made cutting guide for the fibular bone helps the surgeon to set the osseous free flap. The straight fibula flap is contoured to resemble the neo-mandible using a surgical cutting guide that is planned, choosing the fibular osseous fragment virtually and the orientation that is most suitable for future implanted-supported prosthesis insertion. In mandible-wide reconstruction, it is possible to accurately measure the length of the bone component of the free flap and the extent of the vascular pedicle.

Fibular bone segmentation, using a cutting guide and a piezoelectric saw, can be safely performed. Performing piezoelectric osteotomies, the surgeon achieves better procedural control and increases the precision of bone segmentation. The use of a cutting guide and piezoelectric saw significantly reduce the risk of damaging the vascular bundle that runs along the bone. The continuity of the periosteum was preserved and the vascular bundle was not dissected off or protected during the osteotomy. The fact that microvascular failure of the vascularised

bone segments was absent in this series, including when the segment's length was very short, is consistent with the hypothesis of less thermal and mechanical damage after osteotomies with piezosurgery compared with traditional saw damage.

Each segment can be readily osteotomised because both the length and the cutting angle are precisely indicated by the guide. This consistently reduces sectioning time and allows the surgeon to section the fibula into units less than 3.0 cm long, affording a better morphological result upon reconstruction. Our microvascular success rate was 100%, confirming the safety of the procedure.

The morphological results are significantly better than those achieved with standard technique (Fig. 5).

Last but not least, an advantage of the CAD-CAM protocol is that it can be used to educate fellow reconstructive surgeons. The availability of precise cutting guides for bone sectioning make performance of good surgery possible, even by surgeons at the beginning of their learning curves.

There are also some difficulties/limits that surgeons may encounter during surgery using this method that should be kept in mind: when a skin paddle is necessary for a composite reconstruction, it may be difficult to pre-operatively plan the correct position of the guide in relation to the musculocutaneous perforators. In our series, only one case needed an osteocutaneous flap and in this case the perforator vessels were identified by angiography-CT of the leg. However, this could be a limitation of the proposed technique.

In conclusion, the new techniques facilitate all steps that, in the past, required highly skilled operators to restore

correct anatomy by manually sectioning the fibula and inserting bone using a manually bent standard bone plate.

References

- ¹ Tarsitano A, Pizzigallo A, Sgarzani R, et al. *Head and neck cancer in elderly patients: is microsurgical free-tissue transfer a safe procedure?* Acta Otorhinolaryngol Ital 2012;32:371-5.
- ² Deganello A, Gitti G, Parrinello G, et al. *Cost analysis in oral cavity and oropharyngeal reconstructions with microvascular and pedicled flaps.* Acta Otorhinolaryngol Ital 2013;33:380-7.
- ³ Baj A, Beltramini GA, Demarchi M, et al. *Extended-pedicle peroneal artery perforator flap in intraoral reconstruction.* Acta Otorhinolaryngol Ital 2013;33:282-5.
- ⁴ Pellini R, Mercante G, Spriano G. *Step-by-step mandibular reconstruction with free fibula flap modelling.* Acta Otorhinolaryngol Ital 2012;32:405-9.
- ⁵ Tarsitano A, Sgarzani R, Betti E, et al. *Vascular pedicle ossification of free fibular flap: is it a rare phenomenon? Is it possible to avoid this risk?* Acta Otorhinolaryngol Ital 2013;33:307-10.
- ⁶ Berrone M, Crosetti E, Succo G. *Repositioning template for mandibular reconstruction with fibular free flaps: an alternative technique to pre-plating and virtual surgical planning.* Acta Otorhinolaryngol Ital 2014;34:278-82
- ⁷ Tarsitano A, Mazzoni S, Cipriani R, et al. *The CAD-CAM technique for mandibular reconstruction: An 18 patients oncological case-series.* J Craniomaxillofac Surg 2014;42:1460-4.
- ⁸ Ciocca L, Marchetti C, Mazzoni S, et al. *Accuracy of fibular sectioning and insertion into a rapid-prototyped bone plate, for mandibular reconstruction using CAD-CAM technology.* J Craniomaxillofac Surg 2015;43:28-33.

Received: January 5, 2015 - Accepted: March 8, 2015

CASE SERIES AND REPORTS

Physiology and prospects of bimanual tracheoesophageal brass instrument play

Fisiologia e prospettive del suono bimanuale di un ottone in paziente portatore di valvola tracheoesofagea

F.J.M. HILGERS^{1,2}, R. DIRVEN³, I. JACOBI¹, M.W.M. VAN DEN BREKEL^{1,2,4}

¹ Department of Head and Neck Oncology and Surgery, The Netherlands Cancer Institute-Antoni van Leeuwenhoek, Amsterdam, The Netherlands; ² Institute of Phonetic Sciences (ACLIC), University of Amsterdam, The Netherlands;

³ Department of Otorhinolaryngology-Head and Neck Surgery Radboudumc Nijmegen, The Netherlands; ⁴ Department of Oral-Maxillofacial Surgery, Academic Medical Center University of Amsterdam, The Netherlands

SUMMARY

This study investigated whether trachea pressures during brass instrument play of laryngectomised patients are within the range of those measured during tracheoesophageal voicing, and whether application of an automatic speaking valve can 'free' both hands to play a brass instrument. Objective assessment of voicing and music playing parameters was carried out in 2 laryngectomised patients with a low-pressure indwelling voice-prosthesis able to play brass instruments (tenor horn and slide trombone): sound pressure levels in dB, maximum phonation time in seconds and trachea pressures in mmHg; videofluoroscopy, stroboscopy and digital high speed endoscopy to assess neoglottis vibration and opening. The dynamic range of the voice in the patients was 29 and 20 dB, and maximum phonation time was 22 and 19 sec, respectively; intratracheal pressures during voicing varied from 7 mmHg for the softest /a/ to 49 mmHg for the loudest /a/. For brass instrument play, the intratracheal pressures varied from 14 mmHg for the softest tone to 48 mmHg for the loudest tone. Imaging confirmed earlier findings that the neoglottis is closing and vibrating during voicing and remains 'open' without vibrations during music play, indicating good neoglottis control and innervation. From these objective measurements, we can conclude that trachea pressures during brass instrument play are within physiological ranges for tracheoesophageal voicing with a low-pressure indwelling voice-prosthesis. Furthermore, it was shown that application of a stable baseplate for retaining an automatic speaking valve and an additional customisable 'neck brace' makes bimanual play possible again.

KEY WORDS: Total laryngectomy • Videofluoroscopy • Stroboscopy • Trachea pressure • Neck brace

RIASSUNTO

Lo scopo del presente studio è stato quello di valutare se le differenze pressorie misurate durante il suono di un ottone rientrano nel range di quelle ottenute durante la voce parlata tracheoesofagea nei pazienti laringectomizzati, e se l'applicazione di una valvola automatica può permettere di suonare uno strumento musicale senza l'utilizzo delle mani nella gestione della valvola. La valutazione obiettiva della voce e della musica suonata è stata effettuata in due pazienti laringectomizzati portatori di una protesi vocale a bassa pressione, capaci di suonare uno strumento musicale della categoria degli ottoni (corno e trombone) mediante la misurazione di: intensità sonora in dB, tempo massimo di fonazione in secondi, pressione endotracheale; videofluoroscopia, stroboscopia ed endoscopia digitale ad alta velocità sono state utilizzate per valutare l'apertura e la vibrazione della neoglottide. Il range dinamico della voce è stato da 29 e 20 dB, con un tempo di fonazione massimo rispettivamente di 22 e 19 secondi; la pressione intra-tracheale durante la fonazione è variata da 7 mmHg per le tonalità più basse /a/ a 49 per le più alte /a/. Durante l'utilizzo dello strumento musicale la pressione endotracheale è variata da 14 mmHg per le basse tonalità a 48 mmHg per le alte tonalità. L'imaging ha confermato che la neoglottide si chiude e vibra durante la fonazione, mentre rimane aperta senza vibrazioni durante l'utilizzo di uno strumento musicale, indicando che c'è un buon controllo della neoglottide e una buona innervazione. Tramite queste misurazioni obiettive possiamo concludere che le pressioni endotracheali durante l'utilizzo di strumenti musicali rispecchiano i range fisiologici della fonazione tracheoesofagea con ausilio di una protesi fonatoria a bassa pressione. Inoltre, è stato dimostrato che l'applicazione di uno "baseplate" stabile con una valvola fonatoria automatica e un sostegno per il collo personalizzato permette a questi pazienti di suonare tenendo libere entrambe le mani.

PAROLE CHIAVE: Laringectomia totale • Videolaringoscopia • Stroboscopia • Pressione endotracheale • Collare

Acta Otorhinolaryngol Ital 2015;35:202-207

Introduction

In 2009, Cavalot and colleagues reported the case of a professional musician and music teacher who regained his ability to play a brass instrument after total laryngectomy and secondary tracheoesophageal puncture

(TEP)¹. The patient had his surgery in 2000 for a pT-3pN0M0 glottic carcinoma and readily developed good oesophageal voice, but obviously was no longer able to play his slide trombone. In 2003, at a workshop on voice rehabilitation with planned live surgery in San Giovanni

di Rotondo in Italy, he asked whether TEP and voice prosthesis (VP) insertion would enable him to regain his ability to play his slide trombone again. The surgical team at the workshop suggested that in any case his voice likely would become stronger and more fluent and that there was a fair chance he also would be able to play his instrument again, based on prior anecdotal observations with patients being able to whistle and softly play a flute. After the TEP and immediate indwelling VP insertion (Provox2, Atos Medical, Hörby, Sweden), he indeed instantly had a better voice, both in loudness and in fluency. After being provided with an automatic speaking valve (ASV; Provox FreeHands HME, Atos Medical, Hörby, Sweden) with the cough relief valve glued shut to prevent its inadvertent opening, at the third or fourth attempt he was able to play his slide trombone again. Indeed, after less than a minute he literally blew the seal of the adhesive (FlexiDerm oval, Atos Medical, Sweden) retaining the ASV, and playing became impossible because of the air leak underneath the adhesive.

As articulately described by Cavalot and colleagues, the patient did not give up and switched to a tenor horn, which he could play with one hand, freeing the other hand for stoma occlusion¹. This enabled him to continue his music career, not only as a teacher, but also as a performing artist. In the publication about his case, the behaviour of the neoglottis during speaking and music play was thoroughly analysed with videofluoroscopy and stroboscopy. As expected, during voicing, there is neoglottis closure and mucosal vibration, while during music play the neoglottis is 'open' and not vibrating, a behaviour similar to that described for the normal glottis and pharynx under both conditions.

Despite this success, the patient still felt the urge to regain his ability to use both hands for music play and to be able to play his slide trombone again. This was the reason he contacted the first author, who he knew from his surgery at the workshop in 2003. Since objective pressure measurements were not available from the otherwise comprehensive study published about his case, the first question to the patient was how much higher the perceived air pressure was during music play than during (loud) voicing. His answer was that it felt to be like "10 times higher". At first, this suggested a pressure that was too high for any ASV adhesive to withstand for a reasonable length of time, but since actual data about intratracheal pressures were not available, it was decided to first assess these pressures before denying the desired 'handsfree' option to the patient.

The goal of the present paper, therefore, is to report on the assessment of the intratracheal pressures exerted during brass musical instrument play and to compare those to the pressures during (loud) voicing, which is the only piece of the puzzle missing. This would also help in determining whether recent developments in adhesives and other support devices would enable to free both hands for bimanual music play. Moreover, the goal was to as-

sess whether this first patient's unique skills are achievable for more patients based on observations in a second laryngectomised patient playing the slide trombone. In other words, can playing a brass instrument be safely recommended to laryngectomised patients without the risk of sanctioning undue high and potentially harmful intratracheal (back) pressures.

Materials and methods

This study investigated 2 laryngectomised patients able to play a brass instrument, i.e. a tenor horn and a slide trombone. The clinical course of patient 1 has been extensively described previously¹. Patient 2, an amateur musician, underwent total laryngectomy in combination with a total thyroidectomy for a deeply invasive papillary thyroid carcinoma (T4aN0) in December 2012. He also received ablative ¹³¹I therapy in the spring of 2013. Recordings and imaging were made in June 2012 (patient 1; 55 years of age at the time) and December 2013 (patient 2; 71 years of age at the time). Both patients were evaluated according to the same protocol, consisting of trachea pressure measurements, voice quality assessment (sound pressure level and maximum phonation time) and imaging of the neoglottis (videofluoroscopy, flexible stroboscopy and high speed digital endoscopy) during voicing and music play. Recordings were made with digital occlusion of the stoma via a HME in a peristomal adhesive.

Trachea pressure measurements

Trachea pressures were recorded with a digital manometer (Druck DPI 705 Digital Pressure Indicator; GE/Druck Incorporated, 4 Dunham Drive, New Fairfield, Connecticut 06812, USA; regular calibration: Amtele AB, Kungens Kurva, Sweden) both during voicing and during tenor horn play. In patient 1, recordings were made both for manual occlusion of the stoma through a HME, and for automatic valve occlusion. Recordings in patient 2 were made with manual occlusion only. A peristomal adhesive (Provox StabiliBase, Atos Medical, Hörby, Sweden) was perforated with a 4 mm dermal punch to allow airtight access for a customised connector tube attached to the manometer (Fig. 1). Since the first patient initially used a Provox2 voice prosthesis, subsequently to be replaced with a Provox Vega (with a lower airflow resistance²), these trachea pressure measurements were also carried out with the latter VP in place. The second patient already had a Provox Vega.

Voice quality parameters

Dynamic range (DR) was measured using a dB meter (Sound Level Meter Chauvin Arnoux CA 834 dB meter, calibrated according to the manufacturer's recommendations). The dB meter was placed at a distance of 30 cm from the patient's mouth. The patient was asked to occlude the stoma and produce a comfortable sustained /a/ (3 times), to



Fig. 1. Trachea pressure measurement during voicing (left), and during brass instrument play (right) using a digital manometer airtight attached into a peristomal adhesive; printed with permission.

phonate as softly as possible on a sustained /a/ (3 times) and lastly to phonate as loudly as possible on a sustained /a/ (3 times). The softest and the loudest of the 3 attempts were taken as the respective sound pressure level, whereas for comfortable loudness the mean was taken. Maximum phonation time (MPT) in sec was assessed in the same set-up by asking the patient to produce the vowel /a/ 3 times at a comfortable loudness level as long as possible. The longest of the 3 attempts was taken as MPT.

Neoglottis imaging

Videofluoroscopy: Videofluoroscopy was done with Omnipaque coating of the mucosa of the neoglottis during soft/loud and low/high pitched voicing and the same during music play with the addition of playing a scale from the lowest to the highest tone and back again. Swallowing proficiency was assessed with thin and thick liquid Omnipaque and coated cake.

Video stills were made with the program 'ImTOO Video to Picture' (version 1.0.35.0825; ImTOO Software Studio, Xilisoft Corporation), which enables batch extraction of video stills for comparison of the neoglottis configuration at similar situations during (soft to loud and low to high pitch/tone) voicing and brass instrument play.

Stroboscopy and high-speed digital flexible endoscopy:

Stroboscopy was done with the Xion flexible video-nasopharyngoscope (with high-resolution CCD sensor at the distal tip) and EndoSTROB System (Xion GmbH, Berlin, Germany). Since stroboscopy of the neoglottis has the drawback that the pitch of TLE voices often is unstable/varying, high-speed digital imaging (HDSI) was carried out to also obtain 'pitch independent' images for verification of the vibrations/behaviour of the neoglottis³. HDSI was carried out with the flexible endoscope of the HreS Endocam 5562 laryngoscopic diagnosis system (Richard Wolf, Knittlingen, Germany).

Bimanual music play enhancement: The peristomal adhesive used for attaching the ASV was the Provox StabiliBase (Atos Medical, Hörby, Sweden) with additional silicon glue⁴. For reinforcing and further stabilising the adhesive seal, the customisable Nijmegen Neck Brace was used (Fig. 2)^{5,6}.

Results

Analysis of videofluoroscopy images showed essentially the same pharyngoesophageal segment configuration and



Fig. 2. Bimanual tenor horn play with an automatic speaking valve (ASV; Provox FreeHands HME) in a peristomal adhesive (Provox StabiliBase) supported with a customisable Nijmegen neck brace; printed with permission.

functional behaviour as published by Cavalot et al.¹ Figure 3 shows the comparative video stills of voicing and brass instrument play for loudness (softest, comfortable, and loudest /a/ and tone) and pitch (lowest and highest /a/ and pitch) for patient 1. Figure 4 shows video stills of

playing a full scale from low to high and back (top left to bottom right) for patient 1. In Figure 3 a, it is clearly visible that the pharynx in all music playing conditions is wider than in the similar voicing conditions. Moreover, the upward bulging of the neoglottic bar in the voicing conditions indicates that there is good neoglottic closure, whereas the 'flat' structure at the neoglottis level during music play is indicating that there is no neoglottis closure, but merely a change in position of a mucosal fold. The images for patient 2 for both conditions were similar, except for the presence of a pseudo-epiglottis, which, however, did not seem to hinder voicing and music play in any of the recordings.

Figure 5 shows the comparison between voicing and brass instrument play. The clear neoglottic closure during a continuous /a/ voicing (frequency here 120 Hz) and the open neoglottic tract (and the mucosal fold indicated in the videofluoroscopy images) during brass instrument play are clearly noticeable. The images for patient 2 for both conditions were similar, again, except for the presence of the pseudo-epiglottis, not hindering voicing and music play.

Both patients had no trouble with oral intake and during swallowing assessment by videofluoroscopy, the pharyngo-oesophageal segment showed a normal postlaryngectomy relaxation/behaviour during passage of the bolus. In patient 2, the pseudo-epiglottis did not seem to affect swallowing.

The objective voice assessment parameters obtained with manual occlusion of the stoma through a HME are shown in Table I. The sound pressure level at loudest voicing was similar in both patients, but patient 1 was able to speak softer, resulting in a wider dynamic range for patient 1 (29 dB) than for patient 2 (20 dB). The maximum pho-

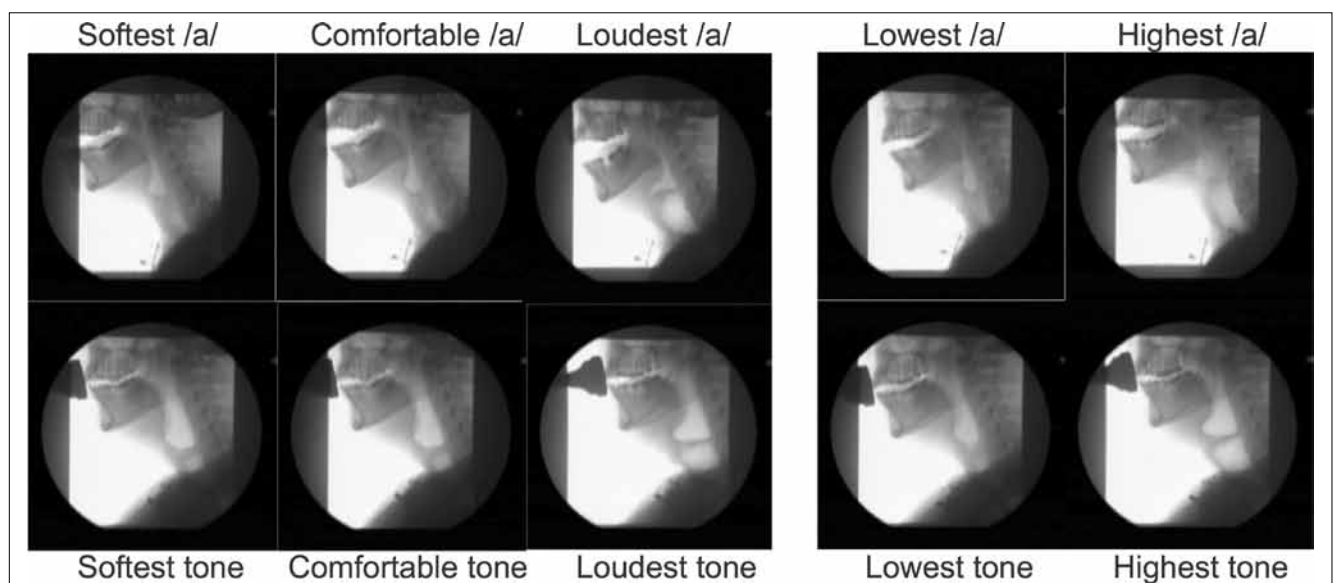


Fig. 3. Comparison of pharyngo-oesophageal segment during voicing and during tenor horn playing.

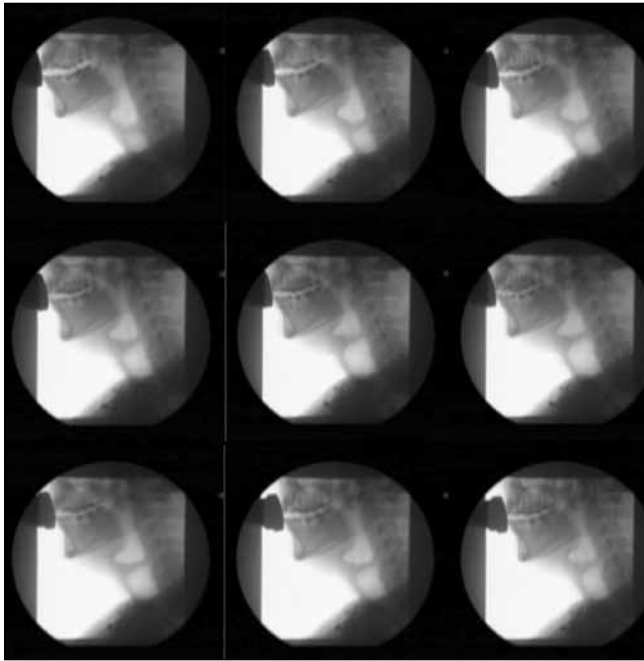


Fig. 4. Comparison of pharyngo-oesophageal segment during playing a scale from low to high and back, starting top left and ending bottom right; highest point in the scale is middle frame.

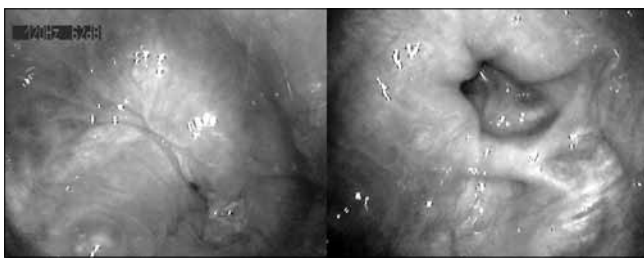


Fig. 5. Laryngoscopy/stroboscopy image of the neoglottis of patient 1 during voicing (sustained /a/; left), and during brass instrument play (right).

nation time for both patients was rather similar (22 and 19 sec). The intratracheal pressures during voicing varied from 7 mmHg for the softest /a/ to 49 mmHg for the loudest /a/. For brass instrument play, this varied from 14 mmHg for the softest tone to 48 mmHg for the loudest tone. Intratracheal pressures recorded with automatic valve occlusion for patient 1 were similar to the values obtained with manual occlusion (data not shown). As shown in Table I, for patient 1 there were slight differences in the pressures during voicing and music play with the Provox2 in situ compared to those with the Provox Vega, the pressures being somewhat lower with the Vega VP.

After application of the StabiliBase Adhesive and the customisable Nijmegen neck brace both patients were able to play their instruments bimanually, which is essential for slide trombone play. For both patients, the airtight seal dur-

Table I. Objective voice parameters, and intratracheal air pressure measurements in patient 1 (P1; professional musician) and patient 2 (P2; amateur musician) while voicing and playing the tenor horn; patient 1 was voicing with his existing Provox2 voice prosthesis first and then with the replacing Provox Vega prosthesis.

		Softest	Comfortable	Loudest
P1	Loudness in dB	57	69	86
	Dynamic range		29	
P2	Loudness in dB	65	67	85
	Dynamic range		20	
P1	Maximum phonation time		22 sec	
P2	Maximum phonation time		19 sec	
Air pressure in mmHg		Softest	Comfortable	Loudest
P1	Provox2/Vega + HME /a/	9.5/9.5	13.5/12.5	32/16
	Provox2/Vega + HME tenor horn	16/14	20/17.5	42/42
P2	Vega + HME /a/	7-11	10-14.7	33-49
	Vega + HME tenor horn	14-16.5	20-22	36-48

ing slide trombone play lasted for at least 2 hours, i.e. the duration of the practise sessions or concerts of his orchestra. An example of patient 1 bimanually playing the tenor horn and slide trombone can be seen and heard through the following link: <http://www.hoofdhalstankker.info/wpav/ wp-content/uploads/SalvatoreBarile-bimanual.mp4>.

Discussion

This study shows that trachea pressures during brass instrument play in these two laryngectomised patients are within physiological ranges for trachea-oesophageal voicing with a low-resistance indwelling voice-prosthesis. Moreover, application of a stable baseplate for the use of an automatic speaking valve⁴ and an additional customisable neck brace⁵ makes bimanual play possible again. Imaging of the neoglottis in this study for patient 1 confirms the earlier findings by Cavalot et al.¹, and adds a second case to the literature showing similar imaging results. Digital high-speed flexible endoscopy, and pitch independent assessment method of the (often irregular) vibrations of the neoglottis³, in both patients confirms the stroboscopy findings earlier obtained in patient 1¹. Voice prostheses have become the gold standard for voice rehabilitation, and over the last decades airflow resistances of indwelling voice prostheses have decreased substantially^{2,7,8}. This has resulted not only in improved and more comfortable voicing⁹, but, as also demonstrated herein, it (still) allows playing a brass instrument.

Knowledge of the trachea pressures during music play, presented here for the first time, can be used during coun-

selling to reassure similar professional and amateur musicians requiring total laryngectomy that there is still a fair chance that, as with the recovery of voicing, they will be able to continue with their work/hobby, despite the loss of their voice box. This certainly will have a positive impact on quality of life, as already mentioned by Cavalot and colleagues, who end their case report with the remark “the insertion of a voice prosthesis in a TE shunt establishes a functional unit useful not only for speech production, but also for fine lung airflow regulation, further improving QOL in patients after TL”. With the trachea pressures exerted during brass instrument play now known, clinicians can advise patients accordingly with even more confidence. Next to the important research on validated voice and speech quality assessments of the substitution voice after total laryngectomy¹⁰, objective assessments of neoglottic function and behaviour as presented here will hopefully trigger more such research on postlaryngectomy recovery prospects. This is especially relevant since the present study only concerns two cases and more series, and more musicians are needed to confirm these promising data.

Conclusions

Trachea pressures during brass instrument play are within physiological ranges for voicing in laryngectomised patients with a low-pressure indwelling voice-prosthesis. Application of a stable baseplate for retaining an automatic speaking valve and an additional customisable neck brace makes bimanual play possible again. Thus, playing a brass instrument safely can be recommended to laryngectomised patients without the risk of sanctioning undue high and potentially harmful intratracheal (back) pressures.

Acknowledgements

We are very grateful for the support of Anne Kornman SLP, Merel Latenstein SLP, and Lisette van der Molen PhD SLP with videofluoroscopy. Liset Lansaat is greatly acknowledged for taking care of the logistics of the assessment programs. Lot Zuur, MD PhD, head and neck surgeon at the Netherlands Cancer Institute is acknowledged for musical support during the professional perfor-

mances of patient 1, carried out in conjunction with this study. Atos Medical is acknowledged for providing the Druck calibrated digital pressure indicator, and for funding travel expenses for patient 1.

References

- ¹ Cavalot AL, Schindler A, Juliani E, et al. *Playing a brass instrument after total laryngectomy: a case report*. Head Neck 2009;31:1102-6.
- ² Hilgers FJ, Ackerstaff AH, van Rossum M, et al. *Clinical phase I/feasibility study of the next generation indwelling Provox voice prosthesis (Provox Vega)*. Acta Otolaryngol 2010; 130:511-9.
- ³ Van As CJ, Tigges M, Wittenberg T, et al. *High-speed digital imaging of neoglottic vibration after total laryngectomy*. Arch Otolaryngol Head Neck Surg 1999;125:891-7.
- ⁴ Hilgers FJ, Dirven R, Wouters Y, et al. *A multicenter, prospective, clinical trial evaluating a novel adhesive baseplate (Provox StabiliBase) for peristomal attachment of postlaryngectomy pulmonary and voice rehabilitation devices*. Laryngoscope 2012;122:2447-53.
- ⁵ Dirven R, Kooijman PG, Maal TJ, et al. *An external neck brace to support the peristomal fixation of an automatic stoma valve (ASV): 3D stereophotogrammetrical assessment*. Acta Otolaryngol 2010;130:851-8.
- ⁶ Dirven R, Kooijman PG, Wouters Y, et al. *Clinical use of a neck brace to improve hands-free speech in laryngectomized patients*. Laryngoscope 2012;122:1267-72.
- ⁷ Hilgers FJ, Cornelissen MW, Balm AJ. *Aerodynamic characteristics of the Provox low-resistance indwelling voice prosthesis*. Eur Arch Otorhinolaryngol 1993;250:375-8.
- ⁸ Hilgers FJ, Ackerstaff AH, Balm AJ, et al. *Development and clinical evaluation of a second-generation voice prosthesis (Provox 2), designed for anterograde and retrograde insertion*. Acta Otolaryngol 1997;117:889-96.
- ⁹ Hilgers FJ, Ackerstaff AH, Jacobi I, et al. *Prospective clinical phase II study of two new indwelling voice prostheses (Provox Vega 22.5 and 20 Fr) and a novel anterograde insertion device (Provox Smart Inserter)*. Laryngoscope 2010;120:1135-43.
- ¹⁰ Schindler A, Ginocchio D, Atac M, et al. *Reliability of the Italian INFVo scale and correlations with objective measures and VHI scores*. Acta Otorhinolaryngol Ital 2013;33:121-7.

Received: January 1, 2015 - Accepted: March 8, 2015

Address for correspondence: Frans J.M. Hilgers, Department of Head and Neck Oncology and Surgery, The Netherlands Cancer Institute-Antoni van Leeuwenhoek, Plesmanlaan 121, 1066CX, Amsterdam, The Netherlands. Tel. +31 20512550. Fax +31 205122554. E-mail: f.hilgers@nki.nl.

CASE SERIES AND REPORTS

Temporo-mandibular joint chondrosarcoma: Case report and review of the literature

Condrosarcoma dell'articolazione temporo-mandibolare: caso clinico e revisione della letteratura

C. GIORGIONE, F.M. PASSALI, T. VARAKLIOTIS, M. SIBILIA, F. OTTAVIANI
Department of Otorhinolaryngology, Tor Vergata University Hospital, Rome, Italy

SUMMARY

Chondrosarcoma is a malignant mesenchymal tumour of cartilaginous origin. It represents 11% of all malignant primary bone tumours, and the pelvis, ribs, femur and humerus are most frequently involved. Chondrosarcoma of the head and neck region is a rare disease, and represents approximately 0.1% of all head and neck neoplasms. This report describes a rare localisation of chondrosarcoma in a 56-year-old man who presented with swelling in the right preauricular area and mild limitation and pain in the mouth opening. Since 1959, just a few cases of temporomandibular joint (TMJ) chondrosarcoma have been described. Computed tomography revealed a large mass (39 x 46 x 40 mm) in the right preauricular and parotid region with morpho-structural alterations of the condyle and an intense periostotic reaction. The tumour was treated by total parotidectomy and condylotomy. The VII cranial nerve was preserved. Histopathologic examination revealed a low grade chondrosarcoma with a 50% proliferation index. At present, the patient is still receiving routine follow-up after radiotherapy and physiotherapy.

KEY WORDS: Chondrosarcoma • Temporomandibular joint • Bone tumour

RIASSUNTO

Il condrosarcoma è un tumore mesenchimale maligno di derivazione cartilaginea. Rappresenta l'11% dei tumori maligni ossei primari e si localizza prevalentemente a livello della pelvi, del femore distale e dell'omero prossimale. Il condrosarcoma della regione testa-collo rappresenta circa lo 0,1% delle neoplasie di questo distretto e l'origine nell'articolazione temporo-mandibolare è un evento raro. Solo 23 casi fino ad oggi sono stati descritti in letteratura dal 1954 ad oggi. Questo report tratta di un caso di condrosarcoma avente come origine il condilo mandibolare in un paziente maschio di 56 anni giunto alla nostra osservazione per la presenza di una neoformazione di consistenza duro-ligneo localizzata nella regione parotideo destra, otalgia, dolore alla masticazione e trisma. La TC evidenziava voluminosa neoformazione (39x46x40mm) che inglobava posteriormente la branca montante della mandibola, con alterazioni morfostrutturali del condilo ed intensa reazione periostotica. Il condilo mandibolare appariva inoltre lussato anteriormente. È stato eseguito intervento chirurgico di parotidectomia totale con conservazione del facciale e mandibolectomia parziale. L'esame istologico associato all'immunoistochimica ha evidenziato un condrosarcoma ben differenziato, con indice proliferativo pari al 50%. Ad oggi il paziente esegue routinariamente follow-up con controlli ambulatoriali dopo aver effettuato trattamento radio e fisioterapico.

PAROLE CHIAVE: *Condrosarcoma • Articolazione temporo-mandibolare • Tumori ossei*

Acta Otorhinolaryngol Ital 2015;35:208-211

Introduction

Chondrosarcoma is a slow-growing malignant tumour characterised by the formation of cartilage, but not bone, by tumour cells. Chondrosarcoma arises from embryogenic cartilaginous rests¹. It seldom occurs in the head and neck region, especially the mandible, and can be found even more rarely in the temporo-mandibular joint (TMJ).

Clinical presentation usually mimics more common disorders, leading to delay in diagnosis (unilateral facial swell-

ing, external auditory canal obstruction or chronic TMJ dysfunction)¹. The clinical behaviour of chondrosarcoma is greatly variable and is linked to histologic grading. The aetiology of chondrosarcomas still remains unclear and their management is controversial. The following report describes a rare case of TMJ chondrosarcoma.

Case report

A 56-year-old east European male was referred to our hospital with right auricular pain that had been present for 12

months and treated with antibiotic and anti-inflammatory therapy without any benefits. The patient also reported a progressive painless mass growth in his right pre-auricular region for 3 months, with mild limitation in the mouth opening and pain on chewing. He denied any trauma.

Objective clinical exam showed facial asymmetry and swelling in the right pre-auricular region.

Ultrasound of the preauricular region, performed in the emergency department, showed a roundish mass 45 x 34 x 29 mm, with parenchymatous echotexture, heterogeneous with calcifications in the context, in close proximity to the parotid gland. In addition, perilesional and intralesional vascularisation was observed.

During hospitalisation, the patient was in good general conditions, with a hard mass in his right parotid region fixed to the deep cervical structure and covered with mild hyperaemic skin. He had trisma and right auricular pain. There were no palpable cervical lymph nodes and no VII cranial facial nerve palsy.

A fine-needle aspiration biopsy of the mass was reported as a pleomorphic adenoma, but due to some myoepithelial cellular characteristics, the pathologist suggested postponing definitive diagnosis until the entire mass could be examined. A head and neck CT scan was performed which revealed a large mass with a hyperintense wall and colligation inside. Its size was 39 x 46 x 40 mm (Fig. 1).

This mass arose from the posterior mandibular branch and presented a partial structural erosion of the condyle with high periostotic reaction. This mass showed a swelling in the region of the masseter muscle and close to the bone portion of the external acoustic meatus.

After CT, a MRI was performed (Fig. 2).

The functionality of the facial nerve, evaluated by electromyography of the orbicularis oculi and oris muscles, was normal.

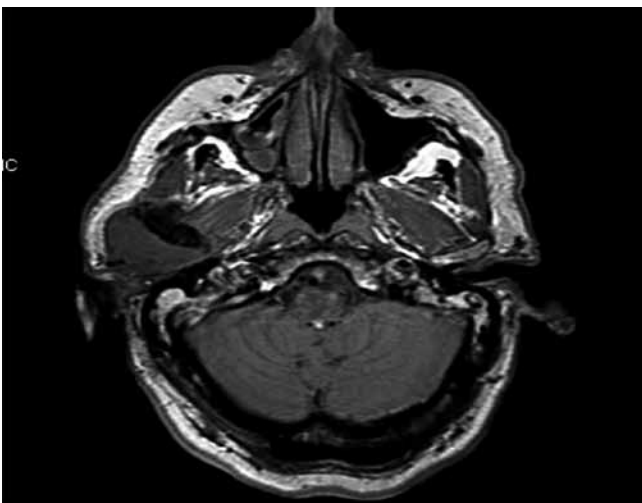


Fig. 1. CT image showing a voluminous mass with hyperdense wall, determining structural alteration of the condyle and an intense periostotic reaction. Furthermore, the lesion appears to be in contact with the front wall of the external acoustic meatus.

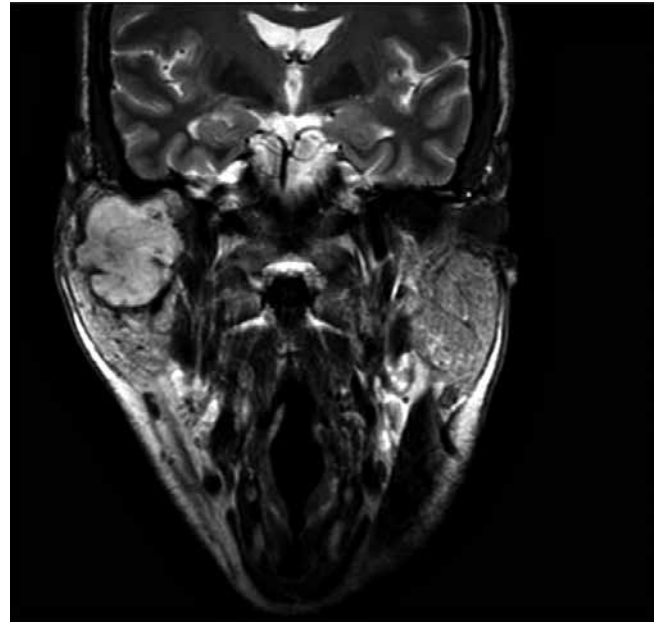


Fig. 2. MRI image showing an expansive mass with liquid content inside an irregular and thickened wall. It also shows inhomogeneous and widespread contrast enhancement.

A total parotidectomy and condylectomy was carried out. The VII cranial nerve was preserved, and during surgery functionality was checked by intraoperative nerve monitoring (NIM). The final histologic diagnosis of the mass was "low grade chondrosarcoma". Microscopic examination of the section showed chondroid tissue, large cells with atypical nuclei and a proliferative index of 50% (Ki-67) (Fig. 3). Immunohistochemically, cells were S100+, CK35BH11-, actin-, vimentin+ ck19-, GFAP- and PANCK-.

After surgery the patient had grade II-III facial nerve paralysis which regressed to a grade II when the patient was discharged (10 days after surgery) (Fig. 4).

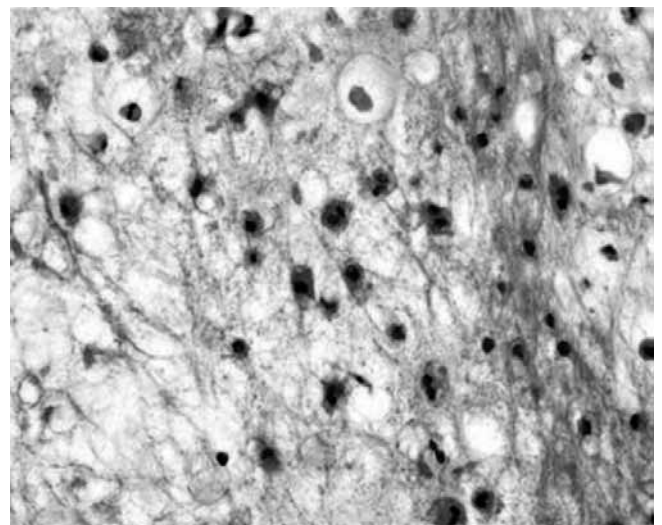


Fig. 3. Histologic image of TMJ chondrosarcoma showing atypical chondrocytes with binucleation and eosinophilic cytoplasm.

He was referred for radiation therapy after an oncologic and radiotherapeutic evaluation because of dubious positive margins of the surgical specimen.

At present, he is undergoing radiotherapy and has completed physiotherapy for the VII cranial nerve. The patient is still receiving routine follow-up at the time of writing (Fig. 5).

Discussion

After osteogenic sarcoma, chondrosarcoma is the most common bone tumour and represents 10-20% of all primary bone tumours². The primary sites of presentation are the pelvis, femur and humerus^{3,1}. Chondrosarcoma of the head and neck region is a rare disease, and only 5-10% of chondrosarcoma occur in the head and neck. Larynx, maxilla and nasal region are the most common sites². The occurrence of chondrosarcoma in TMJ is an exceptional event that has been described in only 23 cases.

Chondrosarcoma can be primary or secondary depending on whether it develops *ex novo* (from normal cartilage, bones or soft tissue) or from a pre-existent benign lesion in patients with Maffucci syndrome, Ollier disease, etc.

No history of bone-cartilage disease or familial skeleton disease was found in the present patient.

Evans classified conventional chondrosarcoma into three grades (I-II, III) based on cellularity, frequency of mitosis and nuclear dimension. It is also possible to divide chondrosarcoma into two groups: low grade (Evans' grade I-II) and high grade (Evans' grade III)⁴.

Low grade chondrosarcoma (grade I) is very close in appearance to enchondromas and osteochondromas, has occasional binucleated cells and may show atypical cells including binucleate forms (cells with two nuclei instead of one). Calcifications and bone formation can be found, but can also be characteristic of higher grade tumours.

Grade II (or "intermediate grade") presents a higher cellular population with a greater degree of nuclear atypia, hyperchromasia and nuclear size. The mitotic rate is low (less than two per 10 high power fields). High grade (grade III) chondrosarcoma has significant areas of marked pleomorphism, large cells with more hyperchromatic, denser and greater nuclei size than grade II, occasional giant cells and abundant necrosis. Mitoses are more than three per field⁴.

Histologic differentiation influences clinical behaviour, and the metastasis rate varies from 10% for grade II cases to 71% for those in grade III. The most frequent metastatic sites are the limbs and lungs. The 5-year survival rate varies from 90% to 81% to 43%, respectively, for grades I, II and III. Metastasis from grade I chondrosarcoma has not been reported⁵.

Chondrosarcoma has several histologic types, although the conventional type is the most common. Other types include clear cell, myxoid, mesenchymal

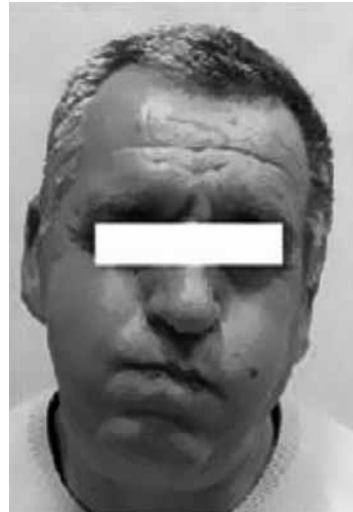

Fig. 4. Functionality of the VII cranial nerve. The patient is perfectly capable of puffing his cheeks, close his eyes and whistle.

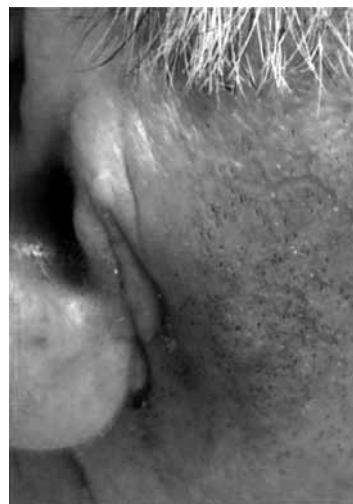

Fig. 5. The final surgical wound.

and dedifferentiated variants. The clear cell variant is called malignant chondroblastoma, but there has been controversy over whether to classify it as a variant of chondrosarcomas or to categorise it separately as malignant chondroblastoma³. The mesenchymal variant is also called the aggressive variant, since 2 of 3 cases arise before the age of 30 and in advanced stages and grades.

Histopathologically, chondrosarcoma of the TMJ seem similar to chondrosarcomas of the head and neck or other regions of the body. Histologically, the lesion is composed of atypical chondrocytes organised in a hyalin matrix where isolated loci of calcification also appear. The classification of this cartilaginous tumour is related to the size that arise in soft tissue areas⁶. T1 tumours are 5 cm or less and T2 tumours are more than 5 cm in the greatest dimension⁷. Surgical treatment is the most effective modality for chondrosarcoma. The most important point is to ensure an adequate safety margin which must be checked from a histological point of view, since residual disease is known to be an important cause of recurrence. It is gen-

erally accepted that radiotherapy should be used for palliative purposes in unresectable cases or as an adjuvant therapy in cases of residual disease rather than as initial treatment.

Prognostic factors in chondrosarcoma are linked to the extent of surgical resection, grade, TNM classification and primary origin sites. The most frequent cause of death is recurrence and not metastasis³.

Pre-operative diagnosis of TMJ chondrosarcoma is difficult and usually not possible because of the rarity of the location and the non-specificity of symptoms. Fine needle aspiration biopsy, although proposed by several authors, does not often provide exact results in this region because it is necessary to distinguish the tumour from osteogenic sarcoma, parotid pleomorphic adenoma and chondroma.

This tumour has a slow growth and is often asymptomatic until it grows to a remarkable size.

There are no pathognomonic findings associated with chondrosarcoma. Single or multiple radiolucent areas can be seen on plain or panoramic films. Bone destruction is a frequent observation, while calcification and ossification, which cause spot densities, are occasionally present. In this case report, the expansive growth of the tumour and its relationship with the TMJ were demonstrated with the use of CT and MRI. In several previously-reported cases of chondrosarcoma, there was evidence of widening of the joint space, which is attributed to condylar resorption. Indeed, local bone destruction was revealed through the use of CT and MRI in all previous cases⁶.

According to Bertoni et al. the most useful features for diagnosis are the following:

- loss of the typical clustering pattern with abundant matrix juxtaposed to areas where the tumour cells are arranged in sheets;
- myxoid change in the matrix;
- hypercellularity with crowding and spindling of the nuclei at the periphery of the lesion;
- presence of necrosis;
- permeation of the trabecular bone and invasion of marrow space⁸.

References

- ¹ Olivera RC, Marques KDS, Mendoca AR, et al. *Chondrosarcoma of the temporomandibular joint: a case report in child*. J Orofac Pain 2009;23:275-81.
- ² Gallego L, Junquera L, Fresno MF, et al. *Chondrosarcoma of the temporomandibular joint. A case report and review of the literature*. Med Oral Patol Oral Cir Bucal 2009;14:39-43.
- ³ Lee SY, Lim YC, Song MH, et al. *Chondrosarcoma of the head and neck*. Yonsei Med J 2005;46:228-32.
- ⁴ Evans HL, Ayala AG, Romsdahl MM. *Prognostic factors in chondrosarcoma of bone: a clinicopathologic analysis with emphasis on histologic grading*. Cancer 1977;40:818-31.
- ⁵ Sesenna E, Tullio A, Ferrari S. *Chondrosarcoma of the temporomandibular joint*. J Oral Maxillofac Surg 1997;55:1348-52.
- ⁶ Gonzalez-perez LM, Sanchez-Sallego F, Perez-Ceballos JL, et al. *Temporomandibular joint chondrosarcoma: case report*. J Craniomaxillofac Surg 2011;39:79-83.
- ⁷ Koch BB, Karnel LH, Hoffman LW, et al. *National cancer database report on chondrosarcoma of the head and neck*. Head and Neck 2000;22:408-25.
- ⁸ Bertoni F, Picci P, Bacchini P, et al. *Mesenchymal chondrosarcoma of bone and soft tissue*. Cancer 1983;52:533-41.

Received: April 2, 2012 - Accepted: April 24, 2012

CASE SERIES AND REPORTS

Audiological findings in a case of cerebellar angioreticuloma

Risvolti audiologici nell'angioreticuloma cerebellare

A. SERRA¹, P. DI MAURO¹, S. COCUZZA¹, I. CHIARAMONTE², L. MAIOLINO¹¹ Department of Otorhinolaryngology, University of Catania, Italy; ² Department of Radiology, Unit of Neuroradiology, University of Catania, Italy

SUMMARY

The aetiology of neurosensorial damage with unilateral hearing loss and/or tinnitus and dizziness can often be difficult to determine because they may be caused wide variety of pathologic processes and a variety of diagnostic tests are needed in initial evaluation. In this paper, the authors describe, the techniques and indications of neuroimaging for evaluation of auditory symptoms. Auditory brainstem response (ABR) testing is still the choice when condition is suspected. We present a study of one patient with unilateral tinnitus, with no significant hearing loss and normal ABR: the patient underwent MRI of the district brain and the internal auditory channel (AIC) that showed the presence of a rare intracranial neoplasm, namely cerebellar angioreticuloma.

KEY WORDS: MRI • ABR • Tinnitus • Cerebellar angioreticuloma

RIASSUNTO

Nella pratica clinica l'eziologia della sintomatologia audiologica e/o vestibolare può spesso essere difficile da determinare, poiché svariati processi patologici possono esserne responsabili e numerosi test diagnostici vengono utilizzati nella valutazione iniziale. In questo lavoro, gli autori descrivono in dettaglio un caso clinico caratterizzato da assenza di significativa ipoacusia neurosensoriale, presenza di acufeni monolaterali e normalità dell'esame ABR. Il paziente è stato sottoposto a Risonanza Magnetica Nucleare del distretto encefalico e dei condotti uditivi interni. L'indagine neuroradiologica ha rilevato la presenza di una neoplasia intracranica rara, l'angioreticuloma cerebellare.

PAROLE CHIAVE: Risonanza Magnetica • Potenziali evocati uditivi • Acufeni • Angioreticuloma cerebellare

Acta Otorhinolaryngol Ital 2015;35:212-214

Introduction

Despite the low incidence of retrocochlear diseases, diagnosis of these conditions is frequent in clinical practice because about 30% of ENT patients refer audiology symptoms such as unilateral hearing loss or balance disorders. Unilateral sensorineural hearing loss, unilateral tinnitus and balance disorders are necessary to suspect a retrocochlear pathology: the most common cause is acoustic neuroma, which represents approximately 80-90% of all tumours of the cerebellopontine angle (PCA)¹, with an incidence ranging from 1/50,000 to 1/81,000 new cases a year².

The evolution of the traditional diagnostic protocol, represented by physical ENT examination, tonal and vocal audiometry, acoustic stapedial reflexometry, ENG, TEOAE and auditory evoked potentials (ABR)³.

Thanks to the excellent morphological definition, there is potential ability to identify lightly symptomatic disease characterised by normal electrophysiological pattern. Thus, radiologic methods have high specificity and sensitivity in early diagnosis of retrocochlear disorders⁴.

Despite the technical evolution of computed tomography (CT) and magnetic resonance imaging (MRI), and the consequent easier diagnosis of diseases of the skull base and petrosal bone, it is not possible to exclusively rely on these imaging techniques in the evaluation of retrocochlear pathology, also considering that these techniques are expensive. For these reasons, the investigation by MRI cannot be considered as a valid screening method.

Herein, the authors present a clinical case of a patient with unilateral tinnitus with no significant hearing loss and normal ABR: the patient was to undergo MRI of the brain district and internal auditory channel (AIC).

Case report

The study was conducted on a male patient 38 years of age at the Department of Otorhinolaryngology of the University of Catania. The patient complained of the presence of unilateral high tone tinnitus in the left ear, with progressive increase in the time of the intensity of tinnitus. Tinnitus over time had become pulsatile.

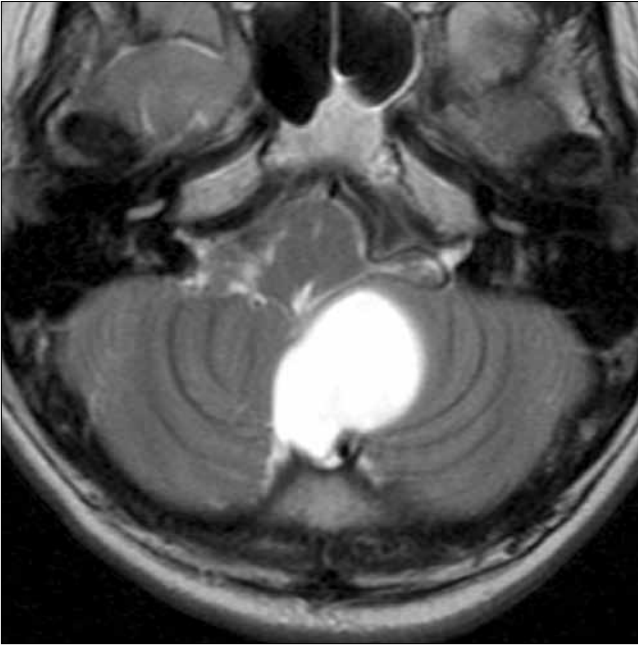

Fig. 1. Cerebellar angioreticuloma (FSE-T2 weighted image MRI).

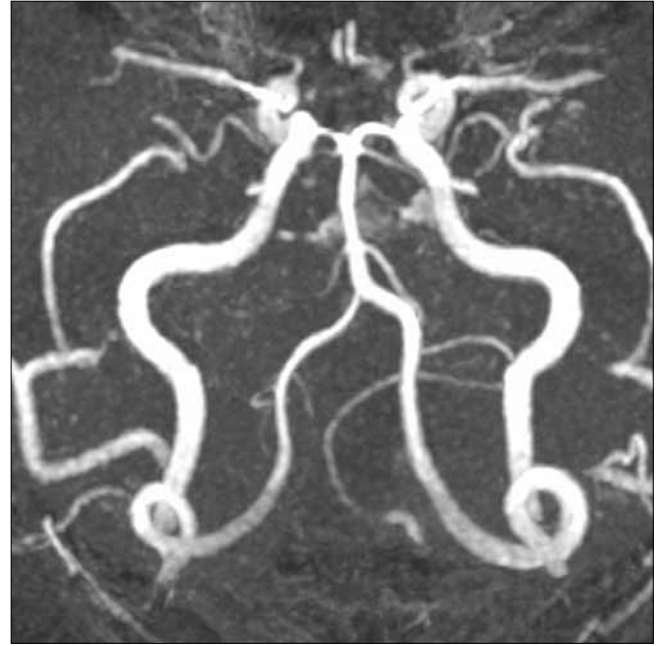

Fig. 2. Left anterior inferior cerebellar artery hyperplasia (angio MRI 3D).

The patient underwent otoneurological anamnesis, tonal audiometry, stapedial reflexometry, TEOAE and auditory evoked potentials (ABR).

The patient underwent neuroradiological evaluation of the brain and internal auditory canals (IAC) with MRI.

The MRI study was conducted with GE equipment (Signa Excite HD) 1.5 T with FSE T2-weighted sequences, FSE T1-weighted, FLAIR, DWI, T2 * GE on the three orthogonal planes for the brain with a thickness of layer equal of 5 mm and interval of 0.5.

For study of IAC, sequences on axial and coronal planes with a slice thickness of 2 mm without interval, with technical FSE T2-weighted, T1-SE, with saturation of the fat signal, acquired on axial and coronal plans were used.

3D-FIESTA sequences were acquired in axial plans, and these images were subsequently processed in MPR 1 mm of para-sagittal and coronal images. The parameters of the 3D-FIESTA sequences were the following: in patients with likely expansive lesions, after obtaining informed consent, we proceeded to study with intravenous administration of gadolinium contrast (Dotarem) at a dose of 0.2 ml per kg of body weight⁵, and acquisition of axial and coronal SE T1-weighted sequences and sagittal 3D - FSPGR and coronal and para-sagittal MPR. In patients who could not or refused to undergo MRI, we proceeded with high-resolution CT of the petrosal bone with GE equipment (Brilliance 64) with the following parameters: FOV 18 × 18, electronic window for bone, thickness 0.65 mm, layer 0.65 mm, rotation time 1 sec, 140 kV, 240 mA. One mm coronal and para-sagittal MPR images were constructed (for a more accurate evaluation of IAC) and the original images were reformatted with

a FOV of 22 × 22 cm, an electronic window for soft tissue thickness 1.2 mm and layer 0.65 mm.

Vascular evaluation was conducted with Siemens angiography with selective catheterisation of the carotid and vertebral arteries.

The audiological evaluation by tonal audiometry revealed the presence in the patient of mild sensorineural hearing loss in the left ear. The mild hearing loss was centered on high frequencies. Impedanzometric examination detected the presence of tympanogram of type “A” and normal stapedial reflexes. The otoacoustic emissions were present bilaterally. Examination by ABR detected the normal morphology of the track and normality of the relative and absolute latency of the waves.

Neuroradiological imaging recognised the presence of a neoplastic formation in the cerebellar with characteristics similar to those of cerebellar angioreticuloma (Fig. 1). MRI examination was completed with 3D angiographic sequences (Fig. 2) and subsequently with selective angiography (Fig. 3). Angiographic sequences identified the presence of hyperplasia of the left anterior inferior cerebellar artery (AICA), a phenomenon which makes it the case even more rare just for the type of unusual vascularisation of the cerebellar angioreticuloma. Selective angiography was also subsequently performed that identified the presence of hyperplasia of left cochlear artery, which was normally not visible in the other conditions.

The patient was subjected to neurosurgical removal of angioreticuloma. Audiological examinations, after neurosurgery, were unchanged from the initial assessment. The

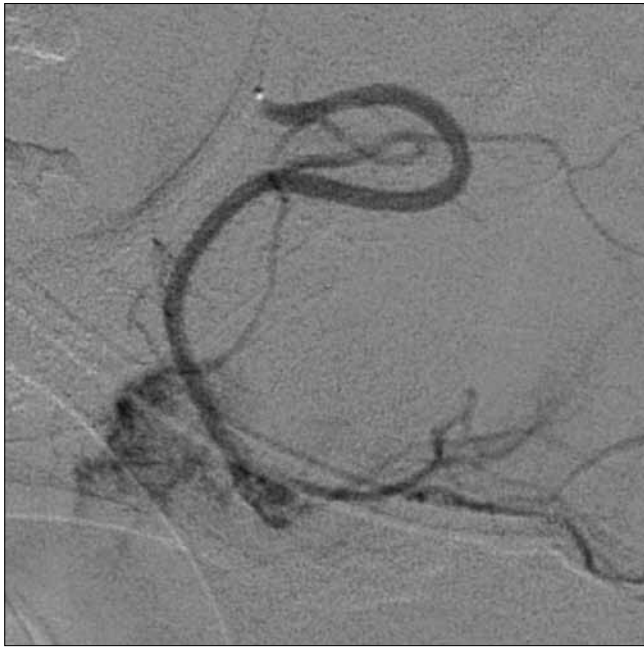

Fig. 3. Left anterior inferior cerebellar artery hyperplasia and cochlear artery hyperplasia (selective angiography MRI).

patient also noticed the reduction and disappearance of pulsatility of tinnitus.

Discussion

Unilateral audiological symptoms are among the most common causes of ENT evaluation, and dizziness and imbalance are also frequent in clinical practice. Many retrocochlear pathologies, such as vestibular tumours, congenital and acquired demyelinating diseases (e.g. multiple sclerosis) and neurovascular conflicts, can be associated with ENT symptomatology during their natural history. ABR permits the diagnosis of retrocochlear disorders that are otherwise not recognisable without diagnostic imaging. From a review of the literature there are contrasting results about the specificity and sensitivity of ABR for detection of intra- and extra- canal tumours⁶. In our study, a patient presented with cerebellar angiodysplasia that was diagnosed by neuroradiological evaluation. Examination by ABR did not detect the presence of morphological abnormalities or timing of absolute and relative latency of the waves. This consideration does not diminish the validity of ABR for the diagnosis of retrocochlear disorders, and the same finding may be present when the damage affects only the CNS structures with balance function, even without audi-

tory system alteration. Other studies attribute a large number of false positives to ABR⁷.

Thus, MRI with Gd permits better reliability in the identification of retrocochlear and central auditory pathway diseases for its excellent morphological definition, especially for some symptomatic lesions with normal electrophysiological pattern, and the MRI can also evaluate cochlear and retrocochlear disorders, such as IAC and PCA alterations⁸. For patients with a high clinical suspicion, MRI can and should remain the gold standard of diagnosis as ABR may miss smaller and/or intracanalicular tumours⁹.

Initial symptoms are sometimes underestimated and the patient is not always referred to radiological investigation. It is always necessary to maintain a high index of diagnostic suspicion to decrease the interval between the first symptoms and final diagnosis.

We believe that this strategy allows adequate diagnosis of retrocochlear disorders, such as small lesions of the IAC and PCA, with the possibility of effective and early medical and surgical techniques aimed at the preservation of hearing.

References

- 1 Jackler RK, Pitts LH. *Acoustic Neuroma (Vestibular Schwannoma)*. In: *Neurotology*. St Louis: Mosby; 1994. p. 729-85.
- 2 Tos M, Thomsen J. *Incidence of vestibular schwannoma*. *Laryngoscope* 1999;109:736-40.
- 3 Hendrix RA, Robert M, Sclafani AP. *The use of diagnostic testing in asymmetric sensorineural hearing loss*. *Otolaryngol Head Neck Surg* 1990;103:593-8.
- 4 Sedwick JD, Gajewski BJ, Prevatt AR, et al. *Magnetic resonance imaging in the search for retrocochlear pathology*. *Otolaryngol. Head Neck Surg* 2001;124:652-5.
- 5 Plaza G, Lopez Lafuente J, Aparicio JM, et al. *Resonancia Magnética: Prueba de elección en el depistaje de tumores del conducto auditivo interno y ángulo pontocerebeloso*. *Acta Otorrinolaringol Esp* 2001;52:651-6.
- 6 Day AS, Wang CT, Chen CN, et al. *Correlating the cochleovestibular deficits with tumor size of acoustic neuroma 1*. *Acta Otolaryngol* 2008;7:756-60.
- 7 Furman JM. *Otoneurology an Issue of Neurologic Clinics*. Saunders Ed; 2005.
- 8 Oh JH, Chung JH, Min HJ, et al. *Clinical application of 3D-FIESTA image in patients with unilateral inner ear symptom*. *Korean J Audiol* 2013;17:111-7.
- 9 Koors PD, Thacker LR, Coelho DH. *ABR in the diagnosis of vestibular schwannomas: a meta-analysis*. *Am J Otolaryngol* 2013;34:195-204.

Received: December 1, 2014 - Accepted: March 8, 2015

Address for correspondence: Agostino Serra, University of Catania, Department of Otorhinolaryngology, A.O. "Policlinico Vittorio Emanuele", via Santa Sofia 78, 95123 Catania. Tel. +39 095 3781093. Fax +39 095 7335738. E-mail: serra@policlinico.unict.it

Calendar of events – Italian and International Meetings and Courses

Acta Otorhinolaryngol Ital 2015;35:215-216

Information, following the style of the present list, should be submitted to the Editorial Secretariat of Acta Otorhinolaryngologica Italica (actaitalicaorl@rm.unicatt.it).

In accordance with the Regulations of S.I.O. and Ch.C.-F. (Art. 8) Members of the Society organising Courses, Congresses or other scientific events should inform the Secretary of the Association (A.U.O.R.L., A.O.O.I.) within the deadlines set down in the respective Statutes and Regulations.

MAY-DECEMBER 2015

CENACOLO ITALIANO DI AUDIOVESTIBOLOGIA • March 21 - May 16, 2015 • Chieti – Italy

Director: Giampiero Neri – E-mail: info@nsmcongressi.it – Website: www.nsmcongressi.it

16th WORLD CONGRESS OF RHINOLOGY • April 30 - May 2, 2015 • São Paulo – Brazil

President: Aldo Stamm – E-mail: secretaria@malulosso.com.br – Website: <http://www.rhinology2015.com/Scientific-program.htm>

VI CONGRESO IBEROAMERICANO DE IMPLANTES COCLEARES Y CIENCIAS AFINES May 20-23, 2015 • Sao Paulo – Brasil

Tel. 55 11 5081 7028

VERTIGO ACADEMY INTERNATIONAL • May 22-23, 2015 • Moscow – Russia

Chairman: O. Nuri Ozgirgin (Turkey) – Website: www.vainternational.org

102nd NATIONAL CONGRESS SIO, ITALIAN SOCIETY OF OTORHINOLARYNGOLOGY HEAD AND NECK SURGERY • May 27-30, 2015 • Rome – Italy

President: Giuseppe Spriano – Organizing Secretariat: NordEst Congressi – Tel. +39 06 68807925 – Fax +39 06 68212211 – E-mail: nec@nordestcongressi.it – Website: www.sio2015.com

3rd CONGRESS OF EUROPEAN ORL-HNS • June 7-11, 2015 • Prague – Czech Republic

President: Jan Betka – E mail: orl-hns2015@guarant.cz – Website: <http://www.europeanorl-hnsprague2015.com>

27° CONGRESSO NAZIONALE SPIGC • June 11-13, 2015 • Brescia – Italy

President: Gian Luca Pariscenti – Website: www.spigc.it

5th HANDS ON DISSECTION ADVANCED COURSE: “FROM REMOVAL TO RECONSTRUCTION IN HEAD & NECK CANCERS” • June 16-19, 2015 • Paris – France

Directors: Marco Benazzo, Department of Otolaryngology HN Surgery, University of Pavia; Fausto Giuseppe Chiesa, Department of Otolaryngology HN Surgery, IEO Milan. Organizing Secretariat: Bquadro Congressi srl, via S. Giovanni in Borgo 4, 27100 Pavia. Tel. +39 0382 302859 – Fax +39 0382 27697 – E-mail: bolla@bquadro-congressi.it – Website: www.bquadro-congressi.it

41° CONGRESSO CONVENTUS SOCIETAS ORL LATINA • July 6-8, 2015 • Torino – Italy

President: Roberto Albera, Francesco Pia

22nd INTERNATIONAL CONGRESS ON THE EDUCATION OF THE DEAF • July 6-9, 2015 • Athens – Greece

Website: www.iced2015.com

WORLD CONGRESS ON LARYNX CANCER 2015 • July 26-30, 2015 • Queensland – Australia

Website: www.wclc2015.org

**27th INTERNATIONAL COURSE ON ENDOSCOPIC SURGERY OF THE PARANASAL SINUSES & SCULL BASE
August 26-29, 2015 • Ghent – Belgium**

Course Director: Claus Bachert – Tel. +32(0)92338597 – Email: Fess@semico.be

SYMPOSIUM & 52nd INNER EAR BIOLOGY WORKSHOP • September 12-15, 2015 • Rome – Italy

Directors: Gaetano Paludetti and Diana Troiani – Website: www.ieb2015.it

2nd SIR (SOCIETÀ ITALIANA DI RINOLOGIA) NATIONAL CONGRESS • September 17-19, 2015 • Udine – Italy

President: Marco Piemonte – E-mail: nec@nordestcongressi.it – Website: www.nordestcongressi.it

V CORSO TEORICO-PRATICO DI AUDIOLOGIA E VESTIBOLOGIA**September 28-30, 2015 • Benevento – Italy**

Segreteria Scientifica: Luigi Califano, Maria Grazia Melillo – E-mail: luigi.califano@tin.it, vertigobn@hotmail.com

**INTERNATIONAL WORKSHOP “OPEN PARTIAL HORIZONTAL LARYNGECTOMIES (OPHL) VERSUS
TRANSORAL LASER MICROSURGERY (TLM) IN LARYNX CANCER”****October 8-10, 2015 • Castel Brando (TV) – Italy**

Chairman: G. Rizzotto – Email: mail@nordestcongressi.it – Websites: www.nordestcongressi.it, www.oncolarynx.it

**XXXIX CONVEGNO NAZIONALE AOOI (ASSOCIAZIONE OTORINOLARINGOLOGI OSPEDALIERI
ITALIANI) October 16-17, 2015 • Genova – Italy**

President: Felice Scasso – E-mail: nec@nordestcongressi.it – Website: www.nordestcongressi.it

7th INTERNATIONAL SYMPOSIUM ON MENIERE’S DISEASE AND INNER EAR DISORDERS**October 17-20, 2015 • Rome – Italy**

Website: meniere2015.eu

**VII INTERNATIONAL SYMPOSIUM ON RECENT ADVANCES IN RHINOSINUSITIS AND NASAL POLYPOSIS
October 22-25, 2015 • Panama**

Information: congresors2015@gmail.com

3rd VIS (SOCIETÀ ITALIANA DI VESTIBOLOGIA) CONGRESS • October 30-31, 2015 • Modena – Italy

Website: www.vestibologyitaliansociety.com

**SIOP (SOCIETÀ ITALIANA DI OTORINOLARINGOIATRIA PEDIATRICA) NATIONAL CONGRESS
November 5-7, 2015 • Rome – Italy**

E-mail: info@formazioneventisrl.it – Website: www.formazioneventisrl.it

**XXXV CONGRESSO NAZIONALE SIAF – AGGIORNAMENTI IN AUDIOLOGIA INFANTILE
December 16, 2015 • Milan – Italy**

Chairman: Antonio Cesarani – Website: www.sia-f.it

JANUARY-DECEMBER 2016**CORSO DI DISSEZIONE OTOLOGICA, OTONEUROLOGICA e IMPLANTOLOGIA Uditiva
January 5-7, 2016 • Paris – France**

Course Directors: Olivier Sterkers, Daniele Bernardeschi. Info: danielle.bernardeschi@aphp.fr

6° CONGRESSO NAZIONALE CO.R.TE. • March 10-12, 2016 • Rome – Italy

President: Nicolò Scuderi – Tel. +39 06 35497114 – Email: corte@jaka.it

**15th INTERNATIONAL MEETING OF THE MEDITERRANEAN SOCIETY OF OTOLGY AND AUDIOLOGY
April 28-30, 2016 • Cappadocia – Turkey**

President: S. Armagan Incesulu – Website: www.msoa2016.org

**INSTRUCTIONAL WORKSHOP EUROPEAN ACADEMY OF OTOLGY AND NEURO-OTOLGY
September 28 - October 1, 2016 • İzmir, Turkey**

President: O. Nuri Ozgirgin – Website: www.eaono.org